

Photo Vignette

Hailey-Hailey disease exacerbated by multiple pregnancies: case report and review of the literature

Shakuntala H. Mauzo, MD¹, Daryl J. Sulit, MD²

Dermatology Online Journal 20 (10): 10

¹University of Texas Health Science Center at Houston, TX

²Walter Reed National Military Medical Center, Bethesda, MD

Correspondence:

Shakuntala H. Mauzo, MD
Department of Pathology and Laboratory Medicine
University of Texas Health Science Center
Houston, TX
E-mail: drmauzos@gmail.com

Abstract

Hailey-Hailey disease is a rare chronic skin disorder that is inherited in an autosomal dominant manner. The disease is characterized by development of vesicles and bullae typically in the intertriginous areas. On histology, there is widespread intraepidermal acantholysis causing the “dilapidated brick-wall” appearance. Mutations in the ATP2C1 gene, encoding for P-type Ca²⁺ transport ATPase, is the primary cause of the disease. The disease manifests around puberty and runs a chronic course with remissions and exacerbations. Ultraviolet light exposure, sweating, friction, stress, and cutaneous infections are the known precipitants of the disease. We report a case of a woman with recurrent flare-ups of Hailey-Hailey disease with repeated pregnancies and remission of her disease during non-pregnancy periods. To our knowledge, this is the first reported case of Hailey-Hailey disease exacerbated by pregnancy.

Introduction

Hailey-Hailey disease (HHD), also known as benign chronic familial pemphigus, was first described by the Hailey brothers in the year 1939 [1]. It is a rare autosomal dominant genetic blistering skin disorder with an incidence of 1 in 50,000 [2, 3].

Clinically, HHD is characterized by recurrent eruptions of fragile vesicles and bullae on an erythematous base. The lesions show predilection to the intertriginous areas, such as axillae, groin, and other sites of friction. On histology, HHD is characterized by full thickness epidermal acantholysis with a “dilapidated brick-wall” appearance [2, 4, 5].

HHD is characterized by multiple relapses and spontaneous remissions. The known precipitating factors are ultraviolet light exposure, sweating, friction, stress, and cutaneous infection [2, 6]. We report a case of a woman who presented with recurrent flare-ups of HHD during multiple pregnancies.

Case synopsis

A 38-year-old gravida 6, para 4, pregnant woman, with a past medical history of HHD, presented to our clinic complaining of worsening of her HHD skin lesions in the intertriginous areas. The lesions were itchy and caused discomfort. She denied any history of fever, chills, or other systemic symptoms. She had similar flare-ups during her past pregnancies, especially as the

pregnancy progressed. Her skin disease would typically improve significantly post partum. Family history revealed similar skin lesions in her father and sister. None of her children manifested with HHD skin lesions, but all of them were 10-years-old or younger. On physical examination, there were symmetric moist, fissured, macerated, eroded plaques on the axilla, inframammary folds, and groin (Figures 1 and 2) Some lesions were tender to palpation.

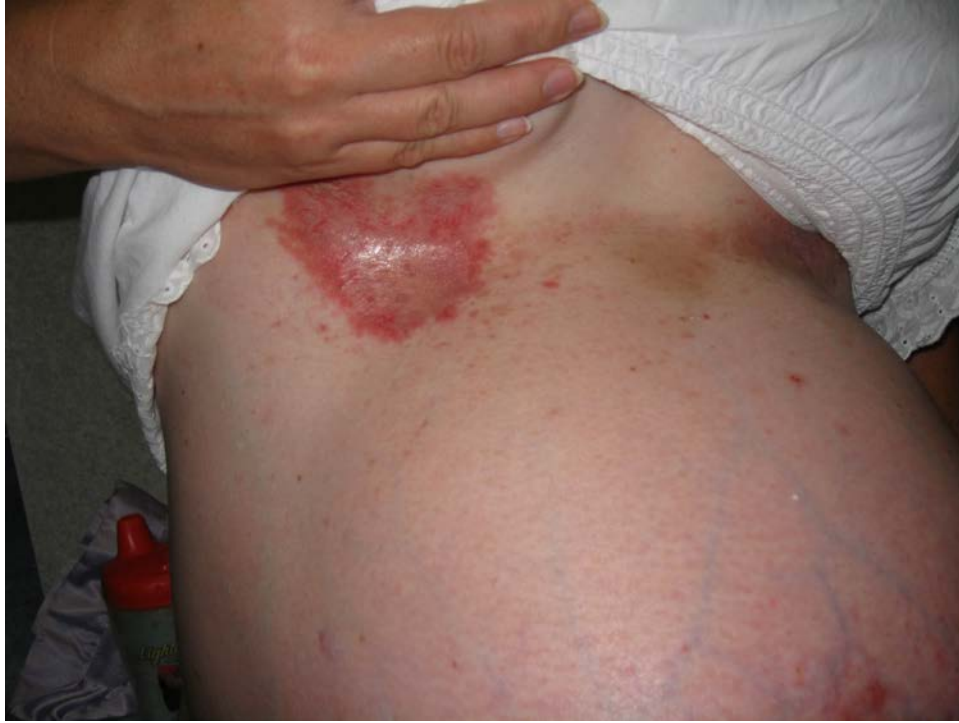

Figure 1. Erythematous, moist, fissured, macerated, eroded plaque on the right inframammary fold

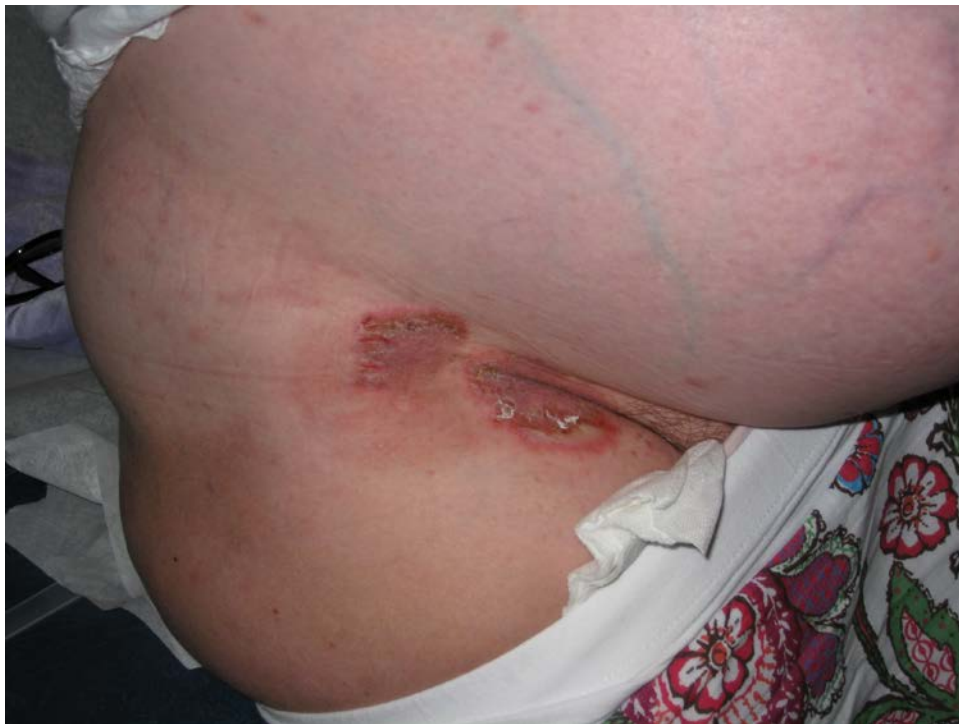

Figure 2. Erythematous, moist, fissured, macerated, eroded plaques on the right inguinal fold

Review of the patient's medical record showed a previous skin biopsy of her left axilla displaying full-thickness epidermal acantholysis (Figures 3 and 4). In addition, there was a negative direct immunofluorescence exam of biopsied skin.

The patient was started on topical benzoyl peroxide 5% gel, topical clindamycin 1% gel, and topical corticosteroids, which resulted only in modest improvement, but did not completely resolve her skin lesions. However, the patient reported significant improvement and relief of symptoms post partum.

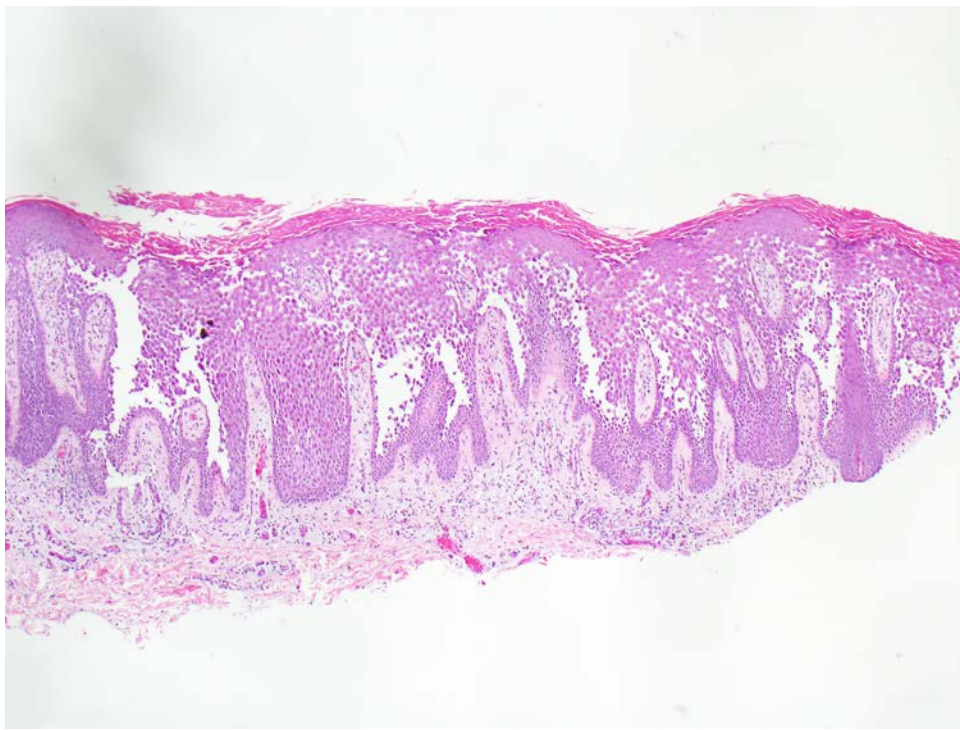


Figure 3. Hematoxylin and Eosin stain from left axilla shave biopsy showing widespread epidermal acantholysis in the “dilapidated brick wall” pattern. The basal cell layer remains attached to the dermis. Microscopic magnification 4x hpf

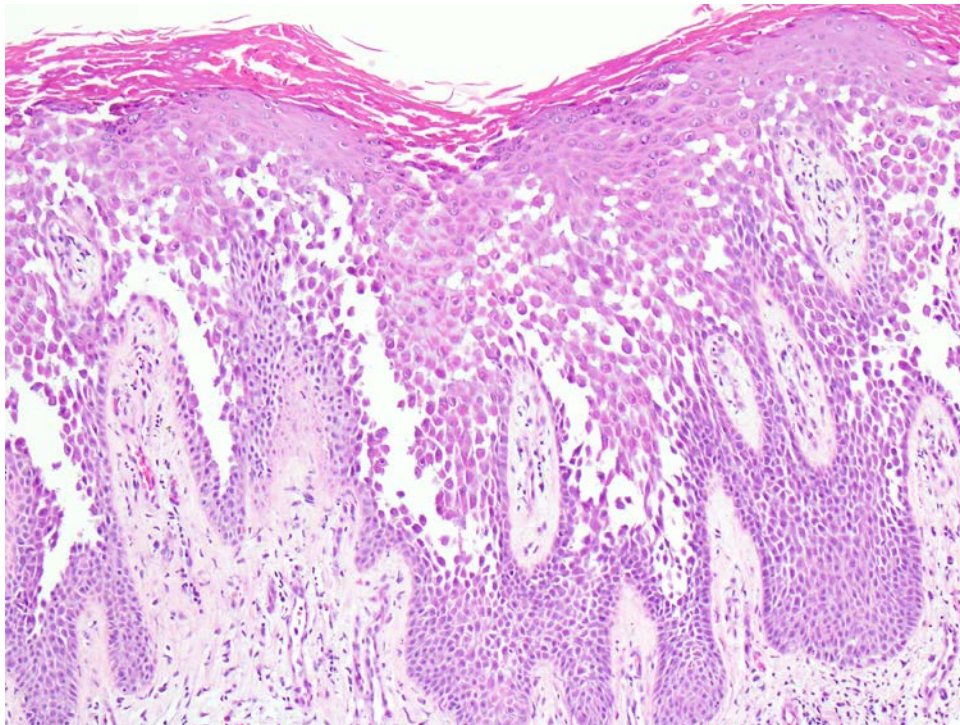


Figure 4. Hematoxylin and Eosin stain from left axilla shave biopsy showing widespread epidermal acantholysis in the “dilapidated brick wall” pattern. The basal cell layer remains attached to the dermis. Microscopic magnification 10x hpf

Discussion

Hailey-Hailey disease (HHD) is an autosomal dominant blistering skin disorder with complete penetrance but variable expressivity [3, 7]. It is characterized by a mutation in the *ATP2C1* gene on chromosome 3q21, which encodes a P-type calcium transport adenosine triphosphatase [8]. Loss of expression of this protein results in calcium depletion from within the Golgi apparatus, which may impair complete processing of junctional proteins required for normal epidermal cell-to-cell adhesion [3, 8, 9, 10].

Affected HHD patients classically present with recurrent, pruritic, painful, and malodorous vesicular patches that mainly affect intertriginous skin, such as the axilla, groin, and inframammary folds [2, 6, 7]. Skin lesions typically first appear after puberty in the second and third decade of life, although they can occur at any age [3]. Although the primary lesions are vesicles and bullae, blisters are usually not seen on skin exam owing to their fragility. Flaccid vesicles often become quickly eroded and sometimes incur secondary eczematous change or superinfection with bacteria or fungus. Healing occurs without scarring, but there may be residual post inflammatory pigment alterations [5].

Diagnosis of HHD can be made with a combination of clinical history, physical exam, histopathology, and immunofluorescence studies. On histology, HHD is characterized by full thickness epidermal acantholysis, which has been called the “dilapidated brick wall” pattern. The basal cell layer remains attached to the dermis [1, 2, 6]. Dyskeratosis of epidermal keratinocytes, which is the predominant finding in Darier's disease, another calcium pump disorder of the skin, is typically mild to absent in HHD [7, 9]. Test results of direct immunofluorescence are negative [6]. In difficult cases, polymerase chain reaction may be performed, in which the segments of ATP2C1 gene spanning all its 27 exons have to be screened for mutations [11]. The majority of the mutations (30%) are frameshift mutations leading to premature termination codons [3].

The clinical differential diagnosis includes intertrigo, seborrheic dermatitis, contact dermatitis, psoriasis, tinea, hidradenitis suppurativa, and erythrasma [4, 5, 6]

Hailey-Hailey disease usually runs a chronic course with remissions and exacerbations. Heat, sweating, mechanical trauma, friction, UVB exposure, and infection are common triggers that exacerbate the disease [2, 3, 6]. It has also been noted that excessive weight in HHD patients induces more mechanical friction and increases HHD severity [9]. Additionally, approximately 17% of female HHD patients experience a premenstrual exacerbation of disease [12].

It has been suggested in the past that aging and hormones may differentially affect ATP2A2 (mutation in Darier's disease) and ATP2C1 (mutation in HHD) expression, thus playing a role in the exacerbation of these calcium ATPase skin disorders [3]. The onset of disease around puberty and premenstrual exacerbation support this theory. In our patient, pregnancy was an exacerbating factor of the disease and we speculate that the hormone changes in pregnancy and the weight gain associated with pregnancy exacerbated her HHD.

The treatment of HHD is challenging. Multiple treatments, both topical and systemic, have been reported in the literature. However, there is no definitive treatment or cure for this genetic condition [6, 13].

In conclusion, we present a case of HHD that has consistently flared during multiple pregnancies. After completion of her pregnancies, the patient's HHD would improve significantly. We believe pregnancy worsened our patient's HHD owing to the temporary increase in size and weight during her pregnancies, which resulted in more mechanical friction in intertriginous areas. We also speculate her HHD exacerbation was further induced by the changes in her sex hormones during pregnancy. To our knowledge, pregnancy as a trigger for HHD exacerbation has not been reported in the medical literature.

References

1. Hailey H, Hailey H. Familial benign chronic pemphigus. *Arch Dermatol Syph.* 1939;39:679-85.
2. Burge SM. Hailey-Hailey disease: the clinical features, response to treatment and prognosis. *Br J Dermatol.* 1992;126(3):275-82. [PMID: 1554604]
3. Szigeti R, Kellermayer R. Autosomal dominant calcium ATPase disorders. *J Invest Dermatol* 2006; 126: 2370-2376. [PMID: 16794587]
4. McKibben J, Smalling C. Hailey-Hailey. *Skinmed.* 2006; 5(5):250-2. [PMID: 16957441]
5. Hohl D, Mauro T. Darier Disease and Hailey-Hailey Disease. In: Bologna J, et al, eds. *Dermatology*, 2nd edition. 2008: 798.
6. Abdullah L, Abbas O. Dermacase. Can you identify this condition? Benign familial chronic pemphigus. *Can Fam Physician.* 2011 Oct; 57 (10): 1157-8. [PMID: 21998234]
7. Foggia L, Hovnanian A. Calcium pump disorders of the skin. *American Journal of Medical Genetics Part C (Semin. Med. Genet.)* 2004; 131C: 20-31. [PMID: 15468148]
8. Hu Z, Bonifas J, Beech J, Bench G, Shigihara T, Ogawa H, Ikeda S, Mauro T, Epstein EH Jr. Mutations in ATP2C1, encoding a calcium pump, cause Hailey-Hailey disease. *Nature genetics* 2000; 24: 61-65. [PMID: 10615129]
9. Dobson-Stone C, Fairclough R, Dunne E, Brown J, Dissanayake M, Munro CS, Strachan T, Burge S, Sudbrak R, Monaco AP, Hovnanian A. Hailey-Hailey disease: Molecular and clinical characterization of novel mutations in the ATP2C1 gene. *J Invest Dermatol* 2002; 118: 338-343. [PMID: 11841554]
10. Dhitavat J, Fairclough R, Hovnanian A, Burge S. Calcium pumps and keratinocytes: lessons from Darier's disease and Hailey-Hailey disease. *Br J Dermatol* 2004; 150: 821-828. [PMID: 15149492]

11. Chao S, Lee J, Wu M, Hsu M. A novel splice mutation in the ATP2C1 gene in a woman with concomitant psoriasis vulgaris and disseminated Hailey-Hailey disease. *International Journal of Dermatology* 2012; 51: 947-951. [PMID: 22788811]
12. Szigeti R, Cho S-C, Szasz O, Teszas A, Kosztolanyi G, Kellermayer R. Premenstrual exacerbation in calcium ATPase disorders of the skin. *J Eur Acad Dermatol Venereol* 2007; 21: 412-413. [PMID: 17309480]
13. Nanda K, Saldanha C, Jacintha M, Kamath G. Hailey-Hailey disease responding to Thalidomide. *Indian J Dermatol* 2014 Mar; 59(2) :190-2. [PMID: 24700941]