

UC Davis

Dermatology Online Journal

Title

Successful treatment of eosinophilic cellulitis with dapsone

Permalink

<https://escholarship.org/uc/item/9v67b10b>

Journal

Dermatology Online Journal, 22(7)

Authors

Coelho de Sousa, Virgínia
Laureano Oliveira, André
Cardoso, Jorge

Publication Date

2016

DOI

10.5070/D3227031648

Copyright Information

Copyright 2016 by the author(s). This work is made available under the terms of a Creative Commons Attribution-NonCommercial-NoDerivatives License, available at <https://creativecommons.org/licenses/by-nc-nd/4.0/>

Peer reviewed

Case Presentation

Successful treatment of eosinophilic cellulitis with dapsone.

Virgínia Coelho de Sousa, André Laureano Oliveira, Jorge Cardoso

Dermatology Online Journal 22 (7): 11

Department of Dermatology and Venereology, Hospital de Curry Cabral – Centro Hospitalar de Lisboa Central, Lisboa, Portugal

Correspondence:

Virgínia Coelho de Sousa, MD
Hospital de Curry Cabral – Centro Hospitalar de Lisboa Central, Lisboa, Portugal
Rua da Beneficência, nº8, 1069-166 Lisboa, Portugal
Tel. +351926826029
Email: virginiacoelhodesousa@gmail.com

Abstract

A 55-year-old woman presented with a 3-year history of recurrent episodes of pruritic cellulitis-like erythematous plaques, mostly located on the limbs. Simultaneously, fever, malaise and peripheral eosinophilia were noted. The clinical diagnosis of eosinophilic cellulitis (also known as Wells' syndrome) was supported by the histopathological finding of typical "flame figures". Treatment with dapsone was initiated at a dose of 50 mg per day. After one year of follow-up the patient was relapse-free. Eosinophilic cellulitis is an uncommon, recurrent inflammatory skin disease. The management is often a challenge, due to the frequent need for long-term therapy. Dapsone is an effective and safe treatment option.

Keywords: Dapsone, Eosinophilic cellulitis, Urticaria, Wells' syndrome

Introduction

Eosinophilic cellulitis or Wells' syndrome is a rare, recurrent inflammatory skin disease of unknown etiology [1]. Clinical presentation hallmarks include a pruritic cellulitis-like eruption often accompanied by general malaise and peripheral eosinophilia.

Case synopsis

A 55-year-old woman presented to our clinic with a 3-year history of recurrent episodes of painful and pruritic, urticaria-like erythematous plaques. These skin lesions were mostly located on the upper and lower limbs. The episodes lasted for about 2 weeks. The lesions healed without scarring.

On physical examination, few well-defined, edematous and firm erythematous plaques were seen on the forearms, legs and abdominal wall. Multiple associated excoriations were also observed. The remaining examination was unremarkable.

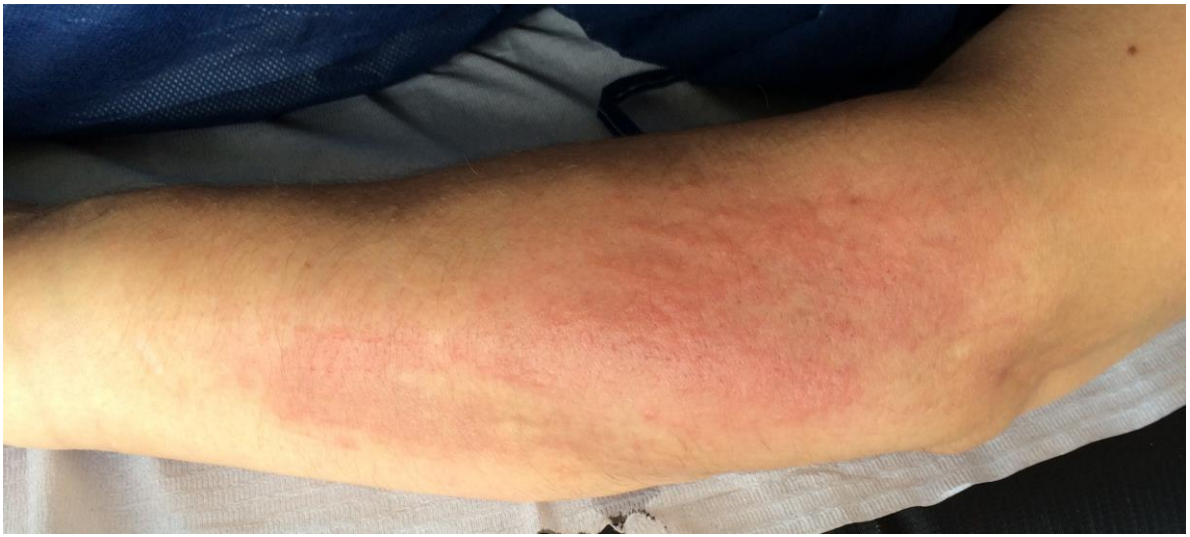

Figure 1. Well-defined, edematous and erythematous plaque on the right forearm.

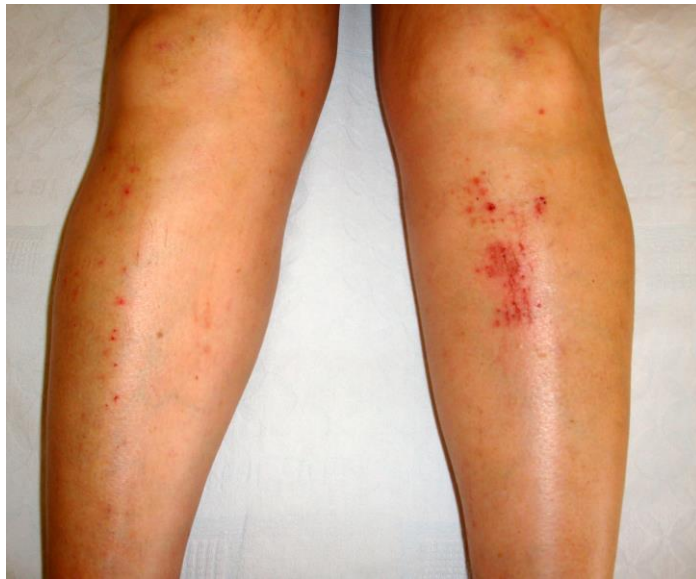

Figure 3. Erythematous and excoriated plaques on the legs.

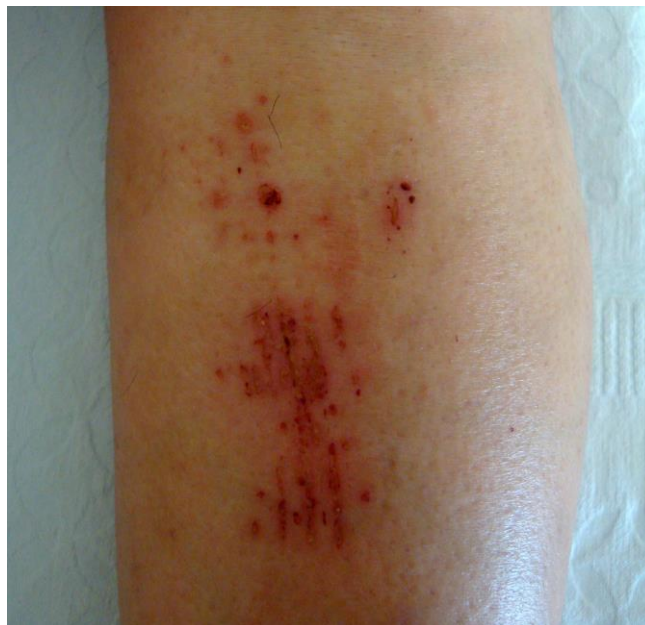

Figure 3. Excoriated, erythematous plaques on the legs (detail).

A biopsy specimen from one of the plaques was taken. Histopathological examination revealed a diffuse and heavy dermal infiltrate of eosinophils and few lymphocytes. “Flame figures” were also observed, resulting from degeneration of eosinophils and deposition of eosinophilic material and nuclear debris on collagen fibers.

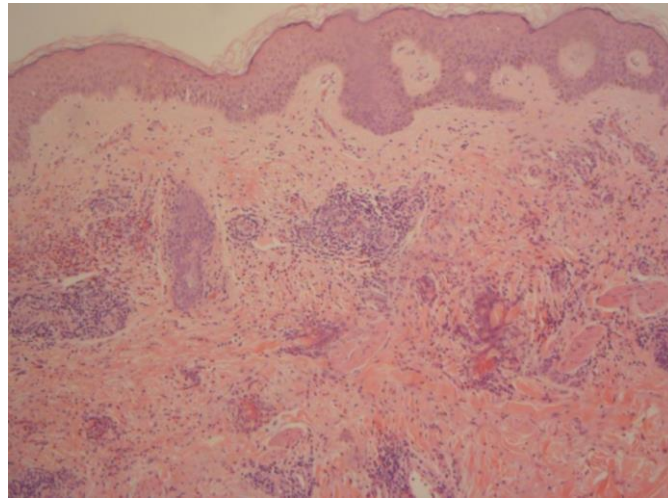


Figure 4. Histopathological examination revealed a dermal infiltrate of eosinophils and “flame figures” (hematoxylin and eosin, x 100)

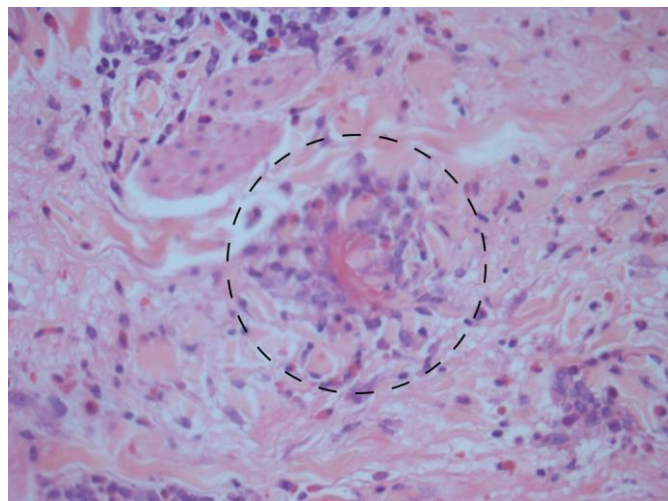


Figure 5. Detail of typical “flame figure” (black circle) with dermal collagen fibers coated with eosinophils (hematoxylin and eosin, x 200).

Blood analysis performed simultaneously to one of the episodes revealed peripheral eosinophilia ($564/\mu\text{L}$, normal range 30-350/ μL).

Clinical and histological correlation supported the diagnosis of eosinophilic cellulitis. The diagnosis of eosinophilic cellulitis was established based on the following features: episodic erythematous and edematous, well-defined (cellulitis-like) plaques, simultaneous constitutional symptoms (general malaise and fever) and peripheral eosinophilia, and typical “flame figures”.

Dramatic improvement was seen after administration of oral prednisolone. However, frequent recurrences were observed with tapering of steroid dose. Additional courses of systemic corticosteroids were needed. Long-term therapy with dapsone was then started at a dose of 50 mg per day (glucose-6-phosphate dehydrogenase within normal range). The patient was relapse and steroid-free after one year of follow-up. No dapsone-related effects were noted.

Discussion

Eosinophilic cellulitis is an uncommon recurrent inflammatory skin disease of unknown etiology, first described by Wells in 1971. There is no sex predominance and a large age range was found in the few reported cases. Clinical presentation characteristically includes a pruritic cellulitis-like eruption with peripheral eosinophilia (observed in 50% of cases). However, a wide variety of clinical presentation have been described: blisters, nodules, papulovesicles and excoriated inflammatory papules. The syndrome commonly affects the extremities and trunk. The episodes are associated with general malaise and less frequently with fever [2].

Clinical differential diagnoses include acute cellulitis, urticaria, fixed drug eruption, pemphigoid and morphea (late stages). Histopathological hallmarks include a marked infiltration of eosinophils in the dermis admixed with some lymphocytes and histiocytes sometimes extending into the subcutaneous fat. Spongiosis and intraepidermal vesicles can be present. Over a period of one to three weeks, eosinophils degranulate. Therefore, typical “flame figures” correspond to collagen fibers coated with eosinophilic granules [1,2]. Although characteristic of eosinophilic cellulitis, “flame figures” are not pathognomonic. They may be seen in drug hypersensitivity reactions, atopic and allergic contact dermatitis, tinea, arthropod bite reactions, bullous pemphigoid, urticarial vasculitis, cutaneous mastocytoma, eosinophilic pustular folliculitis and hypereosinophilic syndrome.

The management of eosinophilic cellulitis is often a challenge considering its relapsing nature. Hence the frequent need for long-term and steroid-sparing therapy. Several treatment options were reported with variable results: topical (mild disease) and systemic corticosteroids, cyclosporine, interferon- α , antimicrobial agents (minocycline, griseofulvin) and anti-histamines.

As shown in our patient, dapson is an effective and well-tolerated drug. Complete response is usually achieved with daily low doses [3]. The mechanisms of action of dapson in eosinophilic cellulitis are still under discussion. Its anti-inflammatory and immunomodulatory properties, and inhibitory effects on eosinophil peroxidase are favored [4].

Conclusion

Dapson is an effective treatment option in eosinophilic cellulitis. It is safe for long-term management, without the adverse effects of other possible drugs, including corticosteroids and immunosuppressive therapies.

References

1. Peckruhn M, Tittelbach J, Schliemann S, Elsner P. Life of lesions in eosinophilic cellulitis (Wells syndrome) – a condition that may be missed at first sight. *Am J Dermatopathol*. 2015;37(2):e15-7 [PMID: 25238447]
2. Consigny S, Courville P, Young P, Richard C, Gauthier V, Maillard V, Detienne A, Joly P, Lauret P. Histological and clinical forms of the eosinophilic cellulitis. *Ann Dermatol Venereol*. 2001 Mar;128(3 Pt 1):213-6. [PMID: 11319382]
3. Bokotas C, Kouris A, Stefanaki C, Sgotzou T, Christofidou E, Kontochrispoulos G. Wells Syndrome: response to dapson therapy. *Ann Dermatol*. 2014;26(4):541-2. [PMID: 25143695]
4. Bozeman PM, Learn DB, Thomas EL. Inhibition of the human leukocyte enzymes myeloperoxidase and eosinophil peroxidase by dapson. *Biochem Pharmacol* 1992;44:553-563 [PMID: 1324677]