

Oral lesions as an important marker for HIV progression

Paulo Henrique Braz-Silva^{1,2} DDS MSc PhD, Juliana Lucena Schussel^{3,4} DDS MSc PhD, Karen López Ortega⁵ DDS MSc PhD, Marina Gallottini⁵ DDS MSc PhD

Affiliations: ¹Laboratory of Virology, Institute of Tropical Medicine of São Paulo, University of São Paulo, São Paulo, Brazil ²Department of Stomatology, Division of General Pathology, School of Dentistry, University of São Paulo, São Paulo, Brazil ³Department of Oral and Maxillofacial Surgery, Erasto Gaertner Hospital, Curitiba, Paraná, Brazil ⁴Department of Stomatology, Graduate Program in Dentistry, Universidade Federal do Paraná, Curitiba, Brazil ⁵Department of Stomatology, Division of Oral and Maxillofacial Pathology, Special Care Dentistry Center, School of Dentistry, University of São Paulo, São Paulo, Brazil

Corresponding Author: Prof. Paulo Henrique Braz-Silva, Instituto de Medicina Tropical de São Paulo – Universidade de São Paulo, Laboratório de Virologia, Av. Dr. Enéas de Carvalho Aguiar, 470, 05403-000, São Paulo -SP -Brazil, Tel: 55 11 26488144, Email: pbraz@usp.br

Abstract

Background: Oral hairy leukoplakia (OHL) is a benign lesion caused by Epstein-Barr virus (EBV) replication in the oral epithelium affecting the borders of the tongue. It is strongly associated with immunosuppression, especially in HIV+ adults but is uncommon in pediatric population. The aim of the study is to show the importance of the correct diagnosis of OHL and its influence on HIV treatment. We report two cases of HIV+ adolescent patients that presented with leukoplakic lesions on the border of the tongue, suggestive of OHL. OHL diagnosis was confirmed in only one case through EBV in situ hybridization. After confirmation of the diagnosis, the patient with OHL was referred to an infectious disease specialist with the decision to start antiretroviral therapy. Conclusion: OHL definitive diagnosis can help clinical management of pediatric HIV+ patients.

Keywords: oral hairy leukoplakia, pediatric HIV patient, EBV

Introduction

Oral hairy leukoplakia (OHL) is described as corrugated white plaques that cannot be scrapped off, more commonly seen along the lateral borders of the tongue [1]. OHL is a result of Epstein-Barr virus (EBV) infection of the oral epithelial mucosa. It is strongly associated with HIV infection, but may be associated with other immunosuppressive conditions. It is usually seen in adults, but is

considered rare in children [2-4]. Other conditions in the differential diagnosis include frictional hyperkeratosis, pseudomembranous candidiasis, lichen planus, white sponge nevus, idiopathic leukoplakia, oral squamous cell carcinoma, and benign migratory glossitis [5]. Histopathological and cytopathological features are not pathognomonic of OHL and may include hyperkeratosis, epithelial hyperplasia, ballooning "koilocyte"-like cells, acanthosis, and a mild inflammatory infiltrate [6]. The nuclear changes may also show Cowdry bodies that are not exclusively seen in EBV infection [7]. The gold standard for definitive diagnosis of OHL is EBV detection by in situ hybridization (ISH), [6, 8]. We report 2 cases suggestive of OHL in HIV+ teenagers.

Introduction

Case 1: A 14-year-old girl, HIV positive since birth, was referred to the Special Care Dentistry Center, School of Dentistry, University of São Paulo for routine consultation. Intraoral examination revealed bilateral white plaques on the lateral borders of the tongue that could not be scrapped off (**Figure 1A**). The CD4+ count, dated four months before the consultation, was 500 cells/mm³ and HIV viral load was undetectable. The clinical impression was OHL and an exfoliative cytology and biopsy were subsequently performed. Both histological and cytological examinations were compatible with OHL and included hyperkeratosis and acanthosis with minimal inflammation in the subepithelial mucosa (**Figure 1B**). Diagnostic confirmation was obtained through ISH for EBV detection (probe EBER, Dako Cytomation, Carpinteria, CA), which allowed the detection of EBV DNA within the epithelial cells of the

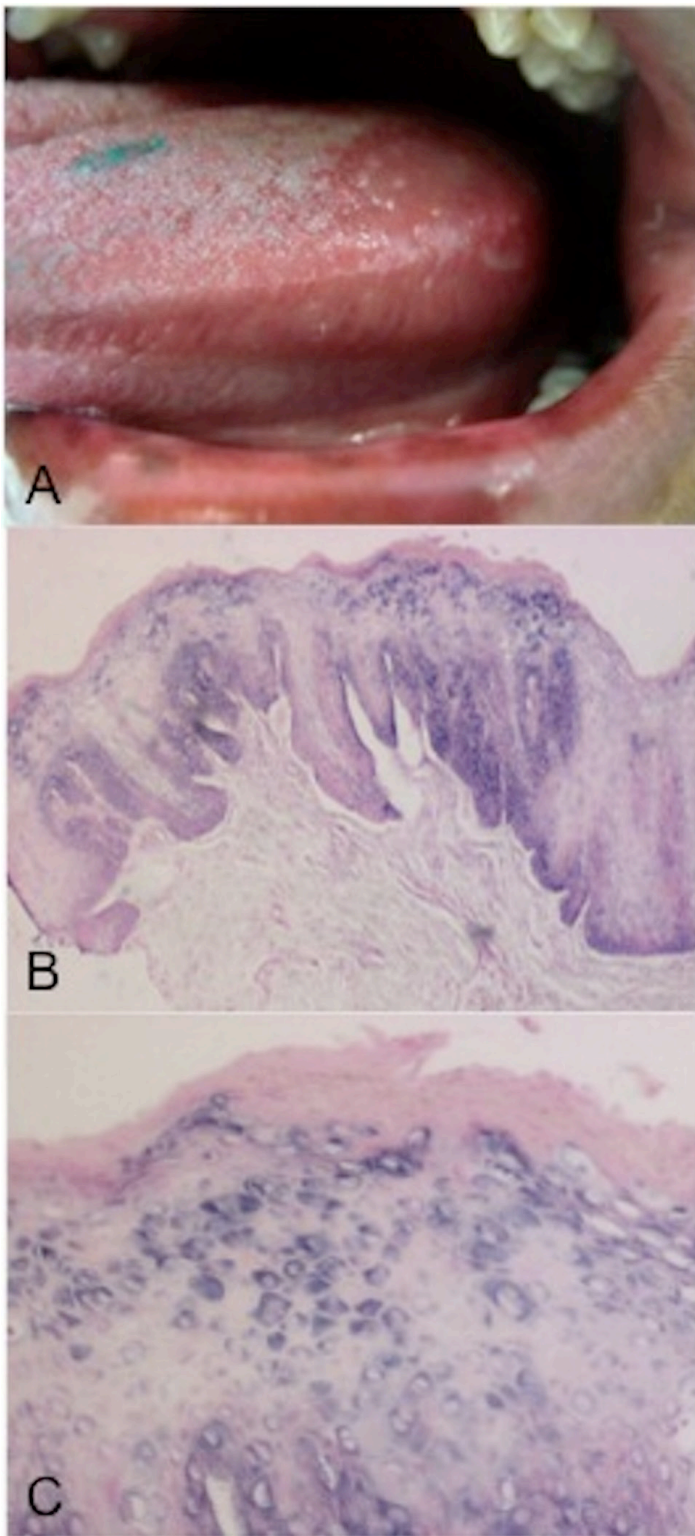


Figure 1. A) White lesion on lateral border of the tongue. B) Histological aspect showing hyperkeratosis, acanthosis, minimal inflammation in subepithelial tissues. C) In situ hybridization showing EBV DNA within the epithelial cells of the lesion.

lesion. (**Figure 1C**). After confirmation of a diagnosis of OHL, the patient was referred to an infectious disease specialist and subsequent laboratory studies showed a decrease in the CD4 count (between 200

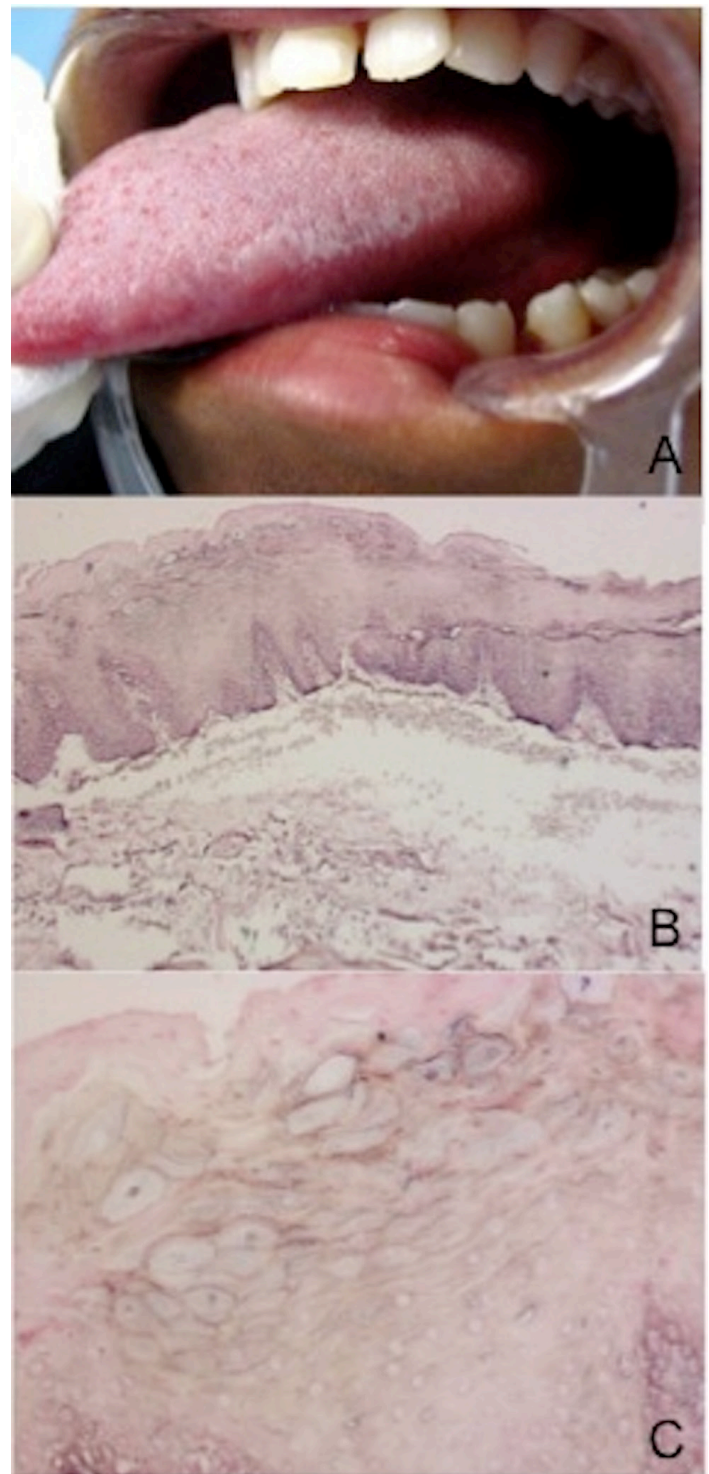


Figure 2. A) Bilateral white plaque on the lateral borders of the tongue that did not wipe off. B) Histology compatible with oral hairy leukoplakia. C) In situ hybridization reaction showed no evidence of EBV DNA

and 400 cells/ mm³). The patient was then started on Highly Active Antiretroviral Therapy (HAART), and a few weeks after initiation of therapy, the lesions on the lateral borders of the tongue disappeared.

Case 2. A 16-year-old black HIV positive girl was referred for routine consultation at Special Care Dentistry Center, School of Dentistry, University of São Paulo. Intraoral examination revealed bilateral white plaques that could not be scrapped off on the lateral borders of the tongue (**Figure 2A**). Her CD4 count was up to 500 cells/ mm³ and she had no detectable viral load. The clinical impression was OHL or frictional hyperkeratosis. Biopsy and exfoliative cytology were performed. Both histological and cytological examinations were compatible with oral hairy leukoplakia (**Figure 2B**), but ISH reaction showed no evidence of EBV DNA (**Figure 2C**), making a diagnosis of OHL unlikely [6]. Based on the diagnosis of frictional hyperkeratosis lesion, a bruxism device was configured. After 3 months follow up, tongue lesions were reduced, CD4 count was still above 500 cells/mm³, and viral load was undetectable.

Conclusion

Oral hairy leukoplakia is strongly associated with HIV disease, but rare in the pediatric population [2-4, 9-14], representing no more than 2.7% of the opportunistic oral lesions that affect pediatric HIV-positive individuals [2, 15].

There are no clinical, histological, or cytopathological features pathognomonic for OHL. Furthermore, the diagnosis of OHL must be confirmed by detection of its etiologic agent, EBV, using molecular biology techniques such as ISH or PCR [6, 8] or electronic microscopy [12]. The ISH is considered the gold standard to detect EBV in oral hairy leukoplakia. PCR is more sensitive, but not specific, because of the high possibility of detecting EBV in saliva when it is not really infecting the oral epithelium. EM is a very difficult technique to perform on a routine basis. Some authors use exfoliative cytology as a diagnostic tool, considering only the cytopathic effects caused by EBV [16]. However, this is not specific and could lead to a misdiagnosis. In both of our cases, the clinical presentation was similar, with bilateral white plaques on the lateral borders of the tongue that could not be scrapped off. Cytological and histopathological examination showed characteristics compatible with OHL features. However, detection of the etiologic agent is essential to exclude other diagnoses that could present similar characteristics [6].

As a benign lesion with low morbidity, OHL does not require specific treatment, but the definitive diagnosis is important because it can be the first sign of advanced immunosuppression in HIV-positive patients [4]. Although the CD4 count is the ideal control for HIV, the diagnosis of AIDS-associated opportunistic lesions can suggest early disease progression.[17, 18]. Berberi et al. [19], in a descriptive cross-sectional study, observed that the severity of OHL oral lesions increased as CD4 count decreased, suggesting that the presence of oral lesions may suggest HIV disease. Naidu et al. [20] found a strong association between a decrease in CD4 counts and the prevalence of oral candidiasis and OHL. In the case reported, initiation of HAART therapy was based on the clinical findings and laboratory test results of the patient [21, 22]. Younger patients infected with HIV progress rapidly to AIDS and antiretroviral therapy results in major reductions of morbidity and mortality. However, it is unclear when is the best moment to start the treatment [21]. A recent published randomized controlled clinical trial corroborates our finding, that oral hairy leukoplakia may indicate immune suppression and the need to start ART [23]. For our first case, the correct diagnosis of OHL allowed the correct clinical management of the patients and was an important indicator to start HAART.

Pediatric HIV-positive patients require special attention so that HAART can be initiated at the right moment. ISH is an easy and safe method for virus detection and is highly recommended for the confirmation of a diagnosis of OHL.

References

1. J.S. Greenspan, D. Greenspan, E.T. Lennette, D.I. Abrams, M.A. Conant, V. Petersen, U.K. Freese, Replication of Epstein-Barr virus within the epithelial cells of oral «hairy» leukoplakia, an AIDS-associated lesion, *N Engl J Med*, 313 (1985) 1564-1571. [PMID: 2999595].
2. M.M. Coogan, J. Greenspan, S.J. Challacombe, Oral lesions in infection with human immunodeficiency virus, *Bull World Health Organ*, 83 (2005) 700-706. [PMID: 16211162].
3. K. Ranganathan, E. Geethalakshmi, U. Krishna Mohan Rao, K.M. Vidya, N. Kumarasamy, S. Solomon, Orofacial and systemic manifestations in 212 paediatric HIV patients from Chennai, South India, *Int J Paediatr Dent*, 20 (2010) 276-282. [PMID: 20536589].
4. F.J. Ramos-Gomez, C. Flaitz, P. Catapano, P. Murray, A.R. Milnes, A. Dorenbaum, Classification, diagnostic criteria, and treatment recommendations for orofacial manifestations in HIV-infected pediatric patients. Collaborative Workgroup on Oral Manifestations of Pediatric HIV Infection, *J Clin Pediatr Dent*, 23 (1999) 85-96. [PMID: 10811111].

- 10204447].
5. D. Triantos, S.R. Porter, C. Scully, C.G. Teo, Oral hairy leukoplakia: clinicopathologic features, pathogenesis, diagnosis, and clinical significance, *Clin Infect Dis*, 25 (1997) 1392-1396. [PMID: 9431384].
 6. P.H. Braz-Silva, N.P. de Rezende, K.L. Ortega, R.T. de Macedo Santos, M.H. de Magalhaes, Detection of the Epstein-Barr virus (EBV) by in situ hybridization as definitive diagnosis of hairy leukoplakia, *Head Neck Pathol*, 2 (2008) 19-24. [PMID: 20614337].
 7. P.H. Braz-Silva, K.L. Ortega, N.P. Rezende, F.D. Nunes, M.H. Magalhaes, Detection of Epstein-Barr virus (EBV) in the oral mucosa of renal transplant patients, *Diagn Cytopathol*, 34 (2006) 24-28. [PMID: 16355381].
 8. J.S. Greenspan, Y.G. De Souza, J.A. Regezi, T.E. Daniels, D. Greenspan, L.A. MacPhail, J.F. Hilton, Comparison of cytopathic changes in oral hairy leukoplakia with in situ hybridization for EBV DNA, *Oral Dis*, 4 (1998) 95-99. [PMID: 9680897].
 9. M.B. Portela, G.F. Castro, E.M. Costa, A. Silva Junior, E.P. Dias, I.P. de Souza, Case report on a rare lesion in an HIV-infected child: hairy leukoplakia, *J Clin Pediatr Dent*, 26 (2002) 405-408. [PMID: 12175137].
 10. G. Laskaris, M. Laskaris, M. Theodoridou, Oral hairy leukoplakia in a child with AIDS, *Oral Surg Oral Med Oral Pathol Oral Radiol Endod*, 79 (1995) 570-571. [PMID: 7600219].
 11. F. Mannelli, L. Galli, G. Ficarra, P. Romagnoli, S. Vierucci, M. de Martino, Oral hairy leukoplakia in two children with perinatally acquired HIV-1 infection, *Pediatr AIDS HIV Infect*, 6 (1995) 21-23. [PMID: 11361738].
 12. P.H. Itin, A.J. Bircher, Y. Litzisdorf, C. Rudin, Oral hairy leukoplakia in a child: confirmation of the clinical diagnosis by ultrastructural examination of exfoliative cytologic specimens, *Dermatology*, 189 (1994) 167-169. [PMID: 8075447].
 13. F.S. Ferguson, H. Archard, G.J. Nuovo, S. Nachman, Hairy leukoplakia in a child with AIDS—a rare symptom: case report, *Pediatr Dent*, 15 (1993) 280-281. [PMID: 8247905].
 14. J.S. Greenspan, M.T. Mastrucci, P.J. Leggott, U.K. Freese, Y.G. De Souza, G.B. Scott, D. Greenspan, Hairy leukoplakia in a child, *Aids*, 2 (1988) 143. [PMID: 3132949].
 15. M.G. Magalhaes, D.F. Bueno, E. Serra, R. Goncalves, Oral manifestations of HIV positive children, *J Clin Pediatr Dent*, 25 (2001) 103-106. [PMID: 11314206].
 16. E.P. Dias, M.S. Israel, A. Silva Junior, V.A. Maciel, J.P. Gagliardi, R.H. Oliveira, Prevalence of oral hairy leukoplakia in 120 pediatric patients infected with HIV-1, *Braz Oral Res*, 20 (2006) 103-107. [PMID: 16878201].
 17. I.D. Miziara, B.C. Filho, R. Weber, Oral lesions in Brazilian HIV-infected children undergoing HAART, *Int J Pediatr Otorhinolaryngol*, 70 (2006) 1089-1096. [PMID: 16406081].
 18. M. Nesti, E. Carli, C. Giaquinto, O. Rampon, S. Nastasio, M.R. Giuca, Correlation between viral load, plasma levels of CD4 - CD8 T lymphocytes and AIDS-related oral diseases: a multicentre study on 30 HIV+ children in the HAART era, *J Biol Regul Homeost Agents*, 26 (2012) 527-537. [PMID: 23034272].
 19. A. Berberi, Z. Noujeim, AIDS: An Epidemiologic and Correlation Between HIV- Related Oral Lesions and plasma levels of CD4, CD8 T Lymphocytes Counts and Ratio Among 50 Patients, *J Int Oral Health*, 7 (2015) 18-21. [PMID: 25709361].
 20. G.S. Naidu, R. Thakur, A.K. Singh, S. Rajbhandary, R.K. Mishra, A. Sagtani, Oral lesions and immune status of HIV infected adults from eastern Nepal, *J Clin Exp Dent*, 5 (2013) e1-7. PMID: PMC3892227].
 21. D. Dunn, Short-term risk of disease progression in HIV-1-infected children receiving no antiretroviral therapy or zidovudine monotherapy: a meta-analysis, *Lancet*, 362 (2003) 1605-1611. [PMID: 14630440].
 22. G. Verweel, J. Saavedra-Lozano, A.M. van Rossum, O. Ramilo, R. de Groot, Initiating highly active antiretroviral therapy in human immunodeficiency virus type 1-infected children in Europe and the United States: comparing clinical practice to guidelines and literature evidence, *Pediatr Infect Dis J*, 25 (2006) 987-994. [PMID: 17072119].
 23. A.S. Batavia, R. Secours, P. Espinosa, M.A. Jean Juste, P. Severe, J.W. Pape, D.W. Fitzgerald, Diagnosis of HIV-Associated Oral Lesions in Relation to Early versus Delayed Antiretroviral Therapy: Results from the CIPRA HT001 Trial, *PLoS One*, 11 (2016) e0150656. [PMID: 26930571].