

# Herpetic infection in Hailey-Hailey disease

Subin Lim<sup>1\*</sup> BA, Katie A O'Connell<sup>1,2\*</sup> MD MS, Robert J Pariser<sup>3</sup> MD

\*Authors contributed equally

Affiliations: <sup>1</sup>Department of Dermatology, Eastern Virginia Medical School, Norfolk, Virginia, USA, <sup>2</sup>Department of Medicine, Vanderbilt University Medical Center, Nashville, Tennessee, USA, <sup>3</sup>Pariser Dermatology Specialists, Norfolk, Virginia, USA

Corresponding Author: Robert J Pariser MD, Pariser Dermatology Specialists, 6160 Kempsville Circle, Norfolk, VA 23502, Tel: 757-622-6315, Email: [rpariser@gmail.com](mailto:rpariser@gmail.com)

*Keywords: familial, Hailey-Hailey, herpes simplex, pemphigus, virus*

To the Editor:

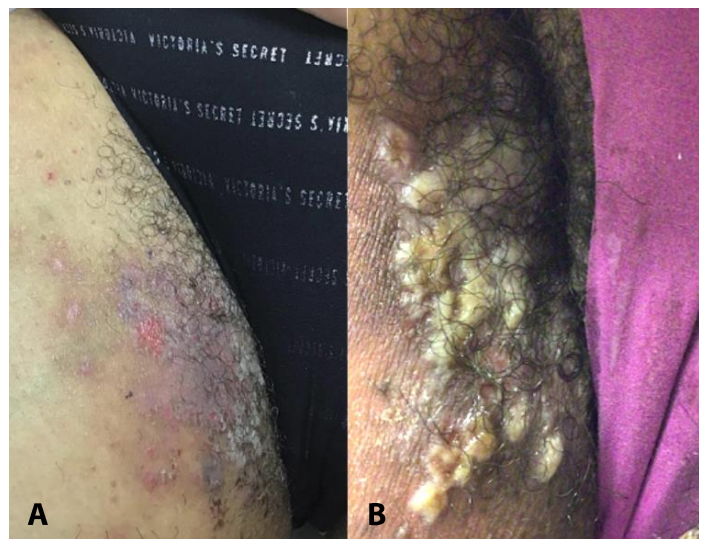
Hailey-Hailey disease (HHD), or familial benign pemphigus, is a rare, autosomal dominant genodermatosis with complete penetrance and variable expressivity in affected family members [1,2]. Clinically, it presents between the third and fourth decade of a person's life with symmetrically distributed vesicles, erosions, and fissures typically in intertriginous areas. Given its chronic, relapsing course and the dearth of evidence-based guidelines regarding treatment, management of HHD remains challenging. Severe flare-ups and spontaneous remissions can occur. The condition confers substantial social and psychological burden on patients [2].

A 45-year-old woman presented in 2013 with a history of adult-onset "eczema" predominantly located in the flexures (**Figure 1A**). There was a maternal history of similar skin disease. A skin biopsy showed full-thickness epidermal acantholysis in an acanthotic epidermis, confirming the clinical impression of HHD. She was treated with various topical agents (clindamycin, triamcinolone), oral agents (doxycycline, naltrexone), and antiseptics, with minimal improvement. Temporary improvement was reported following a trial of botulinum toxin Type A injections into the affected area.

In 2021, she presented with an acute exacerbation of painful, coalescent clusters of vesico-pustules on an erythematous base in the bilateral inguinal folds

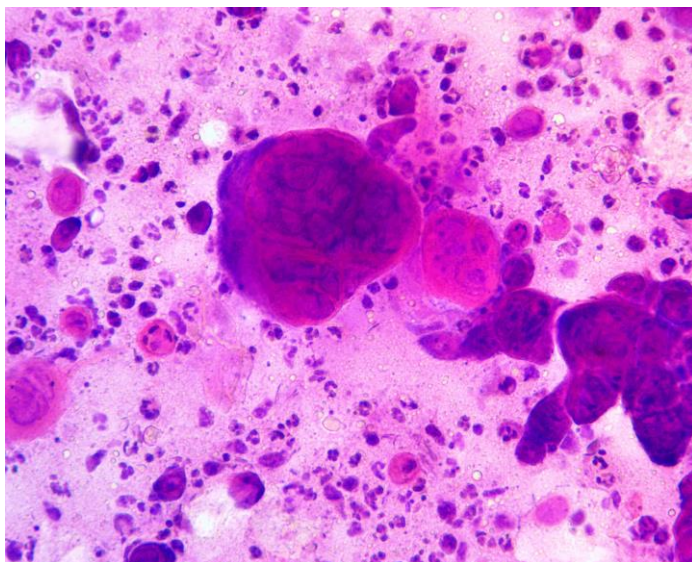
(**Figure 1B**). A Tzanck smear showed numerous multinucleated giant cells, indicating herpetic infection (**Figure 2**). Polymerase chain reaction (PCR) testing confirmed the presence of herpes simplex virus (HSV). Oral valacyclovir and topical Dakin solution (sodium hypochlorite) soaks produced resolution over the next 10 days.

As can be seen in other dermatoses in which epidermal barrier function is disrupted (e.g., atopic and contact dermatitis, pemphigus, pityriasis rubra pilaris, Darier disease), HHD can become secondarily infected with herpes simplex virus. Other risk factors



**Figure 1. A)** Erythema, erosions, and scale crusts of right inguinal area prior to acute flareup. **B)** Coalescent clusters of vesico-pustules on an erythematous base in the same area at presentation in 2021.

in this pathogenesis include use of topical calcineurin inhibitors and/or corticosteroids [1]. This relatively rare concurrence can be erroneously attributed to a flare-up of the HHD if not suspected. Contributing to possible histopathologic confusion is the secondary acantholysis which can result from



**Figure 2.** Multinucleated giant cells on Tzanck smear, 40x.

HSV infections and could be erroneously attributed to HHD; occasionally clusters of acantholytic, dyskeratotic keratinocytes may be found in HHD, which may simulate the true multinucleate giant cells of HSV infection [3]. Tzanck preparations can provide rapid, bedside diagnostic confirmation of HSV infection, justifying prompt initiation of antiviral medication [1]. Viral culture, PCR, and/or immunofluorescent testing can provide diagnostic confirmation, albeit somewhat delayed [4].

Clinicians should consider the possibility of HSV infection in acutely flaring HHD and in other chronic dermatoses at risk for this condition. Extensive involvement, as in Kaposi varicelliform eruption/eczema herpeticum, is a dermatologic emergency with significant morbidity and mortality [3].

### Potential conflicts of interest

The authors declare no conflicts of interest.

### References

1. de Aquino Paulo Filho T, deFreitas YK, da Nóbrega MT, Lima CB, Carriço BL, Silva MA, Paulo FL, Neto PB. Hailey-Hailey disease associated with herpetic eczema-the value of the Tzanck smear test. *Dermatol Pract Concept*. 2014;4:29-31. [PMID: 25396081].
2. Ben Lagha I, Ashack K, Khachemoune A. Hailey-Hailey Disease: An Update Review with a Focus on Treatment Data. *Am J Clin Dermatol*. 2020;21:49-68. [PMID: 31595434].
3. Leitch CS, Panthagani AP, Tidman MJ, Biswas A. Hailey-Hailey Disease With Coexistent Herpes Virus Infection: Insights Into the Diagnostic Conundrum of Herpetic/Pseudoherpetic Features in Cutaneous Acantholytic Disorders. *Am J Dermatopathol*. 2018;40:749-53. [PMID: 28475517].
4. Chin AGM, Asif M, Hultman C, Caffrey J. Hailey-Hailey Disease with Superimposed Eczema Herpeticum Caused by Herpes Simplex Virus Type 2 Infection in a Burn Unit: A Case Report and Literature Review. *Cureus*. 2019;11:e5907. [PMID: 31777694].