

Erythematous scaly plaques and nodules on scalp

Peiyong Audrey Ho¹ MB BCH BAO, Yee Yen Gwee² MBBS, Choon Chiat Oh¹ MBBS FRCP UK FAMS

Affiliations: ¹Department of Dermatology, Singapore General Hospital, Singapore, ²Department of Pathology, Singapore General Hospital, Singapore

Corresponding Author: Choon Chiat Oh, Department of Dermatology, Singapore General Hospital, Outram Road, Singapore, 169608, Tel: 65-62223322, Fax: 65-62249221, Email: oh.choon.chiat@singhealth.com.sg

Abstract

Cutaneous manifestations of syphilis are varied and may present with non-specific features. We describe a 45-year-old man who presented with erythematous scaly plaques and nodules on his scalp. In previously reported cases, there were only descriptions of nodules as well as tumors. However, in our case, the patient presented with plaques and nodules on his scalp that quickly resolved with treatment for syphilis. It is important to recognize and treat syphilis at an early stage.

Keywords: infection, scalp, syphilis

Introduction

Scalp manifestations of syphilis may be non-specific and confused with psoriasis, seborrheic dermatitis, tinea capitis, lichen planopilaris, or alopecia areata [1]. Often syphilis is not suspected when the clinical presentation is of erythematous, scaly plaques and nodules of the scalp.

Case Synopsis

A 45-year-old man with a past medical history of hypertension and hyperlipidemia was referred to the dermatology clinic for sudden onset of rash over his scalp over the past two months. There was no cervical, axillary, or inguinal lymphadenopathy. There were no systemic symptoms of fever, malaise, or influenza. There were erythematous adherent thick scaly plaques and nodules on his scalp (**Figure**

1) and an erythematous maculopapular rash involving the trunk and back. The eruption had first started on the trunk before spreading to the rest of the body, involving the scalp. There were no new medications prior to the onset of the eruption. He had faint confluent erythematous macules on his trunk; his palms and soles were spared and the oral examination was unremarkable. A scalp biopsy was performed.

Histopathology showed interface dermatitis and marked periadnexal as well as perivascular inflammation composed of plasma cells, lymphocytes, histiocytes, scattered neutrophils and eosinophils. Intraepithelial neutrophils are seen forming occasional microabscesses and were associated with inflammatory exudate within the surface parakeratin (**Figure 2**). Blood investigations

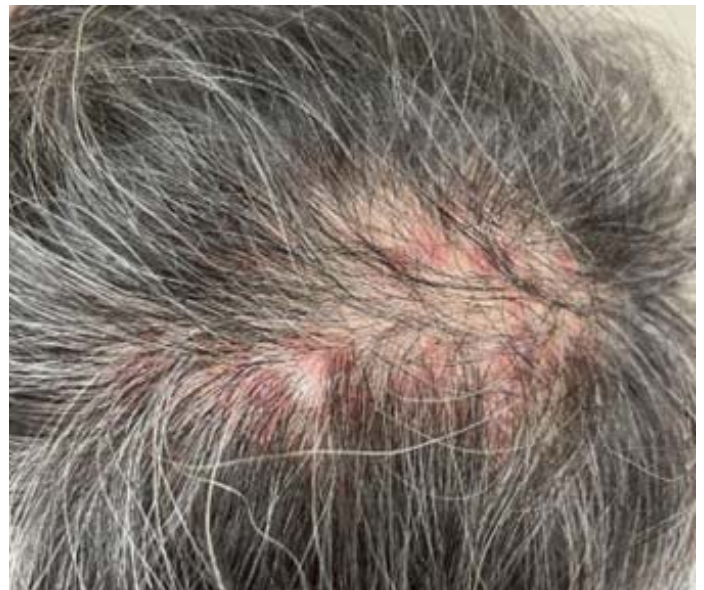

Figure 1. Erythematous plaques and nodules on scalp.

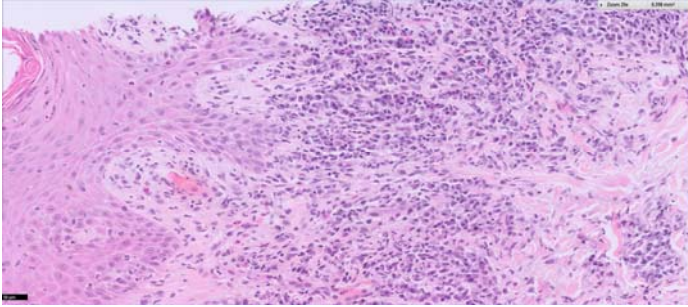


Figure 2. H&E histopathology shows perivascular lymphocytic infiltrate and plasma cells, 20x.

revealed that his *Treponema pallidum* particle agglutination assay (TPPA) was reactive and venereal disease research laboratory test (VDRL) was positive with a titer of 1:256.

He was treated for secondary syphilis with one dose of intramuscular penicillin. Subsequently, the scalp nodules and plaques resolved with post-inflammatory hyperpigmentation (**Figure 3**).

The differential diagnosis for erythematous plaques on the scalp is wide-ranging, with psoriasis possibly being amongst the more common. Histology is required to differentiate psoriasis from a plaque due

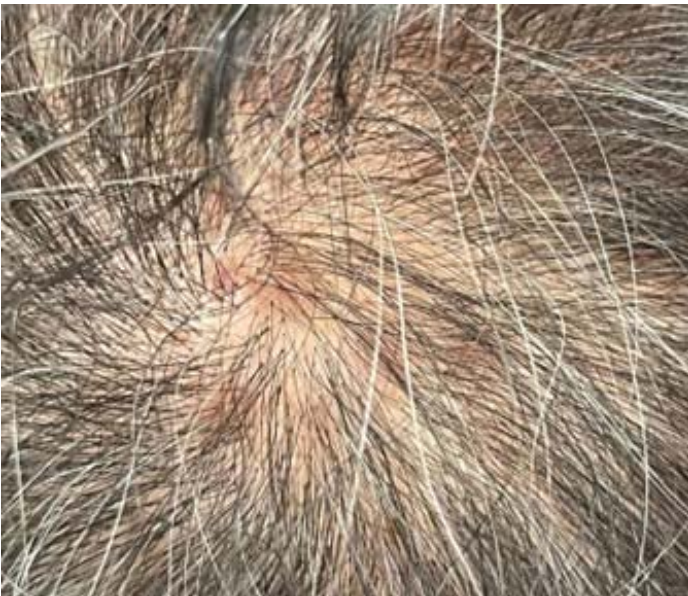

Figure 3. Resolution of plaques with residual post-inflammatory hyperpigmentation.

to syphilis [1]. Other possible diagnoses include seborrheic dermatitis, tinea capitis, and lichen planopilaris. The recommended regimen for adults for the treatment of secondary syphilis is one dose of 2.4 million units of benzathine penicillin G given intramuscularly [2]. In our patient, the erythematous plaques on his scalp completely resolved with treatment of secondary syphilis.

Case Discussion

Syphilis is a disease caused by *Treponema pallidum* and is known as “the great imitator” due to its multitude of cutaneous manifestations varying from a maculopapular rash that also affect the palmoplantar regions, to nodular, annular, pustular, and framboesiform lesions affecting various other sites on the body. With regard to duration, cutaneous secondary syphilis eruption usually presents 3- 10 weeks after the initial contact with the spirochete; the typical duration of cutaneous secondary syphilis eruption is that of weeks to months [3]. Scalp lesions are less commonly reported. In previously reported cases, there were descriptions of nodules, tumors, and alopecia over the scalp [4]. A summary of these case reports is presented in [Table 1](#).

Conclusion

It is important to recognize and treat syphilis at an early stage, to prevent the subsequent complications of tertiary syphilis. However, secondary syphilis can present atypically, which may lead to delayed diagnosis and treatment. Hence, it is important for clinicians to consider cutaneous secondary syphilis in patients with nodules or plaques on scalp.

Potential conflicts of interest

The authors declare no conflicts of interest.

References

1. Gisondi P, Bellinato F, Girolomoni G. Topographic differential

diagnosis of chronic plaque psoriasis: challenges and tricks. *J Clin*

- Med.* 2020;9:3594. [PMID: 33171581].
2. Workowski KA, Bolan GA; Centers for Disease Control and Prevention. Sexually transmitted diseases treatment guidelines, 2015 *MMWR Recomm Rep.* 2015;1-137. [PMID: 26042815].
 3. Stone CE, Onyekaba NA, Lucas M, Jukic D. Cutaneous secondary syphilis resembling non-melanoma skin cancer. *Cureus.* 2020;12:e10774. [PMID: 33033668].
 4. Al-Busani H, Namiki T, Miura K, Yokozeki H. Mixed-pattern syphilitic alopecia of the scalp associated with uveitis and asymptomatic neurosyphilis. *J Dermatol.* 2020;4:e311-e313. [PMID: 32441352].
 5. Park JH, Park YJ, Kim SK, et al. Histopathological differential diagnosis of psoriasis and seborrheic dermatitis of the scalp. *Ann Dermatol.* 2016;28:427-432. [PMID: 27489423]
 6. Li F, Wang T, Wang L. Secondary syphilis primarily presenting with multiple nodules on the scalp: Case report and published work review. *J Dermatol.* 2017;4:1401-1403. [PMID: 28714113].
 7. Wang X, Chen H, Sun J. Multiple nodules on the scalp as the only cutaneous symptom of secondary syphilis. *Int J Dermatol.* 2019;58:e203-e204. [PMID: 31236934].
 8. Tham SN, Ng SK. Secondary syphilis with framboesiform lesions. *Genitourin Med.* 1990;66:99-100. [PMID: 2341147].
 9. Lee ES, Lee MG, Lee JB. Tumorous syphilid. *Genitourin Med.* 1990;66:202-204. [PMID: 2370064].

Table 1. Cases reported for syphilis presenting as nodules/plaques on scalp.

Author	Li F et al [6]	Wang X et al [7]	Tham SN et al [8]	Lee ES et al [9]
Number of Patients	1	1	1	1
Gender	Male	Male	Male	Male
Age	51	62	40	31
Length of Duration of Nodules	2 months	3 weeks	1 month	1 month
Description of nodules	Multiple rounded yellow to red to dull red, non tender nodules over scalp	Multiple non tender firm red nodules over scalp	Multiple crusted papules nodules on scalp	Erythematous oozing tumors on scalp
Other symptoms	Nil	Nil	Cervical, axillary and inguinal lymphadenopathy	Nil
Histopathological Findings	Hyperplasia of epidermis, abundant perivascular infiltration in dermis mainly plasma cells.	Epidermal hyperplasia, dense neutrophilic infiltrate in upper epidermis. Infiltration in dermis mainly plasma cells.	Parakeratosis with scaly crusts, irregular epidermal hyperplasia with spongiiform pustules and infiltration of neutrophils and lymphocytes in epidermis. Dermoepidermal junction- plasma cells, eosinophils, neutrophils, lymphocytes	Epidermis showed verrucous hyperplasia. Upper and mid dermis-heavy polymorphic infiltrate with perivascular and periappendageal arrangement, mainly plasma cells and eosinophils.
Serological Testing	TPPA >1: 320 TRUST 1:8	RPR 1:64 TP-IgG and TPPA positive	VDRL 1: 2048	VDRL 1:32, FTA-ABS reactive 4+, TPHA 1: 20480, 19s(IgM)-FTA 1:1280
Immunohistochemistry	Warthin-Starry staining and immunohistochemical staining TP polyclonal antibody 1:100	Warthin-Starry silver staining and Periodic acid-Schiff negative TP polyclonal antibody 1:200	-	Warthin-Starry stain negative, immunoperoxidase stain with avidin-biotin peroxidase complex demonstrated many <i>T. pallida</i> in epidermis and around dermal blood vessels.
Secondary Infection	Nil	Nil	Staphylococcus aureus	Nil
Treatment	IM Benzathine penicillin G 2.4 MU once a week for 3 weeks	IM Benzathine penicillin G 2.4 MU once a week for 3 weeks	IM Benzathine Penicillin G 2.4 MU once a week for 2 weeks	IM Benzathine Penicillin G 2.4 MU once a week for 3 weeks
Duration to resolution/drop in titers	3 months to resolution of skin lesions TRUST titer still 1:8	3 months to resolution of lesions and 3 fold decrease in titers	2 months to resolution of lesions. 6 months for titers to drop to 1:32	1 month after initiation of therapy, skin lesions resolved. 6 months later, titers of serologic testing decreased: VDRL 1:4, FTA-ABS 4+, TPHA 1: 2560, 19s (IgM)-FTA 1:80

IM, intramuscular; TP, *T. pallida*; TPPA, Treponema pallidum particle agglutination assay; VDRL, venereal disease research laboratory test.