

# Clear cell acanthoma on the areola

Luis J Borda MD, Joshua S Mervis BA, Paolo Romanelli MD, Hadar Lev-Tov MD

Affiliations: Department of Dermatology and Cutaneous Surgery, University of Miami Miller School of Medicine, Miami, Florida, USA

Corresponding Author: Hadar Lev-Tov, M.D., Department of Dermatology & Cutaneous Surgery, University of Miami Miller School of Medicine, 1600 NW 10th Avenue, RMSB 2023A, Miami, FL 33136, Tel: 305-243-6734, Email: [hlevtov@med.miami.edu](mailto:hlevtov@med.miami.edu)

## Abstract

Clear cell acanthoma (CCA) is a rare, benign cutaneous condition most often seen on the lower extremities. Lesions are of variable morphology and have been described as polypoid, pigmented, giant, and cystic lesions. Although no racial or gender predilection has been reported, CCA on the breast is a very rare finding that has been observed mainly in young Korean women. Herein, we describe a case of CCA of the areola in an elderly woman with metastatic renal cell carcinoma. Physical exam revealed a pink plaque with central erosions on the left areola. Given the concern for cutaneous metastasis, excisional biopsy was performed, which showed pale glycogenated epithelium consistent with CCA. No evidence of recurrence or new lesions was observed after 6 months of follow-up. Our case exemplifies that clinicians should consider CCA in the differential diagnosis for a new eczematous lesion involving the breast, even in the setting of malignancy.

*Keywords: clear cell acanthoma, renal cell carcinoma, areola, breast, metastasis*

## Introduction

Clear cell acanthoma (CCA) is an uncommon, benign skin lesion of unknown etiology most often seen on the lower extremities of middle-age to elderly adults [1]. CCA typically presents as an asymptomatic, slow-growing, well-demarcated pink to red papule or nodule 5-20mm in size [1]. Variable morphologies, have been described, including polypoid, pigmented, giant, and cystic forms [1, 2]. Lesions are usually solitary but may be multiple. A linear, pinpoint "string of pearls" pattern revealing the

vascular component of CCA may be seen on dermatoscopic exam, potentially aiding clinical diagnosis and explaining why CCA is prone to bleed after minimal trauma [2-4]. Whereas no gender or racial predilection has been observed [3], CCA of the nipple or areola is a very rare finding that has been reported primarily in young Korean women. Herein, we describe a case of clear cell acanthoma of the areola in an elderly Hispanic woman.

## Case Synopsis

An 80-year-old woman from Cuba presented to the outpatient dermatology clinic with an asymptomatic lesion on her left breast that she first noticed two weeks prior. On physical exam, the patient had a 15mm pink plaque with central erosions and collarette of fine scale on the superior aspect of the left areola (Figure 1). The patient was previously diagnosed with RCC and treated with right nephrectomy three years prior. However, her disease had subsequently metastasized to bone, for which she was receiving infusions of nivolumab every 2

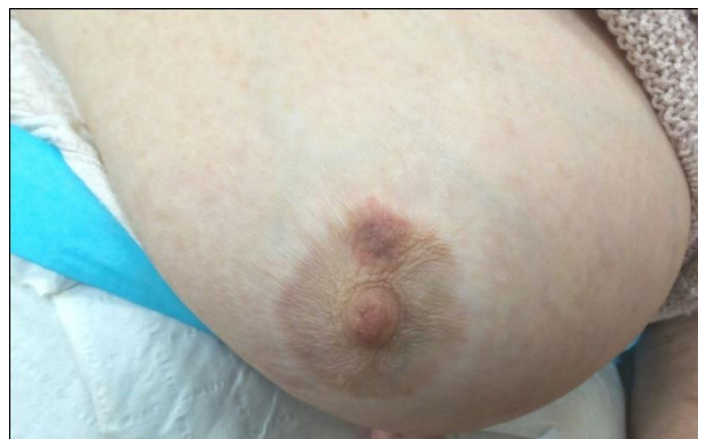

Figure 1. Pink to hyper-pigmented plaque on the upper part of the left areola with surrounding erythema and small erosions in the center

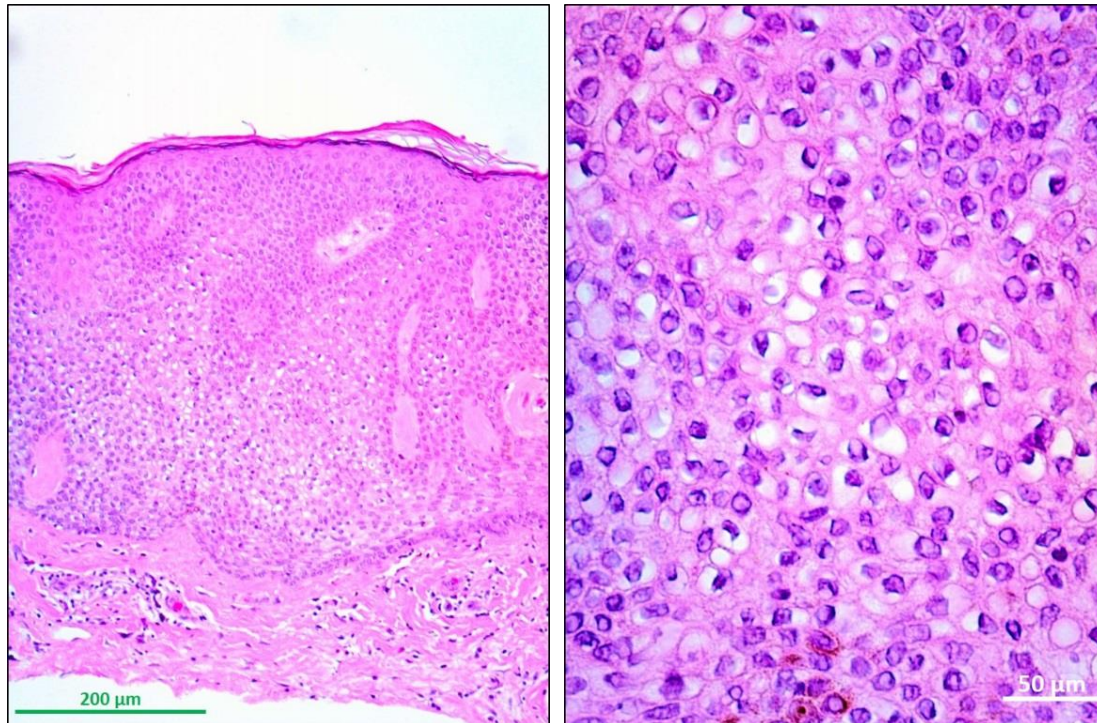


Figure 2. Pale-staining keratinocytes associated with acanthosis. A) Well demarcated area of psoriasiform epidermal hyperplasia in which keratinocytes have pale-staining cytoplasm (i.e. vacuoles with glycogen as content), H&E, 20 $\times$ . B) Close-up of (A) in which pale-staining keratinocytes are seen. Disorganized keratinocytes and thickening of the spinous layer (i.e. acanthosis) within lower epidermal layers, H&E, 40 $\times$ .

weeks. She also had hypertension, diabetes, and congestive heart failure. She did not report a history of atopic dermatitis but did note generalized pruritus for the few months prior to presentation. Her current medications included spironolactone, sacubitril/valsartan, potassium chloride, nebivolol, and alprazolam. Given the patient's history of metastatic RCC, there was significant concern for a cutaneous neoplastic process, thus the lesion was excised. Histology showed epidermal acanthosis, intermittent broad and slender rete pegs with focal fusion of the acanthotic down-growths, pale glycogenated epithelium, and numerous neutrophils within the epidermis extending into the focally eroded stratum corneum (Figure 2A, B). These findings were consistent with CCA. No evidence of recurrence or new skin lesions was seen after 6 months of follow-up.

### Case Discussion

CCA of the nipple or areola is a very rare finding, to our knowledge previously reported in only 10

patients [2, 5]. All but one of the cases were in women and predominantly occurred within the second to third decade of life. Moreover, these patients were predominantly Asian, with five from Korea, one from the Philippines, two from Brazil, and two from Europe. Based on these previous reports, **our patient's case is atypical** given her significantly older age and Hispanic origin.

Although often considered a benign epidermal neoplasm of unknown etiology, some authors have suggested CCA may be a reactive phenomenon secondary to chronic inflammation, as evidenced by its common concurrence with inflammatory skin diseases such as psoriasis or atopic dermatitis [6, 7]. Lending credence to the inflammatory hypothesis are these rare cases of CCA of the nipple and areola, nearly all of which have manifested as eczematous lesions in patients with a history of atopic dermatitis. Interestingly, our patient had complained of generalized pruritus for the few months prior to presentation, but she reported no history of atopy. Furthermore, Park et al. have noted that nipple

eczema is significantly more common in Asians than Caucasians [8], suggesting that this finding could explain the apparent tendency of CCA of the breast to be found in Asians. The preferred treatment options have been surgical resection and cryotherapy with no recurrences observed [2]. Additionally, four cases were successfully treated with topical corticosteroids, leading to complete resolution over the course of several weeks, further supporting an inflammatory etiology for this lesion [9, 10]. If CCA were truly a neoplastic process, treatment with corticosteroids would not be expected to lead to a resolution.

The clinical diagnosis of CCA can be challenging, and the differential diagnosis of CCA on the nipple or areola may include basal cell carcinoma, squamous

cell carcinoma, Paget disease, eczema, psoriasis, and seborrheic keratosis. In our patient, particular concern was for a neoplastic process given her age, history of metastatic RCC, and the rapid onset of the lesion, although the areolar lesion turned out to be coincidental in this case. Histology lends a fairly straightforward diagnosis of CCA, revealing distinctive glycogen-filled keratinocytes with clear cytoplasm that is positive for the Periodic acid–Schiff stain.

## Conclusion

In summary, dermatologists should keep CCA in the differential diagnosis for a new eczematous lesion involving the breast. The etiology of this benign lesion remains elusive.

## References

1. Portal C, Fang F, Kanner W, Wilson B. Clear cell acanthoma. *Cutis*. 2013;92(2):62,77-9. [PMID: 24087787].
2. Hidalgo-Garcia Y, Gonzalvo P, Mallo-Garcia S, Fernandez-Sanchez C. Clear Cell Acanthoma of the Areola and Nipple. *Actas Dermosifiliogr*. 2016;107(9):793-5. [PMID: 27206609].
3. Cetinozman F, Jansen P, Willemze R. Clear cell acanthoma on the dorsum of the hand. *J Eur Acad Dermatol Venereol*. 2016;30(2):378-80. [PMID: 25353276].
4. Zalaudek I, Kreusch J, Giacomel J, et al. How to diagnose nonpigmented skin tumors: a review of vascular structures seen with dermoscopy: part II. Nonmelanocytic skin tumors. *J Am Acad Dermatol*. 2010;63(3):377-86; quiz 87-8. [PMID: 20708470].
5. Gonzalez-Guerra E, Rodriguez JR, Casado AF, et al. Bilateral clear cell acanthoma of the areola and nipple: good response to topical corticosteroids. *An Bras Dermatol*. 2017;92(5 Suppl 1):27-9. [PMID: 29267438].
6. Jacyk WK, Baran W, Essop A. Multiple pigmented clear cell acanthoma in an African patient. *J Eur Acad Dermatol Venereol*. 2016;30(3):494-6. [PMID: 25414053].
7. Degos R, Civatte J. Clear-cell acanthoma. Experience of 8 years. *Br J Dermatol*. 1970;83(2):248-54. [PMID: 4916780].
8. Park SY, Jung JY, Na JI, Byun HJ, Cho KH. A case of polypoid clear cell acanthoma on the nipple. *Ann Dermatol*. 2010;22(3):337-40. [PMID: 20711275].
9. Nazzaro G, Coggi A, Gianotti R. A 26-year-old man with an eczematous lesion on the nipple. *Arch Dermatol*. 2012;148(5):641-6. [PMID: 22782156].
10. Veiga RR, Barros RS, Santos JE, et al. Clear cell acanthoma of the areola and nipple: clinical, histopathological, and immunohistochemical features of two Brazilian cases. *An Bras Dermatol*. 2013;88(1):84-9. [PMID: 23539008].