

# Painful subcutaneous nodules in an alcoholic: a case of pancreatic panniculitis

Marianne Cortes<sup>1</sup> BS, Brittany P Smirnov<sup>2</sup> DO FAAD

Affiliations:<sup>1</sup>Kiran C Patel College of Osteopathic Medicine, Nova Southeastern University, Davie, Florida, <sup>2</sup>Fuchs Dermatology, Falls Church, VA

Corresponding Author: Brittany P Smirnov DO, Fuchs Dermatology, 6565 Arlington Boulevard, Suite 102, Falls Church, VA 22042, Tel: 202-281-9208, Email: [Brittany.p.smirnov@gmail.com](mailto:Brittany.p.smirnov@gmail.com)

## Abstract

Pancreatic panniculitis is an uncommon manifestation of pancreatic disease, affecting approximately 2-3% of patients with acute or chronic pancreatitis [1]. Its accurate diagnosis is crucial for effective treatment as skin manifestations usually precede systemic symptoms of pancreatitis. The diagnosis of pancreatic panniculitis requires identifying and confirming pancreatic disease in addition to the typical histopathological findings of lobular panniculitis without vasculitis. Herein, we present a patient with pancreatic panniculitis, underlying acute pancreatic failure, and kidney injury.

*Keywords: necrosis, pancreatitis, panniculitis, subcutaneous nodules*

## Introduction

The first case of pancreatic panniculitis was initially described by Chiari in 1883, characterized by necrosis of subcutaneous fat [1-3]. This entity continues to be a rare manifestation today, occurring with higher incidence in middle-aged male patients with a history of alcoholism [1]. Though still mostly unknown, the pathogenesis of pancreatic panniculitis is believed to be secondary to the massive release of pancreatic enzymes resulting in peripheral fat degradation (lipolysis), [3,4].

Pancreatic panniculitis clinically presents as painful, erythematous, subcutaneous nodules that may

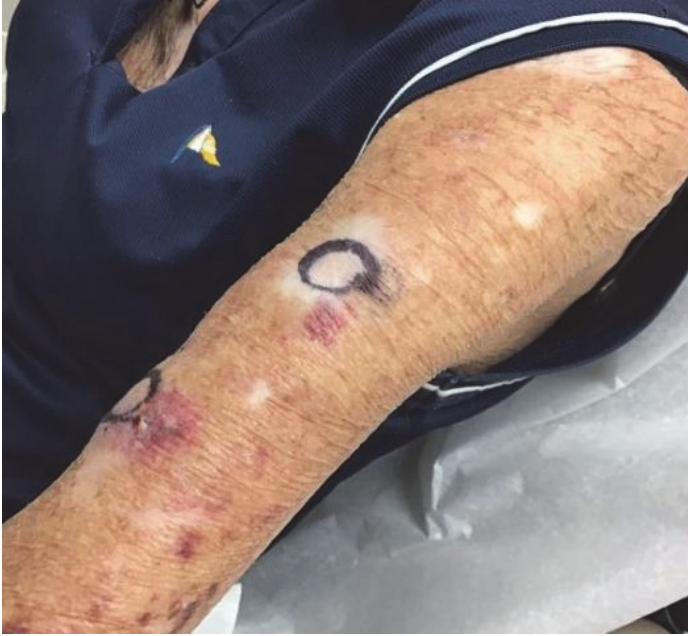ulcerate spontaneously and exude an oily brown substance [2]. Lesions classically present on the distal extremities but may also appear on the trunk, chest, buttocks, and scalp [4]. The skin manifestations have also been reported to occur with acute arthritis and can precede abdominal symptoms of pancreatitis by 1-7 months [1].

## Case Synopsis

A 58-year-old woman with a past medical history of hypothyroidism, chronic anemia, alcoholism, and multiple keratinocytic carcinomas presented to the outpatient dermatology clinic with the complaint of painful firm lumps on the left upper arm and right abdomen for the past month. In addition to these lesions, the patient reported associated weight loss and nausea. Her social history included alcohol and tobacco abuse spanning multiple years.

Clinical evaluation revealed firm, rubbery, fixed subcutaneous nodules measuring 3cm at the aforementioned locations. A 7mm punch biopsy using the double-punch method was obtained from the left proximal posterior upper arm (**Figure 1**).

Histologic examination revealed ghost adipocytes consistent with pancreatic panniculitis (**Figures 2**). Focal lobular panniculitis with saponification were appreciated along with the ghost adipocytes consisting of anucleate adipocytes filled with amorphous granular debris surrounded by an eosinophilic border. Inflammatory cells surrounding necrotic fat were also seen.



**Figure 1.** Circular markings outline the scattered subcutaneous nodules over the upper left extremity in which punch biopsies were taken.

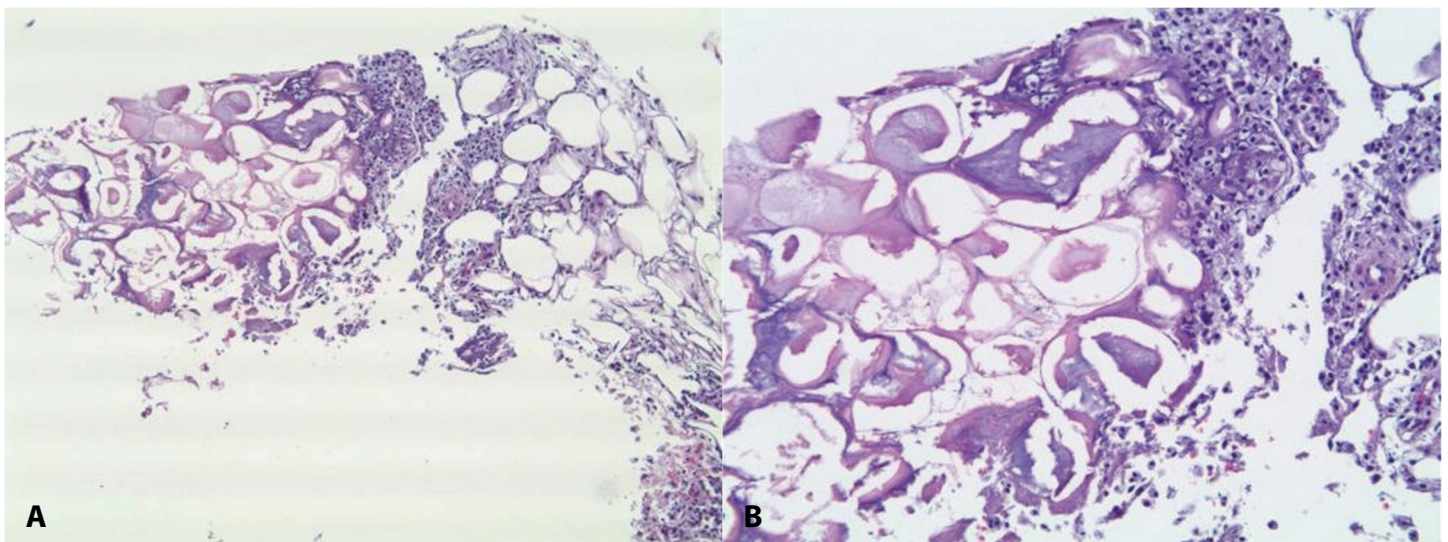
She was subsequently referred to a local hospital where she was determined to have acute pancreatitis with a serum lipase of 3,302 U/L (normal range: 0-160 U/L) and an amylase of 165 U/L (normal range: 40-140 U/L). CT without contrast of the abdomen and pelvis depicted inflammation of the pancreas and layering stones in the gallbladder. The patient was admitted for supportive treatment of pancreatitis leading to the resolution and softening

of the subcutaneous nodules in the subsequent three months.

### Case Discussion

The clinical findings of firm nodules in pancreatic panniculitis can mimic those of other panniculitides such as erythema nodosum, erythema induratum, or subcutaneous metastasis [4]. Evaluation of the biopsy specimen revealed focal lobular necrotic fat with areas of ghost-like appearance along with basophilic hue and adjacent mixed infiltrate, distinctive of pancreatic panniculitis (**Figure 2**).

In addition, laboratory tests can depict elevated amylase, lipase, and trypsin levels and occasionally elevated tumor markers such as carcinoembryonic antigen. Although the pathogenesis of pancreatic panniculitis is not fully understood, it is hypothesized that the release of high amounts of pancreatic enzymes may lead to a focal necrosis of lipids with an accompanying inflammatory reaction [1]. It has also been suggested that additional factors are necessary for the development of pancreatic panniculitis such as increased vessel permeability as this allows the pancreatic enzymes to enter the circulation and into subcutaneous fat [2]. Treatment of pancreatic panniculitis is mostly supportive and aims to target any underlying pancreatic pathology [1].



**Figure 2.** H&E histopathology. **A)** Focal lobular panniculitis with saponification and ghost adipocytes, 5x. **B)** A closer look at the ghost adipocytes depicts anucleate adipocytes composed of amorphous granular debris with an eosinophilic border, 20x. Inflammatory cells surrounding necrotic fat can also be appreciated.

## Conclusion

Pancreatic panniculitis is a rare but important morphological manifestation of acute pancreatitis that can precede the clinical diagnosis of pancreatitis by months. This is a prime example of the importance of early biopsy for proper identification of panniculitic etiology. The skin manifestation of pancreatic panniculitis precedes the more well-known presentation of pancreatitis, highlighting the

importance of an accurate diagnosis for early treatment. This case emphasizes the need for clinicians to develop a high index of suspicion for the early and appropriate diagnosis of pancreatic panniculitis.

## Potential conflicts of interest

The authors declare no conflicts of interest.

## References

1. Guanzioli E, Colombo A, Coggi Antonella, et al. Pancreatic Panniculitis: the 'Bright' Side of the Moon in Solid Cancer Patients. *BMC Gastroenterol.* 2018;18:1. [PMID: 29301491].
2. Kunovsky L, Dite P, Brezinova E, et al. Skin Manifestations of Pancreatic Diseases. *Biomed Pap med Fac Univ Palacky Olomouc Czech Repub.* 2022;166:353-358. [PMID: 35938387].
3. Milani-Nejad N, Johnson AG, Chung CG. Nonpancreatic Pancreatic Panniculitis: An Incidental Finding in Individuals without Pancreatic Disease? A Case Series and Review of the Literature. *J Clin Aesthet Dermatol.* 2021;14:28-30. [PMID: 34055184].
4. Miulescu R, Balaban DV, Sandru F, Jinga M. Cutaneous Manifestations in Pancreatic Diseases – A Review. *J Clin Med.* 2020;9:2611. [PMID: 32806580].