

UC Davis
Dermatology Online Journal

Title

Plate-like osteoma cutis

Permalink

<https://escholarship.org/uc/item/9pn8q4dc>

Journal

Dermatology Online Journal, 20(12)

Authors

Orme, Charisse M
Hale, Christopher S
Meehan, Shane A
et al.

Publication Date

2015

DOI

10.5070/D32012025052

Copyright Information

Copyright 2015 by the author(s). This work is made available under the terms of a Creative Commons Attribution-NonCommercial-NoDerivatives License, available at <https://creativecommons.org/licenses/by-nc-nd/4.0/>

Peer reviewed

Case Presentation

Plate-like osteoma cutis

Charisse M. Orme MD PhD, Christopher S. Hale MD, Shane A. Meehan MD, and Wendy Long MD

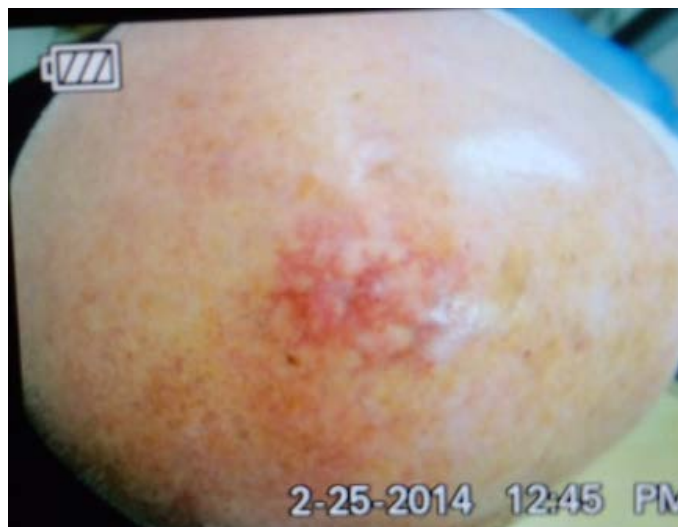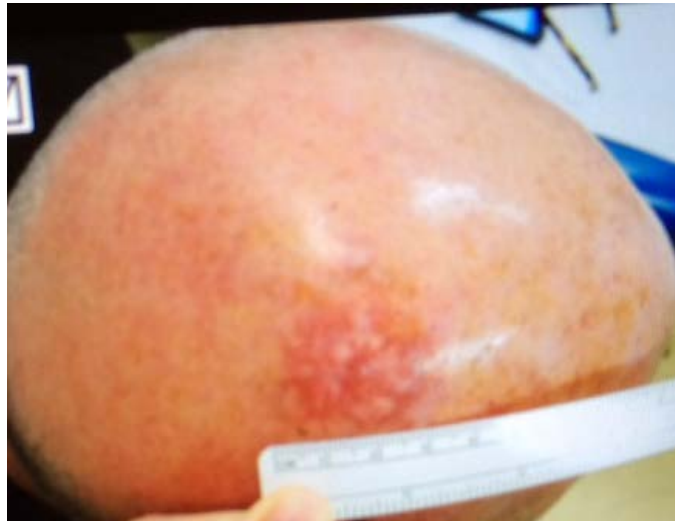Dermatology Online Journal 20 (12): 1

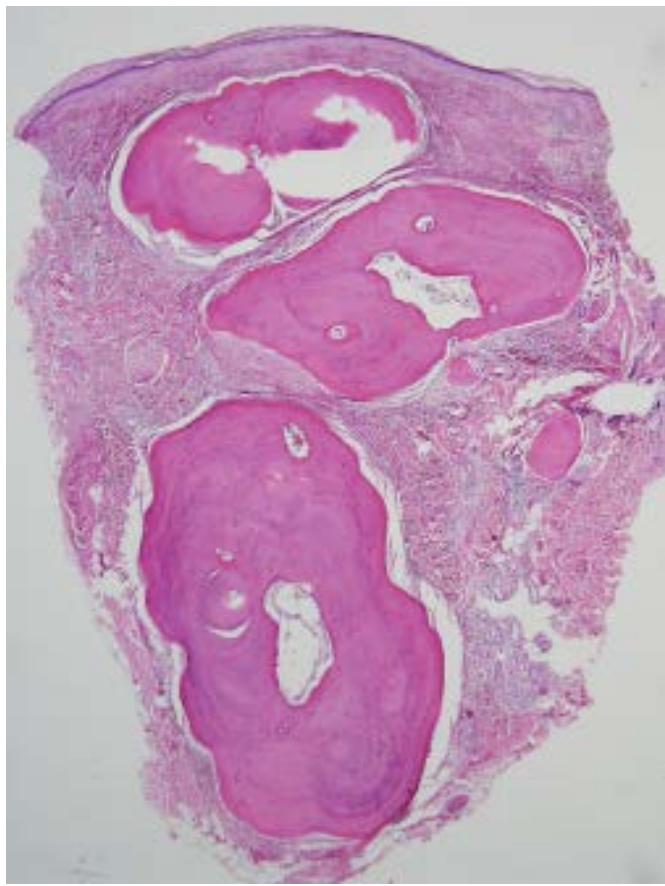
New York University School of Medicine

Special Guest Editor: Nicholas A. Soter, MD

Abstract

Osteoma cutis is the aberrant development of bone within the skin. The bone formation may be *de novo* (primary) or result from an injury to the skin (secondary). Here we present a healthy 53-year-old man with no known abnormalities in calcium or phosphate metabolism with plate-like osteoma cutis of the scalp. Plate- or plaque-like osteoma cutis was initially described as a congenital condition but has now been reported several times in the literature as an idiopathic process that occurs in adults. Treatment options are limited and are only required if the lesion is bothersome to the patient.





Case synopsis

History: A 53-year-old man presented to a private dermatologist with an asymptomatic, firm lump of the vertex of the scalp that had been present since childhood. The patient recalled that his parents were given the diagnosis of benign cyst. Biopsy of the lesion was never performed. When the patient was in his early twenties, a dermatologist unsuccessfully attempted to remove part of the plaque and a scar resulted. As the patient grew older, he developed androgenetic alopecia and the lump became visibly noticeable owing to the absence of hair. Over the past ten years, the patient noticed the development of white bumps and red discoloration of the area. He denied itching, bleeding, or pain at the site of the lesion.

Physical examination: On the vertex of the scalp, there was a firm, non-tender, 3 x 3-cm, pink-red plaque that was studded with white papules. There was no surrounding scale or erythema.

Laboratory data: None

Histopathology: There is a well-circumscribed, nodular aggregate of irregularly shaped lamellar bone. At the periphery, there are compressed collagen fibers.

Discussion

Diagnosis: Plate-like osteoma cutis

Comment: Osteoma cutis (OC) is the aberrant formation of mature lamellar bone within the dermis and subcutaneous tissue [1]. The presence of osteoblasts and osteocytes along with deposition of hydroxyapatite crystals is similar in appearance to normal bone [2].

The bone deposition that is observed in osteoma cutis is classified as primary or secondary. Primary cutaneous bone formation is relatively rare and accounts for approximately 15% of the cases [3, 4]. The clinical pattern of bone formation in primary osteoma cutis is separated into four types: isolated, widespread, multiple military facial, and plate-like [5]. Primary osteoma cutis may be idiopathic in nature or may be associated with the dysregulation of calcium and phosphate metabolism that is observed in some hereditary syndromes [1, 6]. These syndromes include Albright hereditary osteodystrophy, progressive osseous heteroplasia, and

fibrodysplasia ossificans progressiva. Mutations in *GNAS1*, which is a gene that encodes for a protein known to regulate adenylyl cyclase activity, have been implicated in the development of primary osteoma cutis that is associated with these syndromes [7-9].

Secondary osteoma cutis represents the majority (85%) of instances of bone formation that is observed in the skin [3, 4]. In this subset, the aberrant bone formation is thought to be related to prior trauma, tumor, or inflammation of the skin. The most common dermatologic conditions that are associated with secondary osteoma cutis include acne vulgaris, basal-cell carcinoma, nevi, dermatomyositis, pilomatricomas, and pilar cysts [3-5].

The term plaque-like osteoma was first used in 1978 by Worret and Burgdorf [10] and referred to a type of congenital, idiopathic, plate-like primary osteoma cutis [5, 7, 11]. Since that time, others have reported acquired, idiopathic, plate- or plaque-like forms of primary osteoma cutis that developed in older children and adults [12-21]. Similar plate-like growths also have been described for secondary osteoma cutis [22]. The most common location for acquired, plate-like osteoma cutis is on the head and scalp of men [21]. Personal distress over appearance, physical discomfort, and transdermal elimination have been reported for these lesions.

Several treatment modalities have been suggested for osteoma cutis and depend on the extent and location of bone deposition. These include erbium: YAG laser, topical tretinoin, and surgical excision [13, 23-27]. Surgical excision is the primary modality for treatment of plate-like lesions. Removal may be challenging or impractical and depends on the site involved, but success without recurrence has been reported [12, 13].

In the patient presented, it is unclear if his plate-like osteoma cutis was the lump first identified in childhood or if he acquired the bone formation later in life after partial surgical excision of the area. The patient did note increasing numbers of white bumps in his scalp after his hairline had receded and well after the surgical procedure in his twenties. These findings make secondary, plate-like osteoma cutis more likely. Because he was asymptomatic from his lesion, the patient declined surgical excision.

References

1. Orlow SJ, et al. Skin and bones. II. *J Am Acad Dermatol* 1991;25:447 [PMID: 1918486]
2. Cottoni F, et al. Primary osteoma cutis: clinical, morphological, and ultrastructural study. *Am J Dermatopath* 1993;15:77 [PMID: 8434738]
3. Burgdorf W, Nasemann T. Cutaneous osteomas: a clinical and histopathologic review. *Arch Derm Res* 1977;260:121 [PMID: 413495]
4. Roth SI, et al. Cutaneous ossification: report of 120 cases and review of the literature. *Arch Pathol* 1963;76:44 [PMID: 13975332]
5. Sanmartin O, et al. Congenital platelike osteoma cutis: case report and review of the literature. *Pediatr Dermatol* 1993;10:182 [PMID: 8346117]
6. Nakamura S, et al. Primary osteoma cutis. *J Dermatol* 1987;14:85 [PMD: 3112204]
7. Yeh GL, et al. *GNAS1* mutation and *Cbfa1* misexpression in a child with severe congenital platelike osteoma cutis. *J Bone Min Res* 2000;15:2063 [PMID: 11092389]
8. Chan I, et al. Progressive osseous heteroplasia resulting from a new mutation in the *GNAS1* gene. *Clin Exp Dermatol* 2004; 29:77 [PMID: 14723729]
9. Lietman SA, et al. Reduction in *Galpha* induces osteogenic differentiation in human mesenchymal stem cells. *Clin Orthop Relat Res* 2005;231 [PMID: 15864058]
10. 10. Worret WI, Burgdorf W. Angeborenes plattenartiges osteoma cutis bei einem Saugling. *Hautarzt* 1978;29:590 [PMID: 721464]
11. Hernandez-Martin A, et al. Congenital plate-like osteoma cutis in an infant. *Pediatr Dermatol* 2009;26:479 [PMID: 19689534]
12. Henrich DE, et al. Primary osteoma cutis. *Otolaryngol Head Neck Surg* 1997;117:S98 [PMD: 9419115]
13. Ayaviri NA, et al. Isolated primary osteoma cutis of the head: case report. *Canadian J Plast Surg* 2006;14:33 [PMID: 19554229]
14. Cohen PR, et al. Dermal plaques of the face and scalp: platelike osteoma cutis. *Arch Dermatol* 2007;143:109 [PMID: 17224551]
15. Aneiros-Fernandez J, et al. A man with infiltrated and indurated plaque on the forehead. *Dermatol Online J* 2010;16:12 [PMID: 20579467]
16. Vashi N, et al. Acquired plate-like osteoma cutis. *Dermatol Online J* 2011;17:1 [PMID: 22031627]
17. Katz M, Weinrauch L. Primary osteoma cutis. *Cutis* 1985;36:477 [PMID: 4075842]
18. Boschert MT, Puckett CL. Osteoma cutis of the hand. *Plas Reconstruct Surg* 2000;105:1017 [PMID: 10724263]
19. Grandhe N, et al. Acquired perforating primary osteoma cutis. *Acta Dermato-Venereologica* 2004;84:489 [PMID: 15844650]
20. Douri T, Shawaf AZ. Plate-like cutaneous osteoma on the scalp. *Dermatol Online J* 2006;12:17 [PMID: 17083872]

21. Haro R, et al. Plaque-like osteoma cutis with transepidermal elimination. *J Cut Pathol* 2009;36:591 [PMID: 19476531]
22. Monroe AB et al. Platelike cutaneous osteoma. *J Am Acad Dermatol* 1987;16:481 [PMID: 3102570]
23. Altman JF, et al. Treatment of primary miliary osteoma cutis with incision, curettage, and primary closure. *J Am Acad Dermatol* 2001;44:96 [PMID: 11148484]
24. Baskan EB, et al. Miliary osteoma cutis of the face: treatment with the needle microincision-extirpation method. *J Dermatolog Treat* 2007;18:252 [PMID: 17671887]
25. Cohen AD et al. Treatment of multiple miliary osteoma cutis of the face with local application of tretinoin (all-trans-retinoic acid): a case report and review of the literature. *J Dermatolog Treat* 2001;12:171 [PMID: 12243710]
26. Ochsendorf FR, Kaufmann R. Erbium: YAG laser ablation of osteoma cutis: modifications of the approach. *Arch Dermatol* 1999;135:1416 [PMID: 10566848]
27. Wilhelmsen HR, Bereston ES. Treatment of osteoma cutis. *Cutis* 1984; 33:481 [PMID: 6236955]