

# UC Davis

## Dermatology Online Journal

### Title

Nuclear matrix protein 2 antibody-positive adult dermatomyositis: a case report and review of the literature

### Permalink

<https://escholarship.org/uc/item/9n50x88m>

### Journal

Dermatology Online Journal, 26(3)

### Authors

Cartron, Alexander M  
Osler, Montana  
Chung, Catherine  
et al.

### Publication Date

2020

### DOI

10.5070/D3263047981

### Copyright Information

Copyright 2020 by the author(s). This work is made available under the terms of a Creative Commons Attribution-NonCommercial-NoDerivatives License, available at <https://creativecommons.org/licenses/by-nc-nd/4.0/>

Peer reviewed

# Nuclear matrix protein 2 antibody-positive adult dermatomyositis: a case report and review of the literature

Alexander M Cartron<sup>1</sup> BS, Montana Osler<sup>2</sup> MS, Catherine Chung<sup>2</sup> MD, John C Trinidad<sup>2</sup> MD MPH

Affiliations: <sup>1</sup>Department of Dermatology, University of Maryland School of Medicine, Baltimore, Maryland, USA, <sup>2</sup>Division of Dermatology, Department of Internal Medicine, The Ohio State University Wexner Medical Center, Columbus, Ohio, USA

Corresponding Author: Alexander Cartron, Department of Dermatology, University of Maryland School of Medicine, 419 West Redwood Street, Suite 235, Baltimore MD 21201, Tel: 301-821-0309, Email: [alexander.cartron@som.umaryland.edu](mailto:alexander.cartron@som.umaryland.edu)

## Abstract

Dermatomyositis is a clinically heterogeneous inflammatory myopathy with unique cutaneous features. Myositis-specific antibodies can aid in diagnosis and anticipation of patient prognosis. Herein, we report a 22-year-old man who presented with multifocal erythematous plaques with violaceous papules on his bilateral elbows, neck, and face. He was diagnosed with biopsy-proven dermatomyositis and determined to be seropositive for nuclear matrix protein 2 antibody (NXP-2). He was treated with systemic corticosteroids, then intravenous methylprednisolone and azathioprine, and ultimately achieved greatest treatment response with intravenous immune globulin therapy.

*Keywords: dermatomyositis, NXP-2, myositis-specific antibodies*

## Introduction

Dermatomyositis is an idiopathic inflammatory myopathy characterized by proximal skeletal muscle weakness and muscle inflammation that can be challenging for providers to diagnose [1]. Myositis-specific antibodies including nuclear matrix protein (NXP-2) have emerged as a valuable tool to support clinical features and facilitate timely diagnosis [2-3]. NXP-2 antibodies are more common in younger, Caucasian patients, and are most frequently associated with calcinosis cutis in juvenile dermatomyositis [4]. NXP-2 antibodies may also indicate a poorer prognosis despite milder

cutaneous features [5]. Herein, we present an adult patient with NXP-2-positive dermatomyositis and review relevant clinical features of NXP-2-positive dermatomyositis and treatment algorithms for disease management.

## Case Synopsis

A 22-year-old man presented with two months of fatigue, back and neck pain, and joint pain most prominent in his knees, shoulders, and ankles. He was referred to dermatology clinic for evaluation of a rash on his elbows, neck, and face. Physical examination revealed multifocal erythematous plaques with violaceous papules located on the bilateral elbows (**Figure 1A**), right popliteal fossa, neck (**Figure 1B**), and bilateral face, more prominent on the right than the left side. The patient began triamcinolone 0.1% cream and hydrocortisone 2.5% cream twice daily. Two punch biopsies were performed, one of a lesion on the left elbow and another of the upper back.

The biopsies revealed interface dermatitis (**Figure 2A**). Both specimens demonstrated similar findings including focal vacuolar interface dermatitis, basement membrane thickening, and prominent dermal mucin deposition (**Figure 2B**). The constellation of findings was noted to be most consistent with connective tissue disease. The specimen from the left elbow was also noted to have focal leukocytoclasia suggestive of early leukocytoclastic vasculitis. Given these findings, a

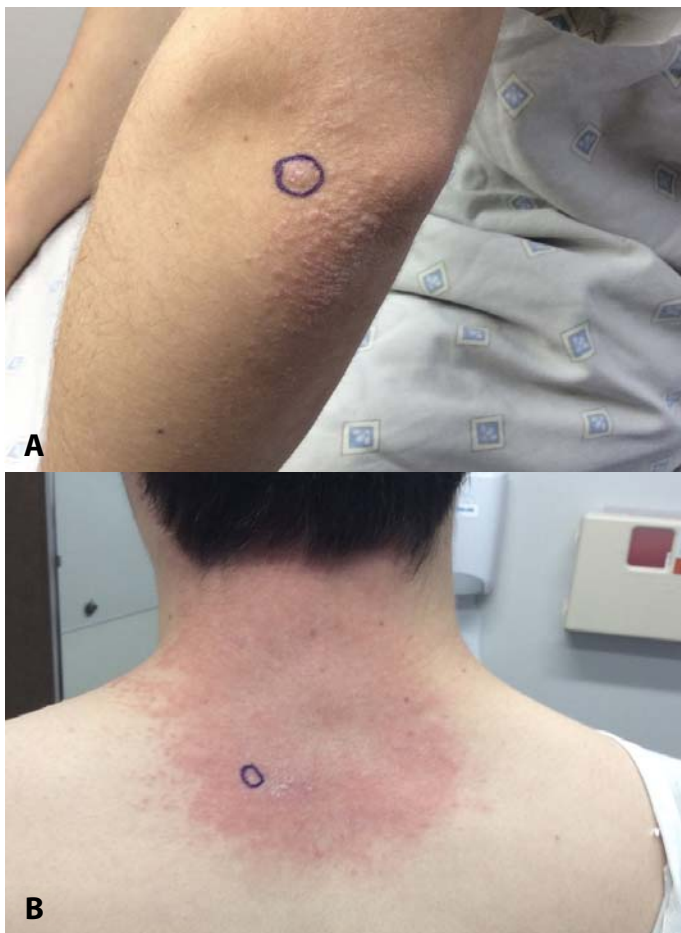prednisone taper was initiated for a presumed autoimmune connective tissue disease.

The patient's C-reactive protein was elevated at 3.9 (normal range <3mg/L) though his erythrocyte sedimentation rate was within normal limits. His cryoglobulin was negative and his rheumatoid factor was unremarkable. Laboratory analysis was significant for a positive anti-chromatin antibody, positive antinuclear antibody screen multiplex, and increased NXP-2 antibodies confirming a diagnosis of dermatomyositis.

The patient reported his myalgia and joint pain improved with prednisone, but he began to have trouble swallowing. However, the primary team did not elect to perform a barium swallow or esophagogastroduodenoscopy. Laboratory analysis

revealed elevated creatine kinase at 2,544 (normal range 30-220U/L) and aldolase elevated at 35 (normal range less than or equal to 8.1U/L). His hepatic function panel was significant for an elevated ALT of 79 (normal range 10-52U/L) and AST of 164 (normal range 14-40U/L). His C3/C4 complement, hepatitis panel, and serum protein electrophoresis were unremarkable.

Needle electromyography was performed on muscles of the right extremities and revealed spontaneous fibrillation potentials and positive sharp waves in proximal muscles consistent with myositis. He began intravenous methylprednisolone therapy and then was started on azathioprine 50mg with sulfamethoxazole trimethoprim 160mg to decrease infection risk. The patient discontinued the sulfamethoxazole trimethoprim owing to an allergic reaction. Given the constellation of clinical symptoms and positive NXP-2 antibodies, paraneoplastic dermatomyositis was considered. Subsequent testicular ultrasound revealed no appreciable changes or abnormalities. A CT of the abdomen and pelvis was also unremarkable. Ultimately, the patient began intravenous immune globulin (IVIG) therapy. At his two-month dermatology clinic follow-up visit the patient reported marked improvement. Scaling of the patient's face resolved, though the rash was still visible on his elbows and neck. Although his work-up for malignancy has been negative to-date we will continue to monitor.



**Figure 1.** **A)** Clinical photo demonstrating multifocal erythematous plaques with violaceous papules located on the bilateral elbows, consistent with Gottron papules. **B)** Clinical photo demonstrating erythematous plaques on the patient's posterior neck of morphology consistent with the shawl sign.

## Case Discussion

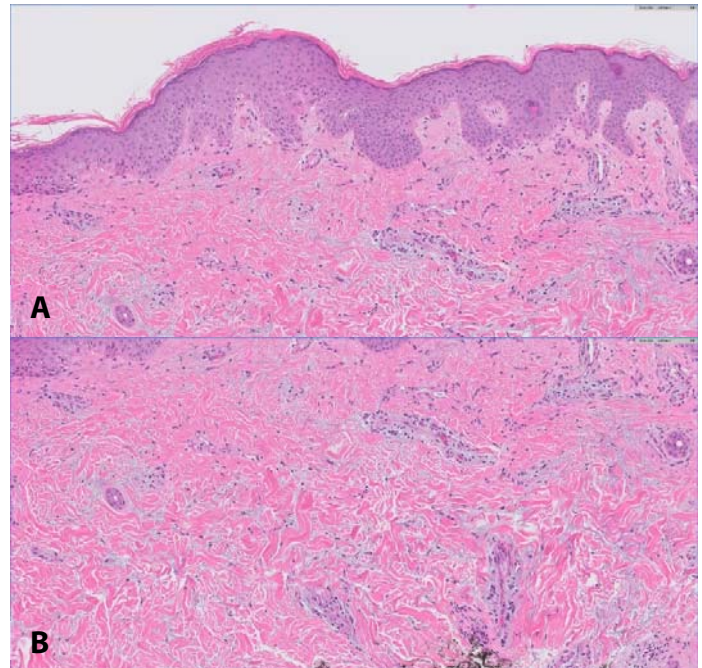
Myositis-specific antibodies have emerged as a valuable laboratory test for patients in which the clinical diagnosis of dermatomyositis is equivocal. Nuclear matrix protein-2 antibodies are believed to regulate RNA metabolism and transcription, which contributes to various nuclear functions [6]. Importantly, NXP-2 antibodies are more common in juvenile dermatomyositis [7], despite our patient representing a case of adult dermatomyositis. Although children with juvenile dermatomyositis typically lack underlying malignancy, NXP-2-positive

dermatomyositis is strongly associated with malignancy in adults [8].

A retrospective cohort analysis by Rogers et al. found that NXP-2-positive adult dermatomyositis patients often have a distinct clinical phenotype with more severe systemic involvement despite milder inflammatory skin disease. Of note, adult patients were more likely to experience myalgia, peripheral edema, and significant dysphagia, whereas patients were less likely to exhibit pathognomonic findings such as Gottron papules or the “shawl sign” [9]. Interestingly, on physical examination our patient exhibited Gottron papules on his elbows and the shawl sign on his neck. He also experienced significant myalgia and dysphagia, yet he lacked peripheral edema or underlying malignancy. Regardless, patients with NXP-2-positive adult dermatomyositis require more aggressive treatment than adult patients lacking NXP-2 seropositivity. For adult patients with NXP-2-positive dermatomyositis, age-appropriate screening and symptom-targeted malignancy screening may be insufficient in detecting underlying malignancy. Thus, patients may require full-body imaging with MRI, CT, or PET-CT [10-12].

In contrast, NXP-2-positive juvenile dermatomyositis is more often associated with calcinosis cutis [4, 13] and patients present commonly with severe myopathy [5]. Patients may develop gastrointestinal bleeding owing to vasculopathy secondary to muscle ischemia, though systemic involvement is otherwise less common [7]. Age-appropriate screening and symptom-targeted malignancy screening are typically sufficient for juvenile dermatomyositis given the decreased likelihood of underlying malignancy. Thus, knowledge of NXP-2 seropositive adult dermatomyositis versus juvenile dermatomyositis is essential in anticipating clinical sequelae and determining prognosis.

Initial management of NXP-2-positive adult dermatomyositis depends on lesion type, degree of muscle involvement, presence of systemic symptoms, and specific patient age [12]. For adult patients with non-vasculopathic cutaneous disease, sun protection, topical corticosteroids, and systemic



**Figure 2.** **A)** H&E histopathology of dermatomyositis demonstrating focal vacuolar interface dermatitis and basement membrane thickening, 200x. **B)** Histopathology of dermatomyositis showing prominent dermal mucin deposition. H&E, 200x.

therapies represent a first-line triad [12]. Systemic therapies may include corticosteroids, antimalarials, methotrexate or mycophenolate mofetil, and rituximab depending on extent of disease. Intravenous immune globulin therapy may be indicated in patients who fail conventional therapies or in whom myopathy is controlled but cutaneous disease is persistent. Emerging therapies include JAK kinase inhibitors such as tofacitinib [14].

Similarly, the initial management of juvenile dermatomyositis consists of high dose corticosteroids with either oral or intravenous methotrexate [15]. Dermatologists and rheumatologists may also consider adjuvant therapies including cyclosporine or rituximab. The Pediatric Rheumatology International Trials Organization (PRINTO) was a large, international, randomized, open-label trial which found that dual therapy with prednisone and either cyclosporine or methotrexate was more efficacious than prednisone monotherapy [16]. Additionally, the study determined the safety profile and steroid-sparing effect favored the combination of prednisone plus



methotrexate dual therapy. In general, providers should aim to mitigate corticosteroid exposure to pediatric patients [15]. Currently, there is a paucity of evidence as to which treatment regimens are most efficacious depending on myositis-specific antibody seropositivity.

## Conclusion

Dermatomyositis in an idiopathic inflammatory myopathy, which may be difficult to diagnose given its heterogeneity in clinical presentation. The use of

myositis-specific antibodies, such as NXP-2, and a thorough understanding of the relative differences between juvenile and adult dermatomyositis can be helpful in optimizing clinical evaluation and anticipating prognosis. Further research is needed to determine if individual myositis-specific antibody dermatomyositis phenotypes respond differently to certain treatment modalities.

## Potential conflicts of interest

The authors declare no conflicts of interests.

## References

- DeWane ME, Waldman R, Lu J. Dermatomyositis: Clinical features and pathogenesis. *J Am Acad Dermatol*. 2020;82:267-281. [PMID: 31279808].
- Butt Z, Patel L, Das MK, Mecoli CA, Ramji A. NXP-2 Positive Dermatomyositis: A Unique Clinical Presentation. *Case Rep Rheumatol*. 2017;4817275. [PMID: 28695037].
- Ceribelli A, Fredi M, Taraborelli M, et al. Anti-MJ/NXP-2 autoantibody specificity in a cohort of adult Italian patients with polymyositis/dermatomyositis. *Arthritis Res Ther*. 2012;14:R97. [PMID: 22546500].
- Tansley SL, Betteridge ZE, Shaddick G, et al. Calcinosis in juvenile dermatomyositis is influenced by both anti-NXP2 autoantibody status and age at disease onset. *Rheumatology (Oxford)*. 2014;53:2204-2208. [PMID: 24987158].
- Wu Q, Wedderburn LR, McCann LJ. Juvenile dermatomyositis: Latest advances. *Best Pract Res Clin Rheumatol*. 2017;31:535-557. [PMID: 29773272].
- Suzuki S, Uruha A, Suzuki N, Nishino I. Integrated Diagnosis Project for Inflammatory Myopathies: An association between autoantibodies and muscle pathology. *Autoimmun Rev*. 2017;16:693-700. [PMID: 28479486].
- Rider LG, Shah M, Mamyrova G, et al. The myositis autoantibody phenotypes of the juvenile idiopathic inflammatory myopathies. *Medicine (Baltimore)*. 2013;92:223-243. [PMID: 23877355].
- Fujimoto M, Watanabe R, Ishitsuka Y, Okiyama N. Recent advances in dermatomyositis-specific autoantibodies. *Curr Opin Rheumatol*. 2016;28:636-644. [PMID: 27533321].
- Rogers A, Chung L, Li S, Casciola-Rosen L, Fiorentino DF. Cutaneous and Systemic Findings Associated With Nuclear Matrix Protein 2 Antibodies in Adult Dermatomyositis Patients. *Arthritis Care Res (Hoboken)*. 2017;69:1909-1914. [PMID: 28129490].
- Selva-O'Callaghan A, Martinez-Gomez X, Trallero-Araguas E, Pinal-Fernandez I. The diagnostic work-up of cancer-associated myositis. *Curr Opin Rheumatol*. 2018;30:630-636. [PMID: 29965856].
- Li Y, Zhou Y, Wang Q. Multiple values of (18)F-FDG PET/CT in idiopathic inflammatory myopathy. *Clin Rheumatol*. 2017;36:2297-2305. [PMID: 28831580].
- Waldman R, DeWane ME, Lu J. Dermatomyositis: Diagnosis and treatment. *J Am Acad Dermatol*. 2020;82:283-296. [PMID: 31279813].
- Gunawardena H, Wedderburn LR, Chinoy H, et al. Autoantibodies to a 140-kd protein in juvenile dermatomyositis are associated with calcinosis. *Arthritis Rheum*. 2009;60:1807-1814. [PMID: 19479859].
- Kurtzman DJB, Wright NA, Lin J, et al. Tofacitinib Citrate for Refractory Cutaneous Dermatomyositis: An Alternative Treatment. *JAMA Dermatol*. 2016;152:944-945. [PMID: 27120749].
- Huber AM. Update on the clinical management of juvenile dermatomyositis. *Expert Rev Clin Immunol*. 2018;14:1021-1028. [PMID: 30308133].
- Ruperto N, Pistorio A, Oliveira S, et al. Prednisone versus prednisone plus ciclosporin versus prednisone plus methotrexate in new-onset juvenile dermatomyositis: a randomised trial. *Lancet (London, England)*. 2016;387:671-678. [PMID: 26645190].