

Bleeding complication following a shave biopsy in a patient taking ibrutinib

Negar Esfandiari¹ BHSc, Nathan Bombardier² MD, Joseph C Pierson^{1,2} MD

Affiliations: ¹The Larner College of Medicine, University of Vermont, Burlington, Vermont, USA, ²Division of Dermatology, University of Vermont Medical Center, Burlington, Vermont, USA

Corresponding Author: Joseph C Pierson MD, 111 Colchester Avenue, Burlington, VT 05401, Tel: 802-847-4570, Email: Joseph.Pierson@uvmhealth.org

Abstract

Ibrutinib is an oral Bruton tyrosine kinase inhibitor approved for use in patients with B-cell malignancies and has been shown to increase progression-free survival in patients with chronic lymphocytic leukemia (CLL). Ibrutinib is known to increase bleeding risk in patients with CLL. We report a patient with CLL on ibrutinib who experienced significant and prolonged bleeding after a routine superficial tangential shave biopsy for suspected squamous cell carcinoma. This prompted temporary cessation of this medication for the patient's subsequent Mohs surgery. This case demonstrates the possible severity of bleeding following routine dermatologic procedures. It is important to consider holding the medication prior to planned procedures such as dermatologic surgery.

Keywords: bleeding, carcinoma, chronic lymphocytic leukemia, ibrutinib, mohs surgery, shave biopsy, squamous cell

Introduction

Ibrutinib (Imbruvica[®], Janssen Biotech and Pharmacyclics LLC) is an oral Bruton tyrosine kinase inhibitor approved for use in patients with B-cell malignancies, including chronic lymphocytic leukemia (CLL); more than 230,000 patients have taken this medication worldwide [1,2]. In patients with CLL, ibrutinib has been shown to increase progression-free survival as compared to other chemoimmunotherapy medications [3]. A known

adverse effect of ibrutinib, however, is that it increases the bleeding risk in patients with CLL [1].

In dermatologic procedures, such as complete scalpel excisions and Mohs surgery, it is common for patients to continue their anticoagulation or antiplatelet medications, given the low risk of bleeding complications and the possible risk of thrombosis with medication cessation [4]. For these procedures, excessive bleeding is not expected, even for patients taking medications affecting hemostasis. We present a patient on ibrutinib who had prolonged bleeding after a routine superficial tangential shave biopsy, which warranted further investigation.

Case Synopsis

A 66-year-old man presented for shave biopsy of a lesion on his left post-auricular scalp concerning for squamous cell carcinoma (SCC). He had a history of facial basal cell carcinoma removed by Mohs surgery three years earlier without complications. He was recently diagnosed with CLL and had started on ibrutinib 420mg daily four days prior to undergoing a superficial tangential shave biopsy, using a Dermablade[®], of his left post-auricular scalp (**Figure 1**). The patient had no other skin examination findings, such as purpura. Same-day laboratory work revealed a platelet count of 94K/ μ L (reference range: 141-377 K/ μ L), white blood cell count of 527K/ μ L (reference range: 4.00-12.40 K/ μ L), and hematocrit of 35.7% (reference range: 34.9-44.4%). His daily medications included allopurinol 300mg,

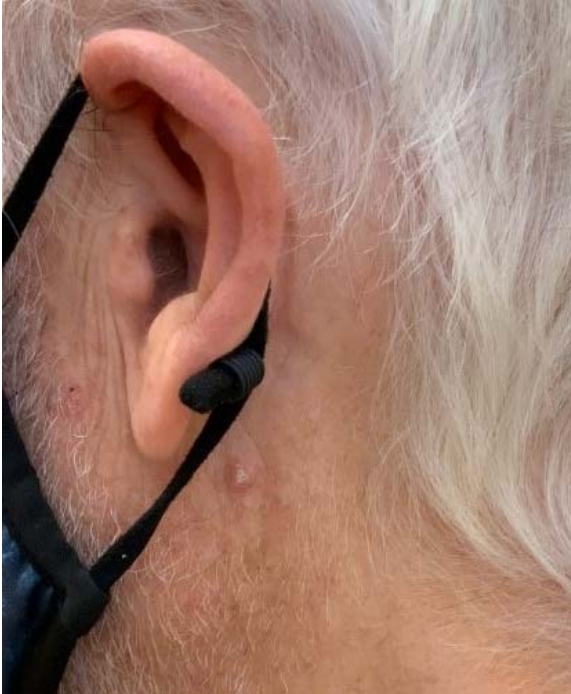

Figure 1. Squamous cell carcinoma of left post-auricular scalp, site of superficial tangential shave biopsy.

atorvastatin 10mg, fish oil 1200mg, lutein 25mg/zeaxanthin 5mg, and tramadol 50mg. The patient held his fish oil on the day of the biopsy and until two days after.

One day after the biopsy, the patient had prolonged brisk bleeding which did not respond to 15 minutes of continuous pressure. He went to a local clinic to have the biopsy site re-bandaged. On the second day after the biopsy, the patient re-started his fish oil. Three days after the biopsy, the patient had continuous bleeding despite applying pressure on the bandage and after home application of aluminum chloride. He went to the emergency department, where they applied 30 minutes of pressure and topical tranexamic acid, which failed to stop the bleeding. The bleeding was eventually controlled after application of QuikClot® with kaolin.

The biopsy confirmed well-differentiated SCC (**Figure 2**) and six weeks later the patient underwent Mohs surgery. The patient was no longer taking fish oil supplements. At the time of Mohs surgery, laboratory work demonstrated a platelet count of 105K/ μ L (reference range: 141-377 K/ μ L), WBC count of 15.31K/ μ L (reference range: 4.00-12.40 K/ μ L), and a hematocrit of 36.7% (reference range: 34.9-44.4%).

Notably, the patient held his ibrutinib for three days prior to and three days after the Mohs surgery. The incision site was closed using an intermediate linear closure and there were no bleeding complications.

Case Discussion

Ibrutinib is used in the treatment of CLL and has an adverse effect of increased bleeding risk [1]. Moreover, in patients diagnosed with CLL, the likelihood of major hemorrhage is increased as compared to healthy controls [5]. It has been proposed that bleeding while on ibrutinib is partially related to the inhibition of platelet accumulation [1]. This bleeding risk is increased for both superficial mucocutaneous bleeds, such as epistaxis, as well as major bleeding, such as gastrointestinal hemorrhage [1]. In a recent systematic review, 30.1% of patients with CLL treated with ibrutinib were reported to have bleeding events, with 2.5% having major bleeding, as compared to 10.3% and 1.1% in the control group, respectively [1]. Furthermore, treatment with ibrutinib has been associated with numerous of cutaneous dermatological findings, described extensively by Sibaud et al. [6]. Notably, there is petechia, ecchymosis, bruising, and less commonly, skin infection, rash, nail and hair changes, folliculitis, and panniculitis. The bruising and ecchymosis can appear akin to solar purpura [6,7]. Our patient did not display any ecchymosis, purpura,

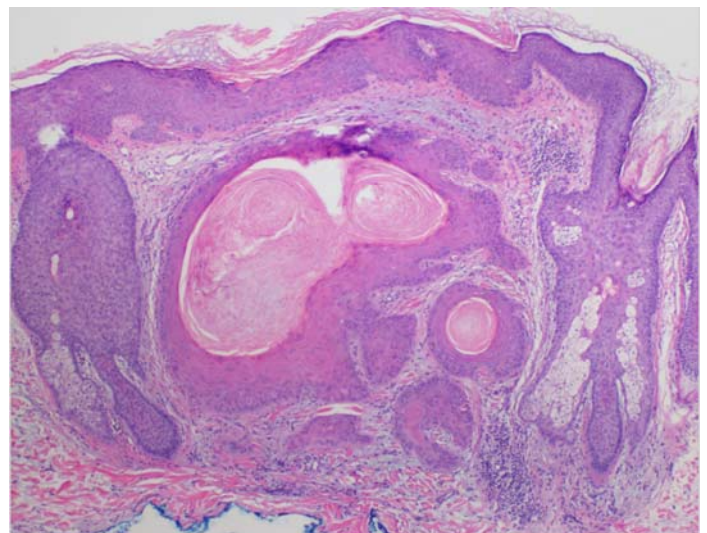


Figure 2. Histology demonstrating well-differentiated squamous cell carcinoma. H&E, 4x.

or other skin findings at the time of his biopsy; however, these additional dermatological toxicities should be considered when treating patients on ibrutinib therapy.

Our patient was on the fourth day of ibrutinib therapy when he underwent the shave biopsy and had subsequent prolonged bleeding. He was not taking antiplatelet or anticoagulation medications and had no history of bleeding complications. Two days after the biopsy, he restarted taking fish oil and continued to have bleeding. A recent meta-analysis has found that although fish oil can reduce both platelet aggregation and primary hemostasis, there is no increased intra-operative/post-operative bleeding risk as compared to patients not taking this supplement [8]. However, fish oil has been shown to increase bleeding risk when paired with certain high-risk medications like warfarin. Shatzel et al. recommend against taking fish oil while on ibrutinib [9].

Shatzel et al. and Parmar et al. propose holding ibrutinib for 3-7 days prior to and up to 3-7 days after elective surgical procedures [9,10]. Parra et al. described two patients on ibrutinib therapy who had post-operative bleeding complications after Mohs surgery to remove facial SCC [11]. The platelet counts were in the normal range for both patients at the time of surgery. A patient with Waldenstrom macroglobulinemia had held his ibrutinib for three days prior to the procedure and until post-operative day 10, whereas a patient with CLL continued his therapy throughout; both post-operative courses were complicated by severe ecchymoses [11]. A shave biopsy is a much less invasive procedure than Mohs surgery, yet our patient experienced

significant three-day bleeding. After consultation with the patient's hematologist, the patient held his ibrutinib for three days prior to, and three days after undergoing Mohs surgery to remove his newly diagnosed SCC and had no bleeding complications.

Conclusion

This case demonstrates severe bleeding after a shave biopsy in a patient on ibrutinib. There were many changing variables before the patient's shave biopsy occurred, with the prolonged bleeding, and the Mohs surgery, after which there were no bleeding complications. First, the patient had rapid improvement of his blood counts with ibrutinib therapy—notably a thirty-four-fold decrease in his white blood cell count. A diagnosis of CLL alone increases bleeding risk; that, combined with the known adverse effect of increased bleeding risk while taking ibrutinib likely contributed to the prolonged bleeding after his shave biopsy. Furthermore, the patient held his ibrutinib for three days prior to, and after his Mohs surgery, whereas he did not hold the ibrutinib for the shave biopsy. The patient also decided to stop taking fish oil after experiencing the significant bleeding with the original biopsy and was no longer on fish oil when he had his Mohs surgery. This case demonstrates the importance of considering holding ibrutinib for skin biopsies, as well as surgical procedures such as complete scalpel excisions and Mohs surgery.

Potential conflicts of interest

The authors declare no conflicts of interest.

References

1. Wang J, Zhao A, Zhou H, Zhu J, Niu T. Risk of Bleeding Associated With Ibrutinib in Patients With B-Cell Malignancies: A Systematic Review and Meta-Analysis of Randomized Controlled Trials. *Front Pharmacol.* 2020;11:580622 [PMID: 33658926].
2. New Phase three Study Results Show IMBRUVICA® (ibrutinib)-Based Combination Regimen as an All-Oral Fixed-Duration Treatment Demonstrated Superior Progression-Free Survival in Adult Patients with Previously Untreated Chronic Lymphocytic Leukemia. Johnson&Johnson. 2021. [https://www.jnj.com/new-phase-3-study-results-show-imbruvica-ibrutinib-based-combination-regimen-as-an-all-oral-fixed-duration-treatment-](https://www.jnj.com/new-phase-3-study-results-show-imbruvica-ibrutinib-based-combination-regimen-as-an-all-oral-fixed-duration-treatment-demonstrated-superior-progression-free-survival-in-adult-patients-with-previously-untreated-chronic-lymphocytic-leukemia)
3. Burger J, Barr P, Robak T, et al. Long-term efficacy and safety of first-line ibrutinib treatment for patients with CLL/SLL: 5 years of follow-up from the phase three RESONATE-2 study. *Leukemia.* 2019;34:787-798. [PMID: 31628428].
4. Alcalay J, Alcalay R. Controversies in Perioperative Management of Blood Thinners in Dermatologic Surgery: Continue or Discontinue? *Dermatol Surg.* 2004;30:1091-1094. [PMID: 15274698].

5. Georgantopoulos P, Yang H, Norris L, Bennett C. Major hemorrhage in chronic lymphocytic leukemia patients in the US Veterans Health Administration system in the pre-ibrutinib era: Incidence and risk factors. *Cancer Med.* 2019;8:2233-2240. [PMID: 30983123].
6. Sibaud, V., Beylot-Barry, M., Protin, C. et al. Dermatological Toxicities of Bruton's Tyrosine Kinase Inhibitors. *Am J Clin Dermatol.* 2020;21:799-812. [PMID: 32613545].
7. Schmidt NJ, Isaac K, Williams ME, et al. Novel Hemorrhagic Dermatologic Toxicity Associated with Bruton's Tyrosine Kinase Inhibitor Therapy. *Blood* 2021;138 (Supplement 1):4528. [DOI: 10.1182/blood-2021-146587].
8. Munk Begtrup K, Engel Krag A, Hvas A. No impact of fish oil supplements on bleeding risk: a systematic review. *Dan Med J.* 2017;64:A5366. [PMID: 28552094].
9. Shatzel J, Olson S, Tao D, et al. Ibrutinib-associated bleeding: pathogenesis, management and risk reduction strategies. *J Thromb Haemost.* 2017;15:835-847. [PMID: 28182323].
10. Parmar S, Patel K, Pinilla-Ibarz J. Ibrutinib (Imbruvica): A Novel Targeted Therapy for Chronic Lymphocytic Leukemia. *Pharm Ther.* 2014;39:483-519. [PMID: 25083126].
11. Parra C, Newsom E, Lee E, Allan J, Minkis K. Association of Ibrutinib Treatment With Bleeding Complications in Cutaneous Surgery. *JAMA Dermatol.* 2017;153:1069-1070. [PMID: 28700792].