

# Apparent darkening of scalp hair related to pili multigemini following dabrafenib and trametinib

Christina Avila<sup>1</sup> BS MPH, Kalyn Hoffman<sup>1</sup> BS, Nima Milani-Nejad<sup>2</sup> MD PhD, Llana Pootrakul<sup>2</sup> MD PhD

Affiliations: <sup>1</sup>The Ohio State University College of Medicine, Columbus, Ohio, USA, <sup>2</sup>Division of Dermatology, The Ohio State University Department of Internal Medicine, Columbus, Ohio, USA

Corresponding Author: Llana Pootrakul, M.D., Ph.D., Division of Dermatology Department of Internal Medicine, 540 Offcenter Place, Suite 240, Columbus, OH 43230, Tel: 614-293-1707, Email: [llana.pootrakul@osumc.edu](mailto:llana.pootrakul@osumc.edu)

## Abstract

The combination of dabrafenib and trametinib is an important immunotherapy option for patients with *BRAF* V600 mutation-positive melanoma. This regimen has been reported to cause cutaneous eruptions. However, hair dysmorphology is not a reported side effect to these or any other medications to date. Herein, we highlight a case of pili multigemini formation in a patient with stage IV melanoma receiving treatment with dabrafenib and trametinib and the corresponding clinical findings.

*Keywords: melanoma, chemotherapy, dabrafenib, trametinib, pili multigemini, hair disorders*

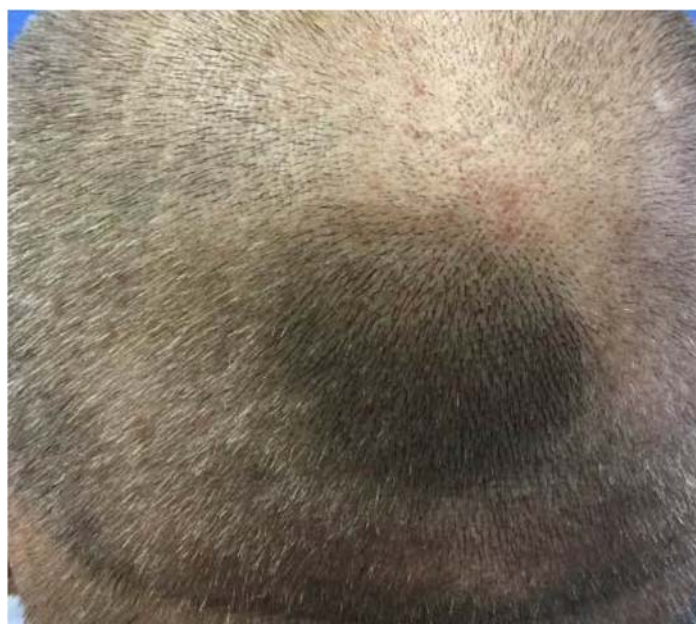## Introduction

A wide variety of dermatologic adverse effects are known complications of immunotherapy. We report a novel case of the onset of pili multigemini following systemic treatment with dabrafenib and trametinib in a patient with stage IV melanoma.

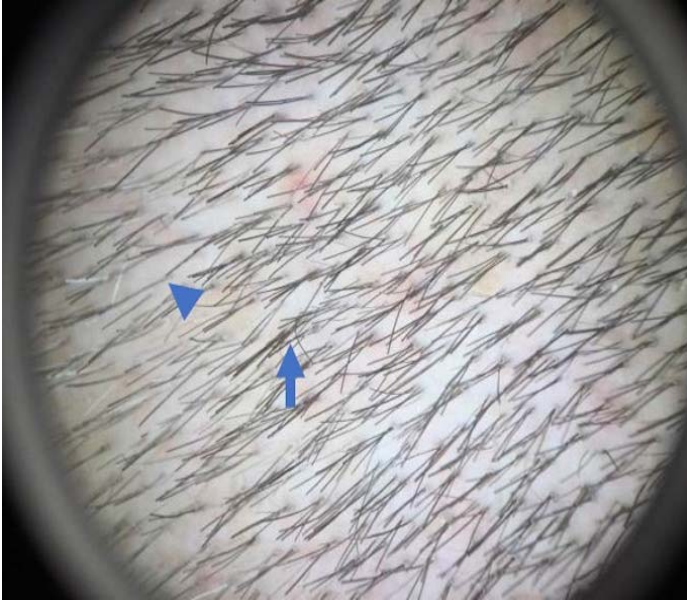
## Case Synopsis

A 52-year-old man with a history of stage IV metastatic melanoma presented to the dermatology clinic for a routine full-body examination. He had diffuse metastatic disease with abdominal carcinomatosis, pulmonary nodules, and leptomeningeal and central nervous system involvement and was on a systemic chemotherapy regimen of dabrafenib and trametinib. While on

immunotherapy the patient experienced a transient alopecia which self-resolved and upon regrowth of the hair he noticed a dark patch of hair on the occipital scalp. The patient denied any hair or scalp discoloration issues prior to the start of the regimen. On physical examination, there was a 45×35mm well-circumscribed area on the posterior scalp (**Figure 1**). Dermoscopy showed multiple hair shafts derived from the same follicular units resulting in an apparent darkening of the hair and scalp related to increased hair density with no darkening or hyperpigmentation of the scalp itself (**Figure 2**). The patient reported no issues with this irregular hair growth and was continued on his regimen without alteration.



**Figure 1.** Gross appearance of a well-circumscribed area on the occipital scalp with new multigeminate hair formation.



**Figure 2.** Dermoscopy showing multiple hair shafts emerging from single follicular units. The arrow indicates an example of pili multigemini and an arrowhead to show uninvolved hair follicles.

## Case Discussion

Pili multigemini is a hair malformation characterized by the presence of multiple hair shafts with distinct cuticles originating from a single pilosebaceous canal. The multigeminate hairs, enclosed by a common bulb, emerge from a single follicular ostium [1]. It is often a finding in male beards, but has been reported in women, children, and in all body hair types [2]. In general, pili multigemini is a benign asymptomatic condition that does not require removal. Some patients elect for removal owing to cosmetic concerns, with electrolysis being the most common method; there have been reports of depilating laser treatment for symptomatic cases [3]. Other hair shaft abnormalities with multiple hairs emerging from a single follicle include tufted hair folliculitis, that often follows scarring alopecia, and compound follicles, which can be a normal finding [4].

Combination immunotherapy with dabrafenib, a BRAF inhibitor, and trametinib, a MEK inhibitor, is a current treatment for *BRAF* V600 mutation-positive melanoma and significantly improves survival in metastatic disease [5]. Adverse events associated

with the dabrafenib and trametinib combination include pyrexia, chills, fatigue, rash, and nausea. Cutaneous adverse events during treatment is well established [5]. In a multivariate analysis of randomized clinical trials with dabrafenib and trametinib, the most common side effects were cutaneous changes. Cutaneous eruption was the most common, with hyperkeratosis, photosensitivity, hair growth modification, alopecia, cutaneous squamous cell carcinoma, and new primary melanoma also reported [6]. Alopecia is a known side effect of this combination therapy. However, hair shaft dysplasia has not been reported. Focal hair pigmentation has been reported following immunotherapy, most commonly anti-programmed cell death 1 and anti-programmed cell death ligand 1 agents [7]. Although the exact mechanism is unknown, the etiology is likely multifactorial, with possible genetic linkage or the reactivation of silent embryonic epithelial germ cells producing the dysplastic follicle [1]. *BRAF* is a proto-oncogene that regulates the MAP kinase/ERK signaling pathways. This pathway is integral to cell division and differentiation. Our patient's acquired pili multigemini may support the hypothesis that these dysplastic follicles develop after reactivation of germ cell genes. Until now, pili multigemini has neither been reported as a possible side effect of the combination of dabrafenib and trametinib nor other systemic cancer therapies.

## Conclusion

Although there are no known adverse effects associated with pili multigemini, aside from cosmetic considerations, it is important to recognize that it may be caused by a common combination immunotherapy regimen for melanoma to avoid potential patient harm and unnecessary workup.

## Potential conflicts of interest

The authors declare no conflicts of interests

## References

1. Ciudad-Blanco C, Montero EC, Heffernan JAJ, Ochaita PL. Extensive pili multigemini over the back. *Int. J. Trichology*. 2014;6:180-181. [PMID: 25368477].
2. Lester L, Vendetti C. The prevalence of pili multigemini. *Br J Dermatol*. 2007;156:1362-1363. [PMID: 17441959].
3. Panchaprateep R, Tanus A, Tosti A. Clinical, dermoscopic, and histopathologic features of body hair disorders. *J Am Acad Dermatol*. 2015;72:890-900. [PMID: 25748313].
4. Miteva M, Tosti A. Hair and scalp dermatoscopy. *J Am Acad Dermatol*. 2012;67:1040-1048. [PMID: 22405573].
5. Long GV, Stroyakovskiy D, Gogas H, et al. Dabrafenib and trametinib versus dabrafenib and placebo for Val600 BRAF-mutant melanoma: A multicentre, double-blind, phase 3 randomised controlled trial. *Lancet*. 2015;386:444-451. [PMID: 26037941].
6. Welsh SJ, Corrie PG. Management of BRAF and MEK inhibitor toxicities in patients with metastatic melanoma. *Ther Adv Med Oncol*. 2015;7:122-136. [PMID: 25755684].
7. Rivera N, Boada A, Biesla MI, et al. Hair repigmentation during immunotherapy treatment with an anti-programmed cell death 1 and anti-programmed cell death ligand 1 agent for lung cancer. *JAMA Dermatol*. 2017;153:1162-1165. [PMID: 28700789].