

Case presentation

Treatment of refractory pyoderma gangrenosum with infliximab in a 17-month-old boy

Susan A Bobbitt MD FRCPC¹, Ernst M Klaus MBChB MMed Int. Med FRCPC², Elizabeth Stringer MD FRCPC², Dhiman Chowdhury MBBS FRCP (Edin) FRCPCH FRCPC FAAP², Laura Finlayson MD FRCPC FACP²

Dermatology Online Journal 22 (4): 9

¹Glenrose Rehabilitation Hospital, University of Alberta

²IWK Health Centre, Dalhousie University

Correspondence:

Elizabeth Stringer MD, FRCPC
Division of Pediatric Rheumatology
IWK Health Centre
5850/5980 University Avenue
PO Box 9700
Halifax, NS, B3K 6R8
Email: Elizabeth.Stringer@iwk.nshealth.ca
Telephone: (902) 470-8827
Fax: (902) 470-7217

Abstract

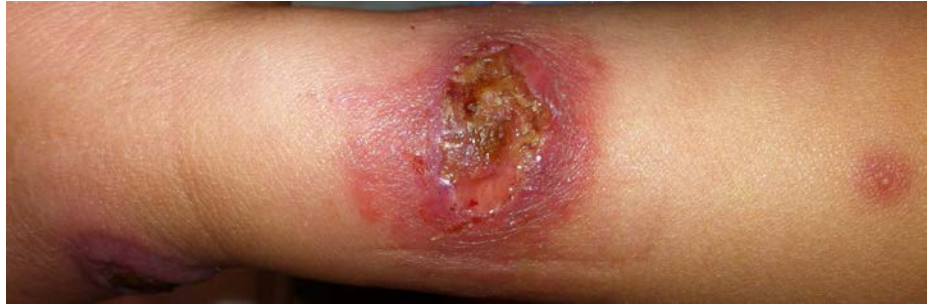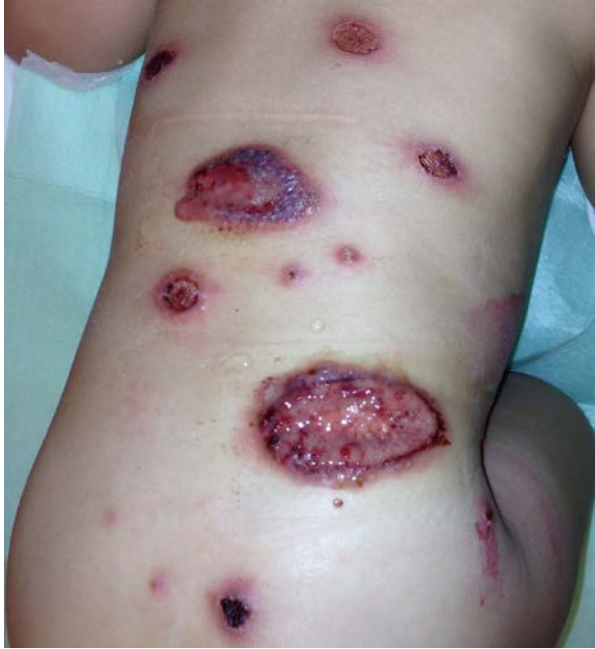This report details the case of a 17-month old boy with refractory multifocal pyoderma gangrenosum responsive to anti-TNF therapy.

Keywords: Pyoderma gangrenosum; neutrophilic dermatoses; infliximab; child

Case synopsis

A 17-month old boy was transferred to our pediatric institution for evaluation of painful widespread cutaneous ulcers. He presented initially to his local hospital with a single pustule on his buttock, which evolved into a necrotic ulcer measuring 3 cm in diameter. The patient was otherwise well and had no constitutional symptoms. The review of systems was negative. The patient was born at term after an uncomplicated pregnancy. Congenital pulmonary stenosis was noted at birth and corrected with balloon valvuloplasty at 6 months of age. He was otherwise thriving and developing normally. There were no symptoms of inflammatory bowel disease. In the two weeks prior to admission to our hospital, further ulcers developed on his torso, extremities, face, and scalp. Upon admission he was irritable and appeared uncomfortable. Vital signs, including a temperature of 36.5 C, were normal. On examination, the patient had approximately 20 intensely inflammatory violaceous plaques with large central bullae and pustules in various stages of breakdown to full thickness ulcers. The ulcers had undermined borders and evidence of cribriform changes, small irregular and deeper punched out areas of ulceration (Figure 1, Figure 2). The ulcers varied in size from 1-6 cm in diameter. Laboratory investigations demonstrated a hemoglobin of 112 g/L (normal 105-135 g/L), white blood cell count of $15.1 \times 10^9/L$ (normal $6.0-15.0 \times 10^9$) with 67% neutrophils (normal 19-36%) and 3% bands (normal 1-8%) and a platelet count of 315×10^9 (normal $150-400 \times 10^9$). Erythrocyte sedimentation rate (ESR) was elevated at 48 mm/hr (normal 0-9 mm/hr) as was C-

reactive protein (CRP) at 32.9 mg/L (normal 0-5.0 mg/L). Histopathological examination of a lesion demonstrated an inflammatory infiltrate composed of numerous neutrophils, eosinophils, and occasional multi-nucleated giant cells within the dermis with overlying spongiosis of the epidermis, most in keeping with the diagnosis of pyoderma gangrenosum (PG) (Figure 3, Figure 4). Given the broad differential diagnosis for the child's presentation, multiple subspecialties were consulted.



Figures 1 and 2.

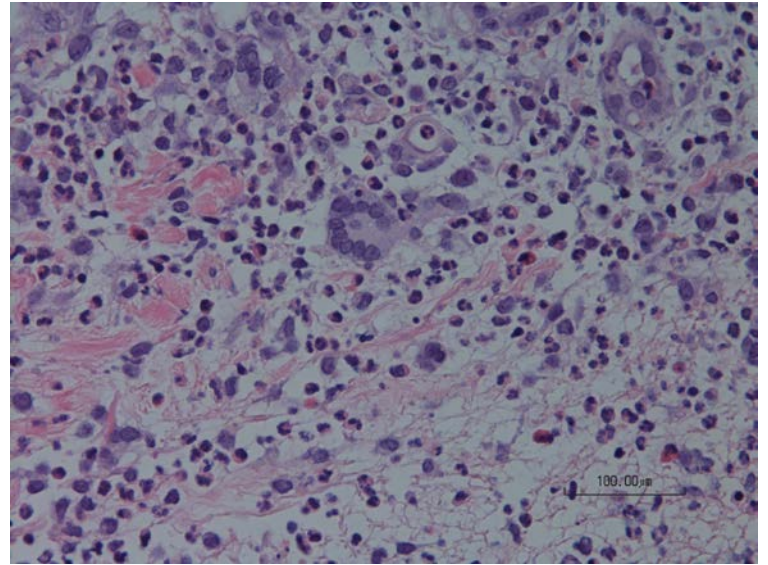
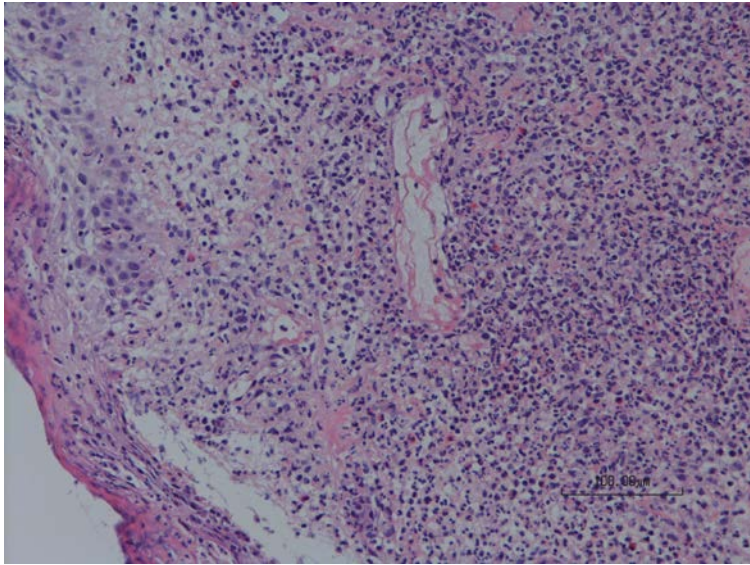


Figure 3. H&E stain (200x) of punch biopsy of buttock lesion demonstrating spongiosis of the epidermis with overlying parakeratosis. An intense inflammatory infiltrate is within the dermis composed of neutrophils, eosinophils and occasional multinucleated giant cells. **Figure 4.** H&E stain (400x) of punch biopsy of buttock lesion demonstrating a multinucleated giant cell (center of image) surrounded by infiltrate of neutrophils and eosinophils within the dermis

Within 48 hours the patient became febrile (temperature 40 C) with an associated elevation in CRP to 252 mg/L, ESR 75 mm/hr, WBC 17.7×10^9 (44% neutrophils, 19% bands), and a fall in hemoglobin to 88 g/L. He continued to develop new lesions (numbering 44 at the highest). The existing ulcers became larger, deeper, and excruciatingly painful. Broad spectrum antibiotics were initiated owing to the concern of systemic infection on day 3 of admission and were continued empirically for 2 weeks, although blood cultures and cultures of swabs from multiple lesions were negative. On day 4 of admission the patient was started on daily pulse intravenous methylprednisolone (IVMP) (30mg/kg), which was continued for a total of 3 days followed by a daily dose of oral prednisone (2mg/kg/day). Fever resolved after 3 days of pulse IVMP and did not recur. Initially his skin lesions regressed and there was a dramatic improvement in his inflammatory markers (CRP decreased to 0 mg/L, ESR 22 mm/hr), but after three days of oral treatment he had a relapse with new lesions forming and rebound of inflammatory markers. Oral cyclosporine 3mg/kg/day was initiated and subsequently increased to 6mg/kg/day, but owing to further lesion progression and

CRP continuing to rising to 142.9 mg/L, a second 3-day course of pulse IVMP was given. Thereafter, infliximab (10mg/kg) was added to the cyclosporine and prednisone. A rapid improvement was noted after the first infusion and subsequent doses were given at 2, 4, and 6 weeks followed by monthly infusions. Inflammatory markers also improved dramatically (CRP 6.2 mg/L). Cyclosporine levels were difficult to keep in the therapeutic range, and owing to potential renal toxicity, cyclosporine was replaced with 10 mg of weekly oral methotrexate. The skin continued to heal with scarring and remained essentially quiescent while prednisone was cautiously tapered over 8 months (Figure 5). CRP and ESR were noted to be variably elevated in follow-up (CRP 3.8 mg/L to 94 mg/L; ESR 20 – 95 mm/hr). Monthly intravenous immunoglobulin (IVIG) (2g/kg) was added to his therapy 5 months into the disease course. Inflammatory markers largely improved following addition of IVIG with CRP normalizing (< 5 mg/L) and median ESR of 20 mm/hr (range <1 to 89 mm/hr) over the follow-up period. Elevations in inflammatory markers have not been associated with any symptoms or abnormalities on examination. At the time of this report (approximately 26 months of follow-up), the patient has had no significant flares of his skin disease and is growing and developing well. Infliximab and IVIG have been spaced out to every 6 weeks, and he continues on 10mg of oral methotrexate weekly.

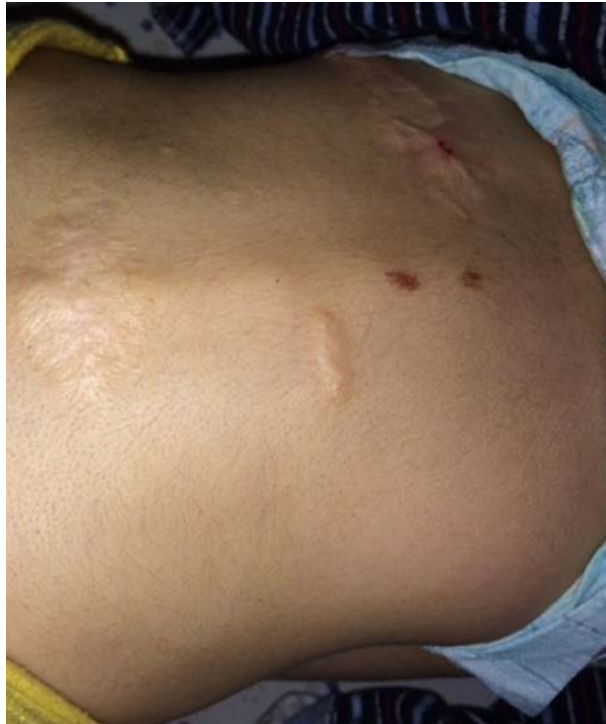

Figure 5.

Investigations: The PG lesions in this case appear to be idiopathic in nature. Mantoux test, HIV, Hepatitis B and C, acute CMV and EBV, syphilis, and HSV serologies were all negative. Anti-nuclear antibody, extractable nuclear antigen antibodies, rheumatoid factor, and anti-neutrophil cytoplasmic antibodies were negative. Angiotensin-converting enzyme level was within the normal range. In pursuing an underlying immunodeficiency, we found normal values when measuring serum immunoglobulins, C3, C4, specific vaccine responsiveness, and nitroblue tetrazolium test (to rule out chronic granulomatous disease). CD18 expression on neutrophils and lymphocytes was normal as was the ability of neutrophils to upregulate CD18 in response to bacterial peptide, making a leukocyte adhesion deficiency very unlikely. There was no evidence of a JAK-2 mutation and genetic microarray was normal. No definitive disease-associated mutations were identified in analysis of genes related to 7 autoinflammatory syndromes These included cyclic neutropenia, Majeed syndrome, familial Mediterranean fever syndrome, hyper IgD syndrome, cryopyrin-associated diseases, PAPA syndrome (pyogenic sterile arthritis, pyoderma gangrenosum, and acne), and TNF-receptor-associated periodic syndrome. Bone marrow biopsy showed normocellular, trilinear hematopoiesis, left-shifted granulopoiesis, and no morphological evidence of malignancy. Chest X-ray revealed a small lucency within the left proximal humeral metaphysis, raising the possibility of an occult osteomyelitis. Nuclear bone scan showed nonspecific abnormalities in the left clavicle and distal right femoral epiphysis, but not in the left proximal humerus. Full body MRI showed two tiny foci of limited bone marrow edema in the medial left clavicle and the proximal left humerus. Bone biopsy was not obtained as the humeral lesion was too close to the epiphysis and the lesions overall were very small in size. Follow-up X-rays of the left clavicle and humerus eight months after presentation were normal.

Discussion

Pyoderma gangrenosum is a rare neutrophilic dermatosis with an estimated incidence of 3 to 10 cases per million population per year [1]. PG is even less common in the pediatric population. In a large case series only 4% were younger than 15 years and it is even less common for PG to present in very young children [2, 3]. Typical lesions are solitary, but multiple lesions can be seen in children involving the lower extremities, buttocks, perineum, and head and neck regions [2]. Our patient had two uncommon features: a very early age of onset and a rapid progression to multiple ulcers prior to initiation of treatment.

There are at present no universally accepted or validated clinical diagnostic criteria for PG and it remains a diagnosis of exclusion. Five major subtypes of PG are recognized and include an ulcerative form (most common) in addition to bullous, vegetative, pustular, and peristomal forms [4]. Useful features in the history include: a painful pustule, papule or vesicle (with pain seemingly out of proportion to the lesion), rapid expansion of the lesion and erosion of surrounding skin resulting in an irregular, raised, and undermined purple border, and an ulcer bed consisting of a hemorrhagic or purulent centre often with a necrotic eschar. Pathergy and the formation of a thin atrophic cribiform (“sieve-like”) scar are other important clues to the diagnosis [3]. Despite concerns about the development of pathergy secondary to a skin biopsy, tissue examination is often necessary to establish a diagnosis and to exclude mimics, such as infection or other inflammatory conditions. A deep elliptical incisional biopsy, including a portion of the lesion, is advised over a punch biopsy [4].

Patients with PG can be systemically unwell with associated fever, as was the case in our patient. The aim of diagnostic testing is to exclude conditions with similar presentation as well as to evaluate for associated diseases. At least 50% of PG cases are associated with underlying conditions including inflammatory bowel disease, arthritis, infection, immunodeficiency, vasculitis, hematological malignancy, and autoinflammatory disease [4]. Associated diseases usually precede the diagnosis of PG. However, sometimes PG can be the presenting feature such as with paraneoplastic phenomena. Of the subtypes of PG described, the bullous variant has a stronger association with hematological malignancies such as acute myeloid leukemia, hence we involved the oncology service in our patient’s evaluation [5]. Extra-cutaneous PG has also been reported in the literature and may present as scleritis, aseptic pulmonary nodules, splenic lesions, sterile pyoarthrosis, neutrophilic myositis, or osteomyelitis [3,6]. Indeed, our patient had evidence of asymptomatic bone involvement on imaging, which resolved with treatment.

No gold standard for treatment of PG exists, but the goals of management should include control of inflammation, pain and wound management, and avoidance of unnecessary trauma. Corticosteroids are often employed as a first line agent either orally or intravenously for more severe disease [4]. In keeping with this, in a recent survey of dermatologists with expertise in wound care, 100% reported the frequent use of systemic steroids in the treatment of PG patients [7]. Our patient showed a rapid response to pulse IVMP, but this was not sustained on 2 mg/kg of oral prednisone. Our patient did not appear to respond to cyclosporine as a steroid-sparing agent either. Cyclosporine is often considered for the treatment of PG with three quarters of dermatologists in the aforementioned survey indicating they would commonly use this agent. There are numerous reports of other immunomodulating agents for the treatment for PG including methotrexate, azathioprine, mycophenolate mofetil, and cyclophosphamide [4].

Infliximab, a chimeric human-murine monoclonal antibody directed against tumour necrosis factor (TNF)- α , was considered as a third therapeutic option for our patient given the severe and refractory nature of his disease. A placebo-controlled trial of infliximab in adults demonstrated a good clinical response in PG at two weeks in those receiving the drug [8] and there have been a number of subsequent reports of using infliximab as well as other anti-TNF- α agents such as adalimumab and certolizumab [9,10,11,12,13]. Similar to our case, Campos-Munoz et al. also reported successful treatment of idiopathic PG with infliximab in an 11-month-old infant whose disease was refractory to oral prednisone and cyclosporine [14]. Although our patient’s cutaneous disease was well controlled with infliximab, his inflammatory markers remained intermittently elevated, suggesting persistent immune activation. There have been several reports of using IVIG to treat PG, particularly refractory PG [15]. We therefore chose to add IVIG to his therapy and this appears to have correlated with a sustained decline in his inflammatory markers, particularly the CRP. It is unclear what effect the IVIG has had on his cutaneous disease as our patient’s PG was in remission when IVIG was initiated.

Conclusion

Multifocal PG occurs rarely in children, particularly in very young children. Our case highlights a thorough investigative approach to the evaluation of PG in a young child involving multiple subspecialties consultants. We aggressively searched for conditions known to be associated with PG including infection, malignancy, autoinflammatory syndromes, and immunodeficiency. Our patient appears to have idiopathic multifocal PG. Infliximab was effective in controlling our patient’s severe and refractory disease and adds to the limited literature of PG presenting in a very young child.

References

1. Ruocco E, Sangiuliano S, Gravina AG, Miranda A, Nicoletti G. Pyoderma gangrenosum: an updated review. *J Eur Acad Dermatol Venereol.* Sep 2009;23(9):1008-1017. [PMID:19470075]
2. Powell FC, Perry HO. Pyoderma gangrenosum in childhood. *Arch Dermatol.* Jun 1984;120(6):757-761.[PMID:6721542]
3. Graham JA, Hansen KK, Rabinowitz LG, Esterly NB. Pyoderma gangrenosum in infants and children. *Pediatr Dermatol.* Mar 1994;11(1):10-17.[PMID:8170841]
4. Ahronowitz I, Harp J, Shinkai K. Etiology and management of pyoderma gangrenosum: a comprehensive review. *Am J Clin Dermatol.* Jun 1 2012;13(3):191-211.[PMID:22356259]
5. Fox LP, Geyer AS, Husain S, Grossman ME. Bullous pyoderma gangrenosum as the presenting sign of fatal acute myelogenous leukemia. *Leuk Lymphoma.* Jan 2006;47(1):147-150.[PMID:16321840]
6. East-Innis A, Desnoes R, Thame K, Shirley S, Gilbert D. Pyoderma gangrenosum associated with osteomyelitis in a paediatric patient: a case report. *West Indian Med J.* Jun 2005;54(3):207-209.[PMID:16209228]
7. Al Ghazal P, Dissemond J. Therapy of pyoderma gangrenosum in Germany: results of a survey among wound experts. *J Dtsch Dermatol Ges.* Apr 2015;13(4):317-324.[PMID:25761564]
8. Brooklyn TN, Dunnill MG, Shetty A, et al. Infliximab for the treatment of pyoderma gangrenosum: a randomised, double blind, placebo controlled trial. *Gut.* Apr 2006;55(4):505-509.[PMID:16188920]
9. Mooij JE, van Rappard DC, Mekkes JR. Six patients with pyoderma gangrenosum successfully treated with infliximab. *Int J Dermatol.* Nov 2013;52(11):1418-1420.[PMID:22512250]
10. Chan JL, Graves MS, Cockerell CJ, Pandya AG. Rapid improvement of pyoderma gangrenosum after treatment with infliximab. *J Drugs Dermatol.* Jun 2010;9(6):702-704.[PMID:20645536]
11. Rajan N, Das S, Taylor A, Abinun M, Spencer D, Carmichael A. Idiopathic infantile pyoderma gangrenosum with stridor responsive to infliximab. *Pediatr Dermatol.* Jan-Feb 2009;26(1):65-69.[PMID:19250410]
12. Pomerantz RG, Husni ME, Mody E, Qureshi AA. Adalimumab for treatment of pyoderma gangrenosum. *Br J Dermatol.* Dec 2007;157(6):1274-1275.[PMID:17916198]
13. Cinotti E, Labeille B, Perrot JL, Pallot-Prades B, Cambazard F. Certolizumab for the treatment of refractory disseminated pyoderma gangrenosum associated with rheumatoid arthritis. *Clin Exp Dermatol.* Aug 2014;39(6):750-751.[PMID:24984791]
14. Campos-Munoz L, Conde-Taboada A, Aleo E, Toledano E, Lopez-Bran E. Refractory pyoderma gangrenosum treated with infliximab in an infant. *Clin Exp Dermatol.* Apr 2014;39(3):336-339.[PMID:24635074]
15. Cafardi J, Sami N. Intravenous immunoglobulin as salvage therapy in refractory pyoderma gangrenosum: report of a case and review of the literature. *Case Rep Dermatol.* Sep 2014;6(3):239-244.[PMID:25493078]