

**Case Presentation**

**Pigmented hidrocystoma of nasal epithelium (PHONE): report of a man with a pigmented hidrocystoma of his nose and literature review**

**Katherine C Rappazzo BA<sup>1</sup>, Philip R Cohen MD<sup>2</sup>**

**Dermatology Online Journal 22 (5): 8**

**<sup>1</sup>University of California San Diego Medical School**

**<sup>2</sup>Department of Dermatology, University of California San Diego, San Diego, CA**

**Correspondence:**

Philip R. Cohen, MD  
10991 Twinleaf Court  
San Diego, CA 92131  
Email: mitehead@gmail.com

---

**Abstract**

**Background:** Hidrocystomas are benign tumors of apocrine or eccrine epithelium. They most commonly occur on the head and neck, especially periorbitally. Albeit rare, these adnexal tumors may present as pigmented lesions.

**Purpose:** To describe a patient with a pigmented eccrine hidrocystoma of his nose and to review the features of other individuals with pigmented hidrocystoma of the nasal epithelium.

**Material and Methods:** PubMed was used to search the follow terms: hidrocystoma and pigmented. All papers were reviewed and relevant manuscripts, along with their reference citations were evaluated.

**Results:** A 52-year-old man who presented with a pigmented eccrine hidrocystoma on his nasal bridge was described. The features of three previously described patients with pigmented hidrocystoma of the nose were evaluated. The tumors presented as single or multiple, less than 2mm, blue papules. Our patient's tumor would intermittently bleed, which prompted consideration of a possible basal cell carcinoma. Biopsy established the diagnosis showing a cystic lesion lined by eccrine epithelium with pigmented secretion within the cyst's lumen. The cyst content stained positive with Fontana-Masson stain. Our patient's excisional biopsy resulted in excellent cosmetic appearance and complete removal of the benign adnexal tumor.

**Conclusion:** Pigmented hidrocystomas may be mistaken for other skin lesions, such as a pigmented basal cell carcinoma and melanoma. A biopsy readily establishes the diagnosis. We respectfully suggest that a hidrocystoma located on the nose that is pigmented be referred to as a PHONE: pigmented hidrocystoma of the nasal epithelium.

**Key words:** apocrine, eccrine, hidrocystoma, multiple, nasal, nose, pigmented, solitary

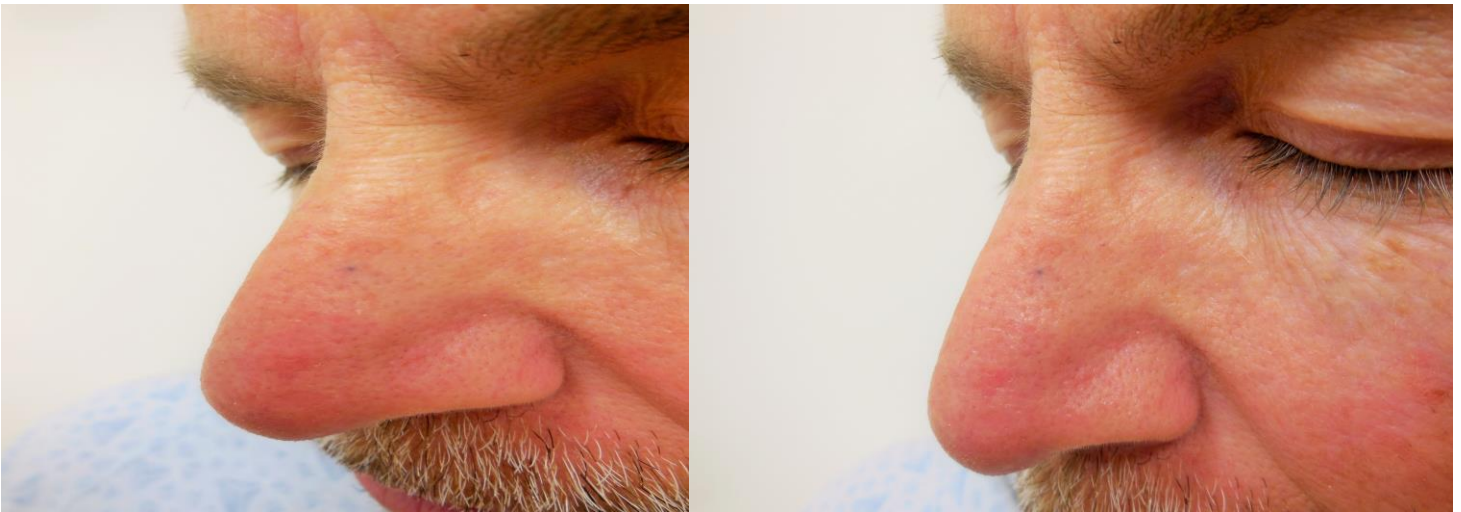# Introduction

Hidrocystomas are benign adnexal tumors. They can present as solitary or multiple lesions. Although they are usually flesh colored, they can occasionally be pigmented. We describe a man with a pigmented hidrocystoma of his nose and review the literature.

## Case synopsis

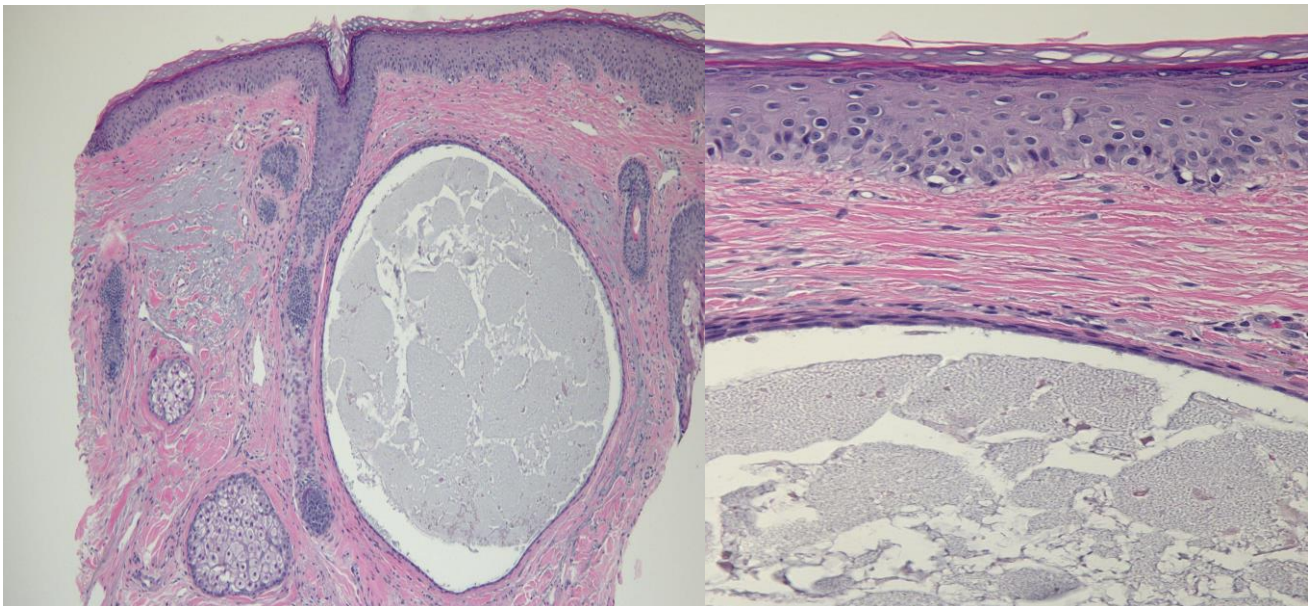
A 52-year-old man presented for evaluation of a new, intermittently bleeding, dark lesion on the left side of his nose. The lesion had been present for 1 year. It did not itch and it was not painful.

He had been diagnosed with diffuse large B-cell lymphoma 2 years earlier for which he was successfully treated with a stem cell transplant. His past medical history was also significant for pulmonary embolism, bilateral cataracts, and hypothyroidism. He had no prior history of skin cancer. Cutaneous examination of his nose revealed a less than 1mm blue macule on the left upper nasal bridge (Figure 1). There were no similar lesions located on face or body. An excisional biopsy using a 2 mm punch was performed.



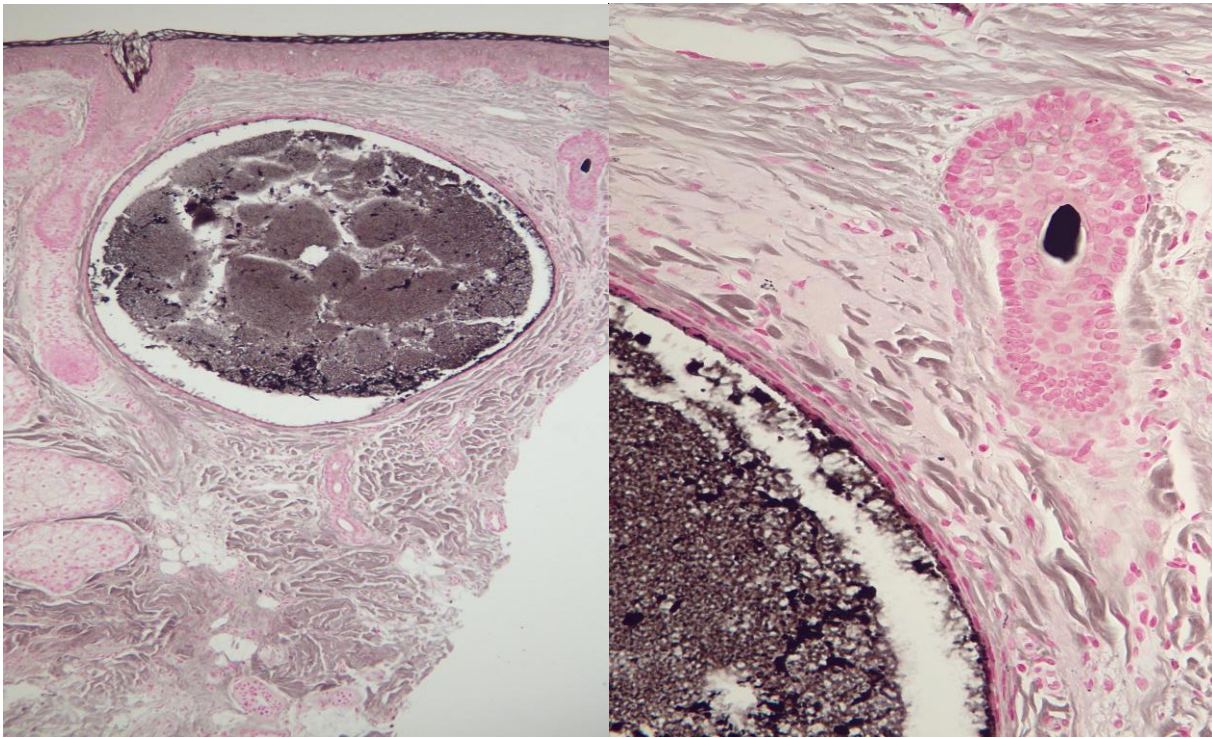
**Figure 1.** (a and b). Distant (a) and closer (b) tangential views of a solitary pigmented hidrocystoma of the nasal epithelium presenting as a blue, less than 1mm macule on the left upper nasal bridge.

Microscopic examination showed a cystic structure within the dermis composed of flattened epithelial cells (Figure 2).



**Figure 2.** (a and b). Distant (a) and close (b) views of a pigmented hidrocystoma show a cystic lesion in the dermis lined by flattened epithelial cells lacking papillary projections into the cyst lumen which contains smudgy brown material. (Hematoxylin and eosin; a=10x. b=20x)

The lumen of the cyst contains smudgy brown material. The contents of the lumen stained positively with Fontana-Masson stain (Figure 3) and did not stain with Perls stain.



**Figure 3.** (a and b). Distant (a) and close (b) views of a pigmented eccrine hidrocystoma showing positive Fontana-Masson staining of the material in the cyst lumen indicating the presence of melanin in the secretions. The hair shaft also stains positive for melanin. (Fontana Masson; a=10x. b=20x)

Correlation of the clinical presentation and pathologic findings established the diagnosis of an eccrine pigmented hidrocystoma. The tumor had been completely removed with the punch biopsy. The biopsy site healed and the hidrocystoma has not recurred.

## Discussion

Multiple eccrine hidrocystomas were first described by Robinson in 1893 [1]. The lesions were seen in women who worked in hot and humid environments and increased in both size and number during the summer months [1]. Subsequently, in 1973, Smith and Chernosky described a similar, but single, lesion that affected men and women equally and did not have seasonal variation [2]. To acknowledge these investigators, these two presentations of eccrine hidrocystomas are referred to as the “Robinson” and the “Smith and Chernosky” types of hidrocystoma, respectively.

Apocrine hidrocystomas typically present as a single cyst. Although there are several individual reports of multiple apocrine hidrocystomas, this is an uncommon presentation [3]. Historically, apocrine hidrocystomas have been considered a proliferation of apocrine glands. However, some investigators consider them to be simple retention cysts [4].

Eccrine and apocrine hidrocystomas are seen in adults 30-70 years of age. Solitary eccrine and apocrine hidrocystomas are equally prevalent between men and women. However, multiple eccrine hidrocystomas are predominantly seen in women [5].

Multiple eccrine hidrocystomas have been associated with Parkinson’s disease [6] and Grave’s disease. Hyperhidrosis is speculated as a possible predisposing etiology of multiple eccrine hidrocystomas in patients with thyroid disease [7]. Multiple apocrine hidrocystomas are associated with genetic disorders such as Goltz-Gorlin (nevroid basal cell carcinoma) syndrome, and Schopf-Schulz-Passarge syndrome; the latter is classified by eyelid apocrine hidrocystomas, palmoplantar keratoderma, hypodontia, and hypotrichosis [8, 9].

Eccrine hidrocystomas classically present as asymptomatic, solitary or multiple, lesions of the periorbital and malar areas. However, they can also appear on the head, neck, and trunk. They are typically flesh colored, translucent, amber, or light blue cysts that grow slowly and persist indefinitely after attaining full size. When incised, clear fluid drains from the cysts [1, 6, 10, 11].

Eccrine hidrocystomas tend to be smaller (1-6 mm in diameter) than apocrine hidrocystomas (3-15 mm in diameter). They are exacerbated by hot, humid weather [1, 7, 8]. In contrast, apocrine hidrocystomas are more likely to be solitary and darkly pigmented [2]. They are common near the inner canthus. However, apocrine hidrocystomas are less likely to present in either the periorbital area or body sites where apocrine glands are typically prominent [4, 5, 12].

Hidrocystomas are dermal cysts that present as apocrine or eccrine derivation. Eccrine type are uniloculated cysts characterized by 1 to 2 layers of smooth cuboidal or flat epithelial cells with eosinophilic cytoplasm [4, 7, 10]. Eccrine hidrocystomas can be distinguished from apocrine hidrocystomas; they lack decapitated columnar epithelium or flattened, vacuolated myoepithelial cells. In contrast to eccrine hidrocystomas, apocrine hidrocystomas are often multiloculated and their secretory cells contain PAS-positive diastase-resistant granules [13]. Papillary projections into the cyst lumen are seen in 50% of apocrine hidrocystomas. However, apocrine hidrocystomas can be distinguished from apocrine cystadenomas [4, 14]; in contrast to apocrine hidrocystomas, which are non-proliferative cystic lesions, apocrine cystadenomas have florid papillary projections, true papillae, and positive Ki-67 staining (Table 1) [7, 8, 10, 15-18].

**Table 1.** Differential diagnosis of pigmented hidrocystoma [a]

|           |   |
|-----------|---|
| Clinical  | Angioma <sup>15</sup><br>Basal Cell carcinoma (pigmented) <sup>CR,7,8</sup><br>Blue nevus <sup>CR,8,10,15</sup><br>Comedone, open <sup>CR</sup><br>Eccrine poroma (pigmented) <sup>16</sup><br>Epidermoid cyst <sup>15</sup><br>Glomus tumor <sup>15</sup><br>Hemangioma <sup>10</sup><br>Lipoma <sup>15</sup><br>Melanoacanthoma <sup>16</sup><br>Melanoma <sup>CR,7,8,10,15</sup><br>Nodular hidroadenoma (pigmented) <sup>16</sup><br>Pilomatrixoma (pigmented) <sup>16</sup><br>Seborrheic keratosis (pigmented) <sup>16</sup><br>Syringoma <sup>10</sup><br>Tattoo <sup>CR</sup><br>Venous lake <sup>8</sup> |
| Histology | Cystadenoma <sup>17,18</sup><br>Apocrine<br>Eccrine<br>Mixed Tumor <sup>18</sup><br>Apocrine<br>Papillary adenoma <sup>18</sup><br>Eccrine  |

[a] Abbreviations: CR= current report

One group of investigators reported different expressions of keratins and human milk fat globulin I between eccrine hidrocystomas and apocrine hidrocystomas [19]. However, other researchers have suggested that all hidrocystomas are of apocrine origin and the characteristic decapitations of apocrine hidrocystomas are attenuated by the intraluminal pressure of some cysts [20].

Pigmented fluid has classically been attributed to the Tyndall phenomenon or the presence of lipofuscin pigment since stains are negative to weakly positive for melanin (S-100) and negative for hemosiderin (Perls iron) [11, 14, 16, 21, 22]. However, positive staining for melanin with Fontana-Masson or S-100 has been reported in solitary eccrine hidrocystoma but not the Robinson, multiple lesion type. Normally, S-100 protein is only found in the secretory cells of eccrine glands, indicating that solitary eccrine hidrocystomas arise from the secretory part of the eccrine gland and the Robinson type arises from the ductal part [21]. The contents of our patient's hidrocystoma stained positive for melanin as demonstrated by the Fontana-Masson stain.

Pigmented hidrocystomas, in comparison to the non-pigmented typical variant of the tumor, are less commonly observed. They are usually located on the eyelid. However, other sites include the cheek, ear, eyebrow, forearm, nose, periorbital, perioral, temple, and vulvar areas (Table 2) [16, 20, 22-32].

**Table 2.** Location and characteristics of pigmented hidrocystoma [a]

| Site             | Solitary                  | Multiple                                     |
|------------------|---------------------------|--|
| Extremity        |                           |  |
| Forearm          | None described            | Apocrine <sup>23</sup>                       |
| Face             |                           |  |
| Auricular        | Apocrine <sup>24</sup>    | None described                               |
| Cheek            | Apocrine <sup>16,24</sup> | Eccrine <sup>20</sup>                        |
| Forehead & Scalp |                           |  |
| Forehead         | None Described            | Apocrine <sup>23</sup>                       |
| Temple           | Apocrine <sup>24,25</sup> | Apocrine <sup>23</sup>                       |
| Nose             | Eccrine <sup>CR, 26</sup> | Apocrine <sup>27</sup> Eccrine <sup>28</sup> |
| Ocular           |                           |  |
| Eyebrow          | Apocrine <sup>24</sup>    | None described                               |
| Eyelid           | Apocrine <sup>29,30</sup> | Apocrine <sup>22</sup> Eccrine <sup>20</sup> |
| Periorbital      | Apocrine <sup>30,31</sup> | Eccrine <sup>20</sup>                        |
| Oral             |                           |  |
| Perioral         | None described            | Eccrine <sup>20</sup>                        |
| Genital          |                           |  |
| Vulva            | Eccrine <sup>12,32</sup>  | None described                               |

[a] Abbreviations:, CR= current report

Hidrocystomas on the nose are uncommon. Pigmented hidrocystomas on the nose are indeed rare. Including our patient, pigmented hidrocystomas have only been described in 4 patients (Table 3) [26, 27, 28]. Our patient, and two other Caucasian individuals, (including another man and a woman), were reported with eccrine hidrocystomas; an Asian man had a pigmented apocrine hidrocystoma. The patients ranged in age at the time of diagnosis from 44 years to 67 years (median, 58 years). The pigmented hidrocystomas were either solitary (2 patients) or multiple (2 patients). A man with multiple eccrine hidrocystomas had lesions on his distal nose, but also in the periorbital area. A second man had multiple apocrine hidrocystomas located only on his nose. The lesions presented as a blue to dark blue to slightly blackish macules or papules. They did not itchy and were not painful. In our patient, the lesion would intermittently bleed.

**Table 3.** Clinical features of pigmented hidrocystomas of the nose [a]

| Case                                       | 1   | 2                                 | 3   | 4   |
|--|---|-----------------------------------|---|---|
| Age, Sex, Race                             | 44y white M   | 52y white M                       | 63y white F   | 67y Chinese M   |
| Single vs multiple                         | Multiple  | Single                            | Single  | Multiple  |
| Location                                   | Distal nose and perioral                                | Left nasal bridge                 | Left ala  | Right nasal side wall and ala                           |
| Size                                       | 0.5-1 mm  | <1mm                              | 2mm   | 7x6,5x4,3x3,2x2   |
| Duration                                   | 10 years  | 1 year                            | 6 years   | 20 years  |
| Bleed/Itch/Pain                            | -/-/-   | +/-/-                             | -/-/-   | -/-/-   |
| Color                                      | Dark blue   | Blue                              | Dark blue   | Slightly blackish                                       |
| Morphology                                 | Papule  | Macule                            | Papule  | Macules   |
| Treatment                                  | Biopsy  | 2mm punch                         | 4mm punch   | CO2 laser [b]   |
| Derivation                                 | Eccrine   | Eccrine                           | Eccrine   | Apocrine  |
| Cell type/decapitation/myoepithelial cells | 2 layer cuboidal cells with eosinophilic cytoplasm/- /- | Flattened epithelial cells/ - / - | 1-2 layer cuboidal cells with eosinophilic cytoplasm/ - / - | Cuboidal apocrine cells with papillary projections/ +/+ |

|           |                                  |                |      |      |
|-----------|----------------------------------|----------------|------|------|
| Stains    | S-100 -/<br>PAS+DR<br>granules - | FM +/- Perls - | None | None |
| Reference | 28                               | CR             | 26   | 27   |

[a] Abbreviations: CO<sub>2</sub> = carbon-dioxide, CR= current report, F=female, FM = Fontana Masson, M=male, mm= millimeter, PAS+DR = Periodic acid-Schiff positive diastase-resistant, y = year, - = absent, + = present, < = less than

[b] A punch biopsy was performed to establish the diagnosis. Patient declined surgical treatment. Carbon-dioxide laser therapy was used, which resulted in a minimal decrease in pigment. The patient declined further CO<sub>2</sub> treatments.

Biopsies were performed and established the diagnosis of either eccrine hidrocystoma (3) or apocrine (1). All of the patients had several medical problems. However, these did not appear to be related to the development of their pigmented hidrocystomas. Our patient's lesion was completely removed during his biopsy. The other patients with eccrine hidrocystomas only had their lesions biopsied [26, 28]. Some of the apocrine hidrocystomas were treated with carbon-dioxide laser. In one, there was only a minimal decrease in pigmentation, and the patient declined further treatment [27].

The clinical differential diagnosis of pigmented hidrocystomas is listed in Table 1 [7, 8, 10, 15-18]. Other diagnoses for consideration include benign (open comedo, blue nevus) and malignant (basal cell carcinoma, melanoma) lesions. Dermoscopy evaluation of the woman's pigmented eccrine hidrocystoma revealed a bluish papule surrounded by several telangiectasias [26]. Since it may be difficult to differentiate these lesions based merely on visual inspection, an excisional biopsy of a small lesion will not only provide a specimen for microscopic evaluation, but also successfully remove the tumor.

The pathogenesis of the pigmented hidrocystomas is unknown. Investigators have postulated that occlusion of the sweat duct apparatus may contribute. Retention of sweat may be secondary to pore closure or abnormal eccrine sweat gland structure [5, 10].

Hidrocystomas are benign lesions. Biopsy establishes the diagnosis and the lesions seldom recur after removal. Electrosurgical destruction or excision can be used to destroy or remove the cyst, respectively. Multiple apocrine hidrocystomas have also been treated with carbon dioxide laser vaporization, or botulinum toxin A injection, or topically with either atropine or trichloroacetic acid. However, these treatments have use limiting side effects or moderate effectiveness [6, 33-37].

## Conclusion

Hidrocystomas are benign lesions of sweat duct epithelium. They present as single or multiple lesions. They may be apocrine or eccrine. They are usually flesh colored macules or papules. They can also be translucent; in this setting, they commonly present on the eyelid as a single lesion. Pigmented hidrocystomas located on the nose are rare. They are typically asymptomatic; however, our patient's lesion would intermittently bleed. They can be eccrine or apocrine, single or multiple, and range in color from blue to dark blue to slightly blackish. They usually appear as small macules ranging in size from less than 1mm to 2mm in diameter. An excisional biopsy results in not only removal of tumor but tissue for evaluation and establishment of the diagnosis. We respectfully suggest that this unique variant of hidrocystoma that is pigmented and located on the nose be referred to as a PHONE: pigmented hidrocystoma of the nasal epithelium.

## References:

1. Robinson AR. Hidrocystoma. *J Cut Gen Urin Dis* 1893;11:292-303. (no PMID number)
2. Smith JD, Chernosky ME. Hidrocystomas. *Arch Dermatol* 1973;108:676-679. PMID:4750204
3. Gupta S, Handa U, Handa S, Mohan H. The efficacy of electrosurgical and excision in treating patients with multiple apocrine hidrocystomas. *Dermatol Surg* 2001;27:382-384. PMID:11298711
4. Weedon, David. Cysts, sinuses, and pits (eccrine hidrocystoma). In: *Weedon's Skin Pathology*. Third edition, Edinburgh: Churchill Livingstone/Elsevier, 2010 pp:442-459(449).
5. Kaur C, Sarkar R, Kanwar AJ, Mohan H. Multiple eccrine hidrocystomas. *J Eur Acad Dermatol Venereol* 2002; 16:288-290. PMID:12195577
6. Lee MR, Ryman W. Multiple eccrine hidrocystomas. *Australas J Dermatol* 2004;45:178-180. PMID:15250898
7. Sarabi K, Khachemoune A. Hidrocystomas – a brief review. *MedGenMed* 2006;8:57. PMID:17406184
8. Talsania N, Langman G, Orpin SD. A blue nodule on the forehead. *Clin Exp Dermatol* 2009;34:645-646. PMID:19508482
9. Castori M, Ruggieri S, Giannetti L, Annessi G, Zambruno G. Schöpf-Schulz-Passarge syndrome: further delineation of the phenotype and genetic considerations. *Acta Derm Venereol* 2008;88:607-612. PMID: 19002348

10. Massone C, Noll P, Hofmann-Wellenhof R. Multiple, bilateral periorbital blue macules. *Clin Exp Dermatol* 2014;39:423-424. PMID:24635095
11. Anzai S, Goto M, Fujiwara S, Da T. Apocrine hidrocystoma: a case report and analysis of 167 Japanese cases. *Int J Dermatol* 2005;44:702-703. PMID:16101883
12. Ozkan Z. Multiple eccrine hidrocystomas of the vulva. *Int J Gynaecol Obstet* 2009;105:165. PMID:19110246
13. Sperling LC, Sakas EL. Eccrine hidrocystomas. *J Am Acad Dermatol* 1982; 7:763-770. PMID:6217229
14. Alfadley A, Aboud K, Tulba A, Mourad M. Multiple eccrine hidrocystomas of the face. *Int J Dermatol* 2001;40: 125-130. PMID:11328394
15. Perez-Lopez I, Garrido-Colmenero C, Balasco-Morente G, Aneriors-Fernandez J, Arias-Santiago S. Utility of ultrasound in differential diagnosis of blue lesions, hydrocyst. *Dermatol Online J* 2015;16:21. PMID:25933080
16. Malhortra R, Bhawan J. The nature of pigment in pigmented apocrine hidrocystoma. *J Cutan Pathol* 1985;12:106-109. PMID:15250898
17. Sugiyama A, Sugiura M, Piris A, Tomita Y, Mihm MC. Apocrine cystadenoma and apocrine hidrocystoma: and examination of 21 cases with emphasis on nomenclature according to proliferative features. *J Cutan Pathol* 2007; 34:912-917. PMID:18001413
18. Obaidant N, Alsaad K, Ghazarian D. Skin adnexal neoplasms - part 2: An approach to tumours of cutaneous sweat glands. *J Clin Pathol* 2007;60:145-159. PMID:16882695
19. de Viragh PA, Szeimies RM, Eckert F. Apocrine cystadenoma, apocrine hidrocystoma, and eccrine hidrocystoma: three distinct tumors defined by expression of keratins and human milk fat globulin 1. *J Cutan Pathol* 1997; 24:249-255. PMID:9138118
20. Farina M, Pique E, Olivares M, Escalonilla P, Martin L, Requena L, Sarasa JL. Multiple hidrocystoma of the face: three cases. *Clin and Exp Dermatol* 1995;20:323-327. PMID:8548991
21. Tokura Y, Takigawa M, Inoue K, Matsumoto K, Yamada M. S-100 protein-positive cells in hidrocystomas. *J Cutan Pathol* 1986;13:102-110. PMID:3522675
22. Alessi E, Gianotti R, Coggi A. Multiple apocrine hidrocystomas of the eyelids. *Br J Dermatol* 1997; 137:642-645. PMID:9390347
23. Scriber J, Regan TD, Steger JW. An unusual presentation of multiple hidrocystomas. *Cutis* 2011;88:178-181. PMID:22106725
24. Zaballos P, Banuls J, Medina C, Salsench E, Serrano P, Guionnet N. Dermoscopy of apocrine hidrocystomas: a morphological study. *J Eur Dermatol Venereol* 2014;28:378-381. PMID:23198900
25. Veradi S, Gianotti R, Pabisch S, Gasparini G. Pigmented apocrine hidrocystoma—a report of two cases and review of the literature. *Clin Exp Dermatol* 1991;16:18-21. PMID:2025927
26. Kluger N, Monthieu J, Gil-Bisters D, Guillot B. A bluish pigmented cystic lesion of the nose. *Acta Derm Venereol* 2010;90:555-556. PMID:20814652
27. Yanagi T, Sawamura D, Nishie W, Abe M, Shibaki A, Shimizu H. Multiple apocrine hidrocystoma showing plane pigmented macules. *J Am Acad Dermatol* 2006;54:S53-54. PMID:16427998
28. Bourke JF, Colloby P, Graham-Brown RAC. Multiple pigmented eccrine hidrocystomas. *J Am Acad Dermatol* 1996;35:480-482. PMID:8784293
29. Desjardins L. Benign pigmented lesions of the eyelids. *J Fr Ophthalmol* 2005;28:889-895. PMID:16249773
30. Al-Rohil RN, Meyer D, Slodkowska EA, Carlson JA. Pigmented eyelid cysts revisited: apocrine retention cyst chromhidrosis. *Am J Dermatopathol* 2014;36:318-326. PMID:24247572
31. Chin K, Finger PT, Iacob C. High-frequency ultrasound imaging of periocular hidrocystomas. *Optometry* 2003;74:760-764. PMID:14677727
32. Kamishima T, Igarashi S, Takeuchi Y, Ito M, Fukuda T. Pigmented hidrocystoma of the eccrine secretory coil in the vulva: clinicopathologic, immunohistochemical and ultrasound studies. *J Cutan Pathol* 1999;26:145-149. PMID:10235380
33. Masri-Fidling GD, Elgart ML. Eccrine hidrocystomas. *J Am Acad Dermatol* 1992;26:780-782. PMID:1583183
34. del Pozo J, Garcia-Silva J, Pena-Penabad C, Fonseca E. Multiple apocrine hidrocystomas: treatment with carbon dioxide laser vaporization. *J Dermatolog Treat* 2001;12:97-100. PMID:12243666
35. Dailey RA, Saulny SM, Tower RN. Treatment of multiple apocrine hidrocystomas with trichloroacetic acid. *Ophthal Plast Reconstr Surg* 2005;21:148-150. PMID:15778671
36. Woolery-Lloyd H, Rajpara V, Nijhawan RI. Treatment for multiple periorbital eccrine hidrocystomas: botulinum toxin A. *J Drugs Dermatol* 2009;8:71-73. PMID:19180900
37. Blugerman G, Schavelzon D, D'Angelo S. Multiple eccrine hidrocystomas: A new therapeutic options with botulinum toxin. *Dermatol Surg* 2003;29:557-559. PMID:12752528