

UC Davis

Dermatology Online Journal

Title

Striking enhancement at the site of radiation for nivolumab-induced Stevens-Johnson syndrome

Permalink

<https://escholarship.org/uc/item/97g3t63v>

Journal

Dermatology Online Journal, 24(6)

Authors

Shah, Kishan M
Rancour, Elizabeth A
Al-Omari, Ahmed
et al.

Publication Date

2018

DOI

10.5070/D3246040713

Copyright Information

Copyright 2018 by the author(s). This work is made available under the terms of a Creative Commons Attribution-NonCommercial-NoDerivatives License, available at <https://creativecommons.org/licenses/by-nc-nd/4.0/>

Peer reviewed

Striking enhancement at the site of radiation for nivolumab-induced Stevens-Johnson syndrome

Kishan M Shah BA, Elizabeth A Rancour MD, Ahmed Al-Omari MD, Sahand Rahnama-Moghadam MD MS

Affiliations: Indiana University School of Medicine, Department of Dermatology, Indianapolis, Indiana, USA

Corresponding Author: Sahand Rahnama-Moghadam MD, MS, Indiana University School of Medicine, Department of Dermatology, 545 Barnhill Drive – EH 139, Indianapolis, IN 46202, Email: srahnama@iupui.edu

Abstract

Stevens-Johnson syndrome is a rare adverse cutaneous drug reaction characterized by epidermal detachment of <10% body surface area with an average mortality rate of 1-5%. The mechanism of SJS is not fully understood. Nivolumab is a monoclonal antibody directed against programmed cell death-1 protein (PD-1), a receptor with immune checkpoint inhibitory and antineoplastic activities. We present a case of SJS in a patient being treated with anti-PD-1 therapy nivolumab for metastatic squamous cell carcinoma of the oropharynx. This case is unusual because of the severe accentuation with striking enhancement at his prior radiation site and in the cutaneous region with heavier tumor burden from his metastatic disease. This reaction may give insight to the underlying pathophysiology of SJS, suggesting that immune checkpoint inhibitors can activate T-cells to target keratinocytes and that external factors may be involved in creating distinct epitopes for T-cell recognition. We hope this case adds to the body of knowledge in the pathogenesis of Stevens-Johnson syndrome and cutaneous adverse events seen with checkpoint inhibitors.

Keywords: Stevens-Johnson syndrome, SJS, PD-1 inhibitor, drug reaction

Introduction

Stevens-Johnson syndrome (SJS) is a rare adverse drug reaction characterized by epidermal detachment of <10% body surface area (BSA) with an

average mortality of 1-5%. Exfoliation relates to extensive death of keratinocytes via apoptosis, mediated by CD8+ T-cells and natural killer cells [1] through the cytotoxic secretory protein granulysin, and the interaction of the death receptor-ligand pair Fas-FasL [2]. Nivolumab is a human immunoglobulin G4 monoclonal antibody directed against the negative immunoregulatory human cell surface receptor programmed cell death-1 (PD-1), with immune checkpoint inhibitory and antineoplastic activities [3]. Nivolumab results in activation of T-cells and cell-mediated immune responses against tumor cells, but is not known to activate the Fas-FasL

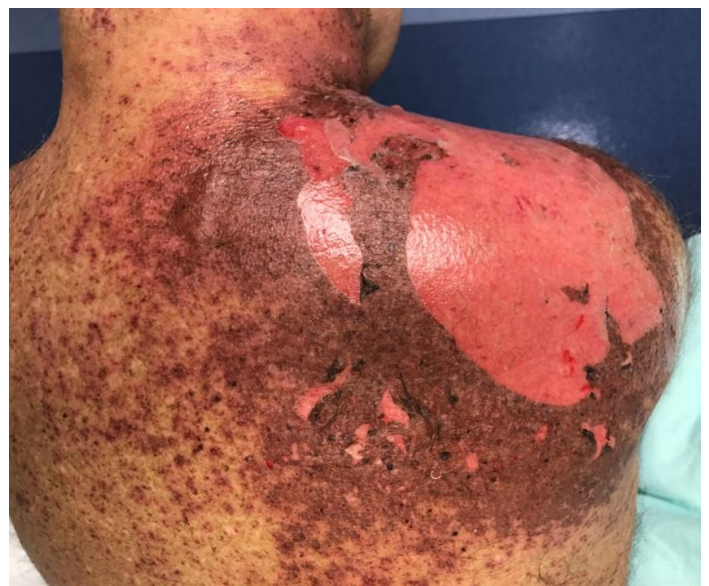

Figure 1. Confluent dusky violaceous to dark red erythema localized to the right side of his neck, right chest and right upper back involving 8% body surface area.

pathway directly [3]. We present a case of SJS accentuated in an area of previous radiation therapy in a patient being treated with nivolumab.

Case Synopsis

A 63-year-old man with a history of stage IV squamous cell carcinoma (SCC) of the uvula and soft palate was treated with neck dissection, adjuvant chemotherapy, and radiation treatment to the oropharynx and bilateral neck. He was started on anti-PD1 immunotherapy with nivolumab one day after completion of radiation. One week after the first nivolumab infusion, he developed a diffuse rash with lip crusting and conjunctival injection. He complained of worsening oral mucosal pain. He denied ocular symptoms and a full review of systems was otherwise unremarkable.

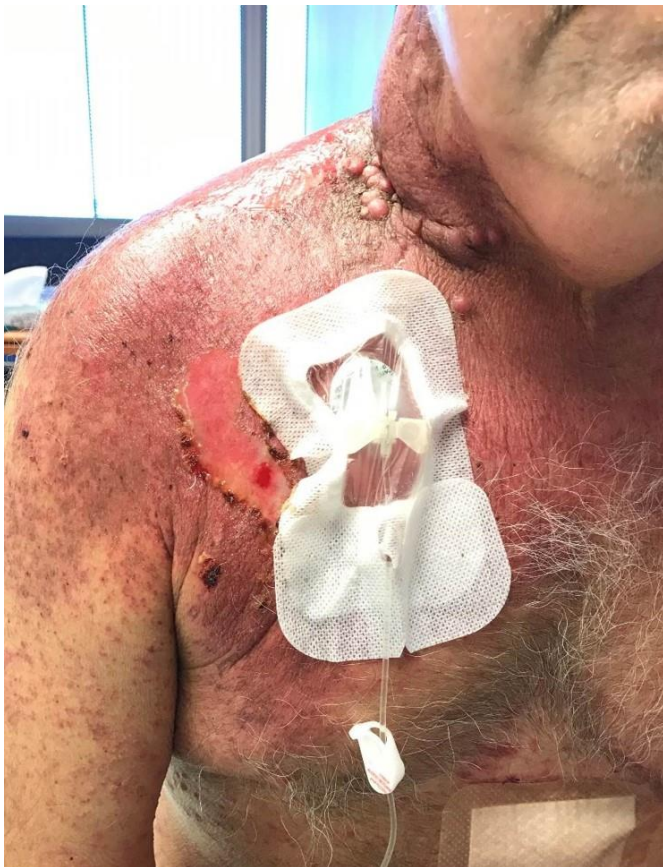

Figure 2. Desquamation most prominent on the right posterior shoulder and several 1 cm intact bullae with positive Asboe-Hansen and Nikolsky signs. In the same distribution, he had background poikilodermatous patches from prior radiation; his port was located within the area of most significant involvement as well as subcutaneous nodules from his metastatic squamous cell cancer

He had confluent dusky violaceous to dark red erythema localized to the right side of his neck, chest, and upper back involving 8% BSA. He had 2% BSA desquamation, most prominent on the right posterior shoulder and several 1cm intact bullae with positive Asboe-Hansen and Nikolsky signs (Figure 1). In the same distribution, he had background poikilodermatous patches from prior radiation; his port was within the area of poikiloderma (Figure 2). On the remainder of his exam, he had a scattering of dusky violaceous atypical targetoid papules and erosions of approximately 2% BSA, a confluent mucositis of his upper and lower mucosal lips, and bilateral conjunctival injection with mucosal eyelid erythema.

Three punch biopsies were obtained: from the right upper back (Figure 3), the right leg, and the left leg, all revealing a pauci-inflammatory interface process with numerous dyskeratotic cells, a subepidermal split, and areas of full thickness epidermal necrosis consistent with SJS. The patient recovered with supportive care alone, and future treatments with nivolumab were discontinued.

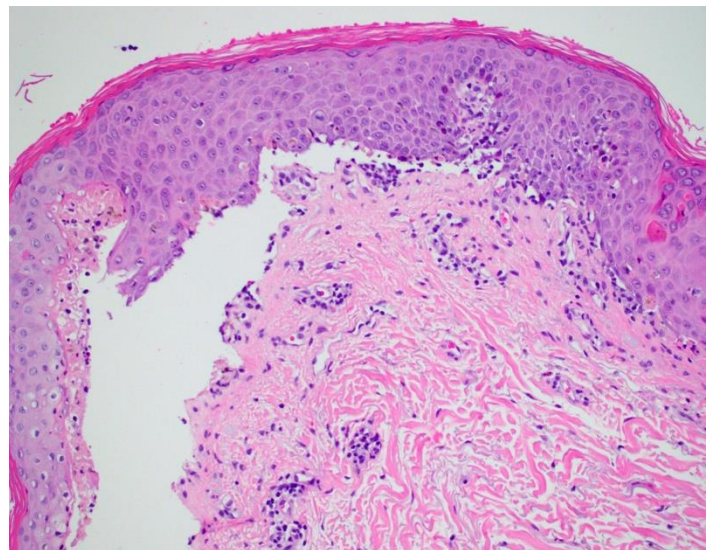


Figure 3. A biopsy of the R upper back lesion demonstrated pauci-inflammatory interface process with numerous dyskeratotic cells, subepidermal split and areas of full thickness epidermal necrosis. These findings are consistent with Stevens-Johnson syndrome. The additional two biopsies of the right and left legs demonstrated the same pathology. H&E, 200x.

Case Discussion

In summary, we present an unusual case of SJS triggered by nivolumab with striking enhancement at the site of radiation therapy. This immune checkpoint inhibitor targeting PD-1 is frequently associated with cutaneous side effects including lichenoid reactions, eczema, and vitiligo [4]. This class of drugs has also been reported to cause bullous or toxic skin reactions [5]. This case adds to the array of cutaneous adverse effects associated with immune checkpoint inhibitors.

Additionally, this case is unusual because of the distinct enhanced presentation at the site of radiation. It is unclear if this accentuation was related to an area of heavier tumor burden, history of radiation therapy, or local diffusion from the port infusion. This distribution could suggest a local fraction of T-cells being stimulated or recognizing distinctive epitopes induced by radiation or nearby cancer cells. A similar case in the literature reported pembrolizumab-induced SJS localized to an area

previously treated with radiotherapy in a patient with metastatic sarcomatoid renal cell carcinoma [6]. Additionally, a case of localized bullous pemphigoid at the site of radiation therapy induced by a PD-1 checkpoint inhibitor has been reported [7]. The sparse but scattered involvement on the remainder of his trunk and extremities does suggest a systemic component to the immune response as well.

Conclusion

This reaction may give insight to the underlying pathophysiology of SJS, suggesting programmed cell death checkpoints may be involved. Our case adds to the body of evidence that immune checkpoint inhibitors can activate T-cells to target keratinocytes and that external factors may be involved in creating distinct epitopes for T-cell recognition. Further work is needed to characterize the molecular pathways involved in the pathogenesis of this entity.

References

1. Miyauchi H, Hosokawa H, Akaeda T, Iba H, Asada Y. T-cell subsets in drug-induced toxic epidermal necrolysis. Possible pathogenic mechanism induced by CD8-positive T cells. *Arch Dermatol.* 1991;127(6):851-5. [PMID: 2036032].
2. Schwartz RA, McDonough PH, Lee BW. Toxic epidermal necrolysis: Part I. Introduction, history, classification, clinical features, systemic manifestations, etiology, and immunopathogenesis. *J Am Acad Dermatol.* 2013;69(2):173 e1-13; quiz 85-6. [PMID: 23866878].
3. Naidoo J, Page DB, Wolchok JD. Immune checkpoint blockade. *Hematol Oncol Clin North Am.* 2014;28(3):585-600. [PMID: 24880949].
4. Hwang SJ, Carlos G, Wakade D, Byth K, Kong BY, Chou S, Carlino MS, Kefford R, Fernandez-Penas P. Cutaneous adverse events (AEs) of anti-programmed cell death (PD)-1 therapy in patients with metastatic melanoma: A single-institution cohort. *J Am Acad Dermatol.* 2016;74(3):455-61 e1. [PMID: 26793994].
5. Goldinger SM, Stieger P, Meier B, Micaletto S, Contassot E, French LE, Dummer R. Cytotoxic Cutaneous Adverse Drug Reactions during Anti-PD-1 Therapy. *Clin Cancer Res.* 2016;22(16):4023-9. [PMID: 26957557].
6. Saw S, Lee HY, Ng QS. Pembrolizumab-induced Stevens-Johnson syndrome in non-melanoma patients. *Eur J Cancer.* 2017;81:237-9. [PMID: 28438440].
7. Hirotsu K, Chiou AS, Chiang A, Kim J, Kwong BY, Pugliese S. Localized bullous pemphigoid in a melanoma patient with dual exposure to PD-1 checkpoint inhibition and radiation therapy. *JAAD Case Reports.* 2017;3(5):404-6. [PMID: 28884139].