

## Case Presentation

### A case of Griscelli syndrome

Joshi Anand Kerketta MD DNB<sup>1</sup>, Moushumi Lodh MD<sup>2</sup>, Krishanu Mandal MD<sup>3</sup>

Dermatology Online Journal 20 (11): 2

<sup>1</sup>Pediatrics, Department of Pediatrics, The Mission Hospital, Durgapur, West Bengal, India

<sup>2</sup>Biochemistry, Laboratory Services, The Mission Hospital, Durgapur, West Bengal, India.

<sup>3</sup>Pediatrics, Department of Pediatrics, The Mission Hospital, Durgapur, West Bengal, India

### Correspondence:

Dr Moushumi Lodh, M.D Biochemistry  
The Mission Hospital, Sector 2C, Immon kalyan sarani, Bidhannagar, Durgapur  
West Bengal, India, pin-713212  
E-mail id:drmoushumilodh@gmail.com

## Abstract

A hallmark of Griscelli syndrome, a rare autosomal recessive disorder, is hair hypopigmentation characterized by a silver-gray sheen and the presence of large clusters of pigment unevenly distributed in the hair shaft. Either a primary neurological impairment or immune abnormalities are associated with this phenotype. We report the case of a 10-year-old child of consanguineous parents. He presented with abdominal pain and fever and was noted to have silvery hair, eyelashes, and eyebrows. Bone marrow studies indicated hemophagocytosis, whilst microscopic examination of the hair showed irregular agglomerations of pigment in hair shafts. The prognosis, treatment, and genetic counseling needs differ considerably among the various forms of Griscelli Syndrome.

**Keywords: hair depigmentation; hemophagocytic lymphohistiocytosis; partial albinism; melanosomes; pancytopenia; hypertriglyceridemia**

## Introduction

Griscelli and Prunieras initially described Griscelli syndrome (GS; MIM 214450) or partial albinism with immunodeficiency, in 1978 [1]. Three genetic defects identified in Griscelli syndrome [GS] are the gene encoding the molecular motor protein Myosin 5a [MYO5A][type 1 GS], the guanosine triphosphate (GTP)-binding protein [RAB27A], a reticular activating system-associated protein (RAS-associated protein) [type 2 GS], and a homozygous missense mutation in human melanophilin [MLPH], the phenotype of which is restricted to hypopigmentation [type 3 GS] [2]. Silvery gray hair is common to all three, but immunological defects are only seen in the patients with Griscelli syndrome type 2. Genetic linkage analysis has localized Griscelli syndrome to chromosome 15q21. More than forty cases have been documented and most cases have been reported from Turkish and Mediterranean populations [3].

## Case synopsis

A ten-year-old boy was admitted to our hospital with abdominal pain for three days and fever of ten days duration. The pain was periumbilical and was neither related to eating nor associated with any radiation of pain. The patient complained of constipation

and nausea over three days. There was no abdominal distension, melena, or hematemesis. The fever was high grade, associated with generalized body aches and not associated with rigor.

He had no chest pain, cough, headache, diarrhea, bleeding, easy bruisability, photophobia, loss of consciousness, seizures, altered sensorium, jaundice, dysuria, chest pain, dry eyes, or breathing difficulty. There was no history of nystagmus, drug intake, mucosal involvement, or other relevant complaints. There was no history of Herpes simplex or other exanthemas. He had a mild degree of photosensitivity. There was no rash, bleeding, joint pain, joint swelling, or oral ulcers. The urine output was adequate but high colored. There were no features suggestive of Raynaud phenomenon.

Our patient was the 4<sup>th</sup> child born to consanguineous parents by normal vaginal delivery at term. His development was normal and he was in adequately immunized for age. A younger sibling had died of similar complaints two years prior. There was no history of transfusions received in the past. There was no history of contact with tuberculosis.

At admission, his vitals were stable. His height was 124 cms; his weight was 23 kg and head circumference was 48 cms. He had silvery grey hair on the face, scalp, eyelids, eyebrows, and forearms (Figure 1). He had pallor, icterus, and bilateral pitting pedal edema. Fundus examination did not reveal any abnormality. There were no enanthema or exanthema. There was pallor. He had no clubbing, edema, cyanosis, or jaundice. Hess Test was negative. Multiple, non tender, non-matted cervical and jugulodigastric lymph nodes were palpable. Abdominal examination revealed firm hepatomegaly and splenomegaly. The respiratory examination revealed decreased air entry on both sides with dullness to percussion in the left infra-axillary and interscapular areas. Cardiovascular and central nervous system examinations were within normal limits.

Laboratory investigations were as follows [reference ranges in parantheses]: hemoglobin 10.6 gm/dl [11-15.5], total leukocyte count 9200 cells/cu.mm[4000-10,000], total erythrocyte count 4.13 million/cumm[4.5-5.5], hematocrit 30.5 % [45-50], platelet 1.33 lakhs/cumm[1.5-4], MCV 73.9 fl[83-101], MCH 27pg[27-31], MCHC 36.5 [31.5-34.5], erythrocyte sedimentation rate 84 mm in 1<sup>st</sup> hour [5-15], lymphocytes 67%, neutrophils 30%, monocytes 2%, and basophils 1%, fibrinogen 1.7 g/dL [ 2-4 ]. Direct Coomb's test was negative and the peripheral blood smear showed no giant cytoplasmic granules in leukocytes.

Procalcitonin was 3.24 ng/ml [ $<0.5$ ] with a CRP of 140 mg/L [ $\leq 6$ ]. Prothrombin time and activated partial thromboplastin time were within reference range. Serum electrolytes, uric acid, calcium, and creatinine were normal. Liver function test revealed total bilirubin of 0.4 mg% [up to 1], direct bilirubin of 0.1 mg% [upto 0.3], total protein of 5.9 gm% [6.5-8.1], albumin of 2.5 gm% [3.5-5], SGOT of 135 U/L, SGPT 124U/I, and alkaline phosphatase 207 U/L. Serum ferritin was 1352 ng/ml [30-300], cholesterol 170 mg% [ $<200$ ], triglycerides 297 mg% [ $<200$ ], high-density lipoprotein cholesterol 48 mg% [ $>40$ ], and low-density lipoprotein cholesterol 59 mg%. [ $<100$ ]. Serum lactate dehydrogenase was 704 U/L [266-500], creatine phosphokinase 657 U/L[33-186]. Serum amylase, lipase, ceruloplasmin, urinary electrolytes, serum immunoglobulins G and M, and random plasma glucose were within reference range. Serum immunoglobulin A was slightly below reference range. Serology was non reactive for hepatitis (HAV and HBV), HIV, dengue IgG, IgM, NS1Antigen, Brucella, kala azar, Malaria, typhoid and Weil Felix. The anti dsDNA [crithidia] and anti-nuclear antibodies [IFA Hep2] were negative at  $<1:80$  titer and  $<1:10$  titer, respectively. Urine and stool routine examination and microscopy showed no abnormality; urine culture showed no growth after 48 hours incubation. Blood culture showed methicillin resistant staphylococcus aureus.

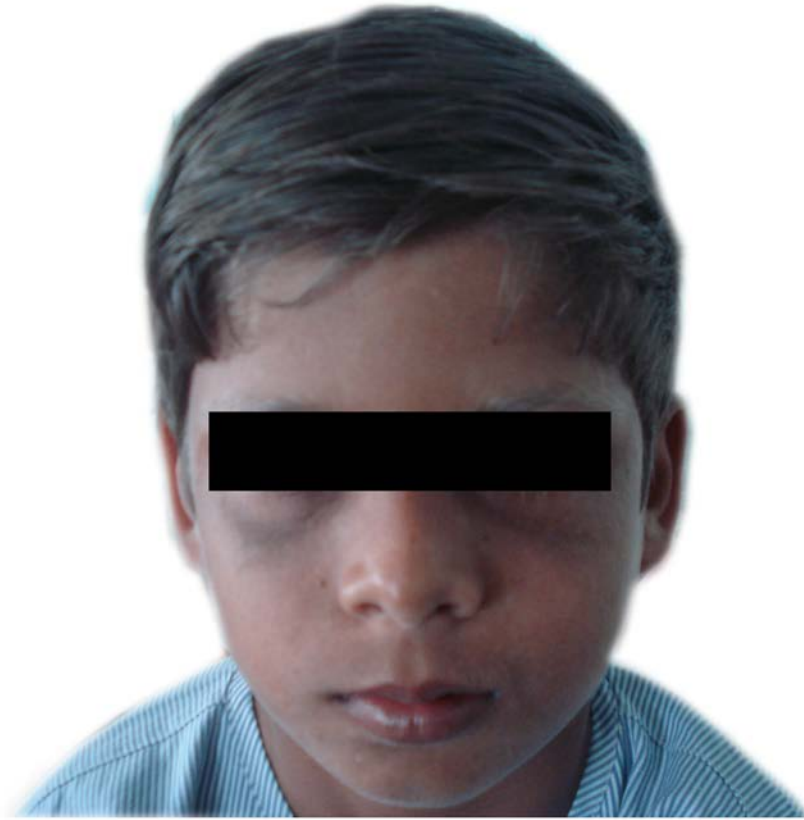Chest radiograph revealed bilateral pneumonitis. Ultrasonography of the abdomen revealed hepatosplenomegaly and bilateral pleural effusion. An echocardiogram showed minimal pericardial effusion with no evidence of vegetations. The Mantoux test was negative. Bone marrow aspiration samples revealed slight hypocellularity with mild erythroid hyperplasia and hemophagocytosis (Figure 2). There were no abnormal cells in the bone marrow; no hemoparasites were identified.

Hair shaft examination revealed an uneven accumulation of large pigment granules instead of the homogenous distribution of small pigment granules as seen in a normal hair shaft (Figure 3). His hair biopsy revealed clumped pigment deposition in the basal epithelial layer and pigment in the keratinocytes.

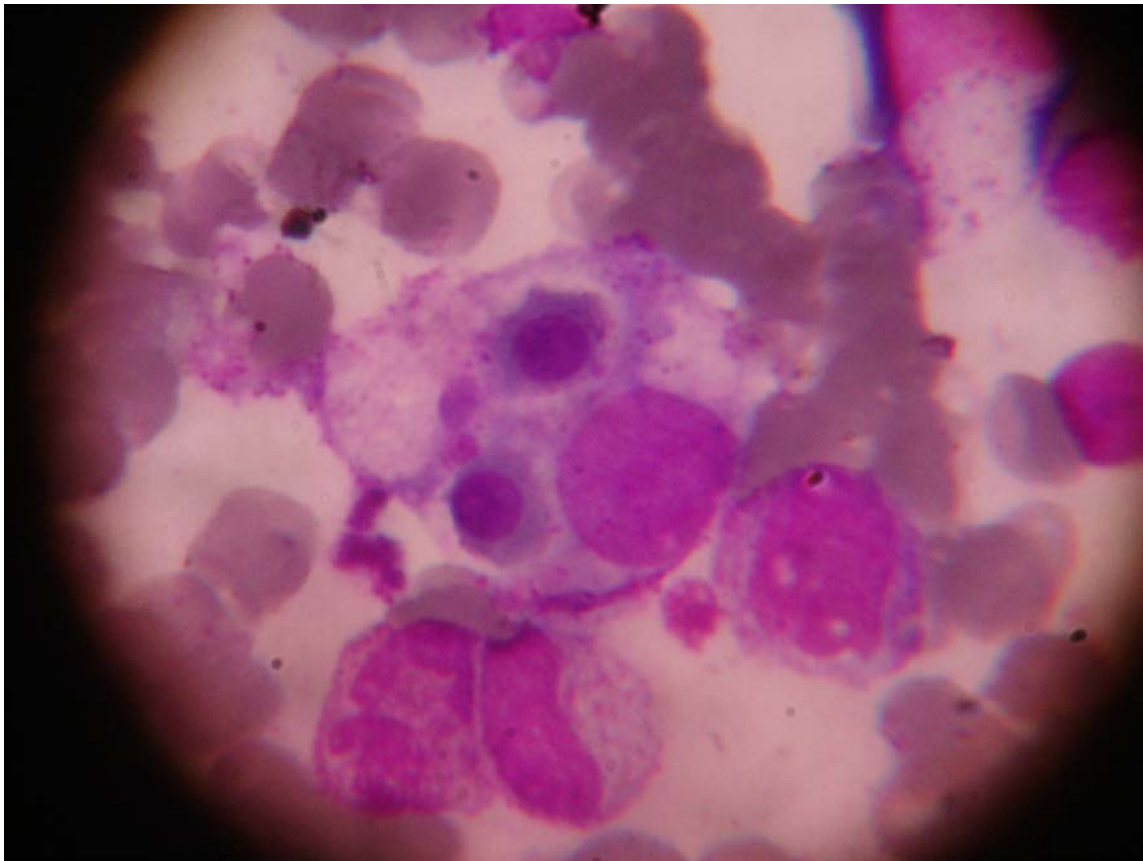
Hair depigmentation suggested Chediak-Higashi syndrome or GS. The absence of giant cytoplasmic granules in leukocytes in the peripheral blood smear helped us rule out Chediak-Higashi syndrome. Collagen vascular diseases were ruled out by negative autoantibodies (ANA, DsDNA). Typical features of microcytic anemia, thrombocytopenia, hypofibrinogenemia, hypertriglyceridemia, high serum ferritin, hypoproteinemia with hemophagocytes in bone marrow, and hair depigmentation helped us diagnose this case as Griscelli syndrome with infection associated hemophagocytosis. Evidence of liver involvement was demonstrated by abnormal liver function results and hepatosplenomegaly detected in the abdominal ultrasonogram.

He was treated with IV fluids and appropriate antibiotics and later was started on corticosteroids (methyl prednisolone). Owing to financial constraints, definitive diagnosis by molecular analysis to identify the mutation and stem cell therapy could not be

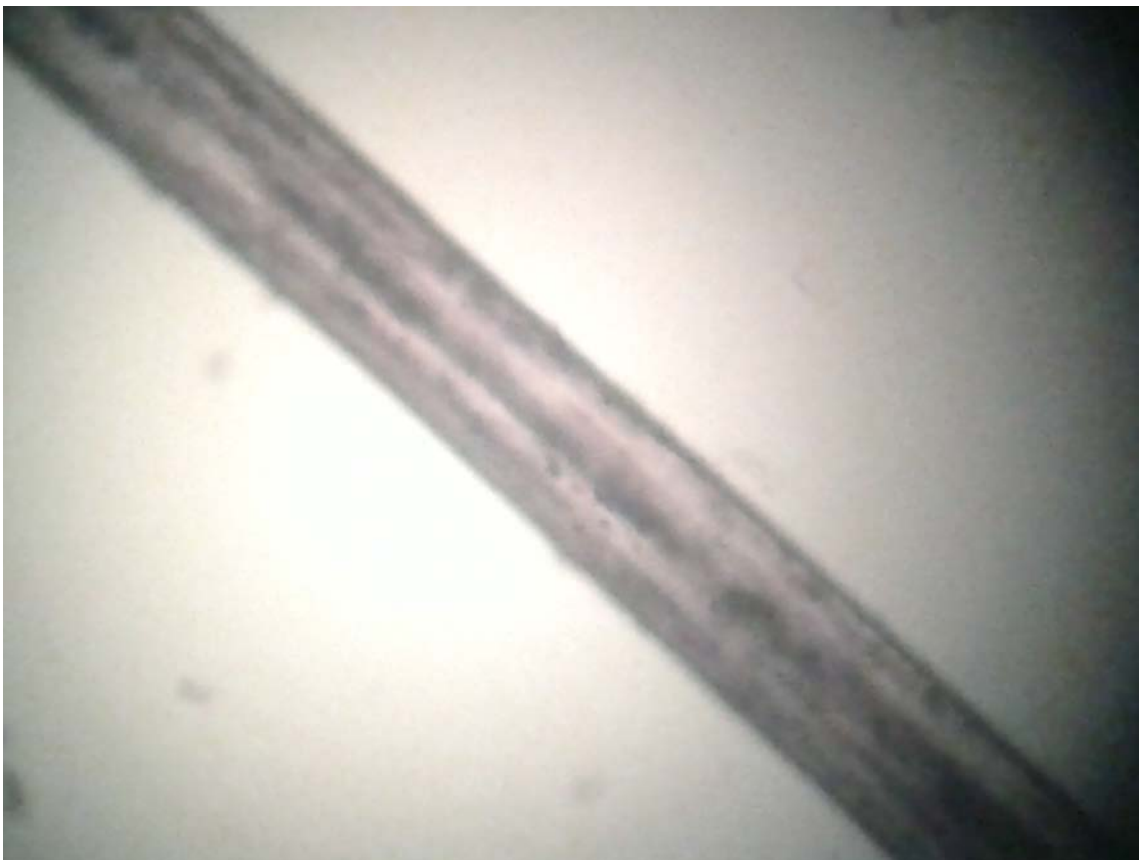pursued. The patient was managed with corticosteroids and appropriate antibiotics for his staphylococcal septicemia. The repeat ultrasound of the chest showed no evidence of pleural effusion. The fever gradually decreased. The serial monitoring of his C reactive protein showed a gradual decline to normal levels. After completion of his course of antibiotics he was discharged.



**Figure 1.** Silvery grey hair on face, scalp, eyelids and eyebrows



**Figure 2.** Hemophagocytosis in the bone marrow study



**Figure 3.** Light microscopy of patient's hair shafts showing clumps of pigment irregularly distributed along the hair shaft

## Discussion

Light microscopy of hair shaft in GS shows irregular, large aggregations of melanin pigment in hair [4]. If equivocal, polarized light microscopy of hair shafts aids in the differential diagnosis of Chediak-Higashi syndrome and Griscelli syndrome [5]. The gene products of MYO5A and RAB27A form a tripartite complex with the MLPH gene product producing melanophilin (RAB27A-MLPH-MYO5A) facilitating intracellular melanosome transport [6]. The MYO5A and RAB27A anomalies lead to defective transport of melanosomes, which are not transported properly to surrounding keratinocytes, leading to the characteristic feature of hyperpigmented basal melanocytes and sparse pigmentation of adjacent keratinocytes. This pathology of melanocytes and keratinocytes leads to large, clumped melanosomes in hair shafts; as a result the hair has a silvery-gray sheen. These results can be highlighted in Fontana-Masson-stained sections.

Since MYO5A is expressed in the brain, defects in MYO5A cause neurologic pathology. Children with GS caused by a defect in the RAB27A gene develop an uncontrolled T-lymphocyte and macrophage activation syndrome known as hemophagocytic syndrome (HS) or hemophagocytic lymphohistiocytosis (HLH) [7]. Ramzan et al reported that in eight infants diagnosed with HLH, the mean age was 7.1 months (range 2–11) [8]. A report describes a Griscelli syndrome type I patient alive at age 21 years without problems except motor retardation and severe mental retardation and 2 patients with Griscelli syndrome type 3, healthy at ages 21 and 24 years, manifesting merely with silvery gray hair, eye brows, and eyelashes and cutaneous pigmentary dilution [9].

The diagnosis of GS should be considered for any child with hypopigmentation, associated with neurological symptoms or signs of the accelerated phase of the disease, like hepatosplenomegaly, pancytopenia, and lymphadenopathy. Microscopic examination of the hair shaft provides strong support to the diagnosis of GS. Mutation analysis of the patient's DNA provides confirmation. Chemotherapy and stem cell transplantation [10] are recommended treatment modes. However, the prognosis for long term survival of GS patients is poor. Prompt identification of the genetic disorder leading to HLH may confirm the indication for allogeneic hematopoietic stem cell transplantation as the only curative tool; other less severe conditions should be identified as soon as possible in order to avoid potentially unnecessary and life-threatening treatments. Further studies are needed to assess the correlation between genotype and phenotype and aid in medical decision-making. Our patient's parents were consanguineous and they had already lost a child with similar problems. Genetic counseling and educational programs are required to highlight the higher incidence of autosomal recessive diseases in consanguineous families.

## References

1. 1. Griscelli C, Prunieras M. Pigment dilution and immunodeficiency: a new syndrome. *Int J Dermatol*. Dec 1978; 17(10):788-91. [PMID: 730432]
2. 2. Ménasche G, Ho CH, Sanal O, Feldmann J, Tezcan I, Ersoy F, Houdusse A, Fischer A, Basile GDS. Griscelli syndrome restricted to hypopigmentation results from a melanophilin defect (GS3) or a MYO5A F-exon deletion (GS1) . *J. Clin. Invest.*2003; 112:450–456. [PMID: 12897212]
3. 3. Vieira- Karuta SC et al. Griscelli syndrome and electroencephalography pattern. *Arq. Neuro-Psiquiatr.*2008;66(2):420-422. [PMID: 18641887]
4. 4.Celik HH, Tore H, Tunali S, Tatar I, Aldur MM. Light and scanning electron microscopic examination of hair in Griscelli syndrome. *Saudi Med J*. Aug 2007; 28(8):1275-7. [PMID: 17676217]
5. 5. Valente NY, Machado MC, Boggio P, et al. Polarized light microscopy of hair shafts aids in the differential diagnosis of Chédiak-Higashi and Griscelli-Prunieras syndromes. *Clinics (Sao Paulo)*. Aug 2006; 61(4):327-32.[PMID: 16924324]
6. 6. Van Gele M, Dynoodt P, Lambert J. Griscelli syndrome: a model system to study vesicular trafficking. *Pigment Cell Melanoma Res*. Jun 2009; 22(3):268-82. [PMID: 19243575]
7. 7.Aslan D, Sari S, Derinoz O, Dalgic B. Griscelli syndrome: description of a case with Rab27A mutation. *Pediatr Hematol Oncol*. Apr-May 2006; 23(3):255-61.[ PMID:16517541]
8. 8. Ramzan M, Yadav SP, Kharya G, Chinnabhandar V, Enteserian M, Henter J, Sachdeva A.
9. Hemophagocytic lymphohistiocytosis in infants: a single center experience from India.*Pediatr Hematol Oncol*. 2014; 31(3):285-92. [PMID:24383954]
10. 9. Cagdas D, Ozgür TT, Asal GT, Tezcan I, Metin A, Lambert N, et al. Griscelli syndrome types 1 and 3: analysis of four new cases and long-term evaluation of previously diagnosed patients. *Eur J Pediatr*. Oct 2012; 171(10):1527-31. [PMID: 22711375]
11. 10.Cesaro S, Locatelli F, Lanino E, et al. Hematopoietic stem cell transplantation for hemophagocytic lymphohistiocytosis: a retrospective analysis of data from the Italian Association of Pediatric Hematology Oncology (AIEOP). *Haematologica* 2008; 93 (11):1694-701. [PMID: 18768529]