

Multifocal primary cutaneous nodular amyloidosis

Martha Emily Matsumoto¹, Mary-Katharine Collins², Anastasios Raptis³, Jaroslaw Jedrych², Timothy Patton²

Affiliations: ¹University of Pittsburgh School of Medicine, Pittsburgh, Pennsylvania, ²Department of Dermatology, University of Pittsburgh Medical Center, Pittsburgh, Pennsylvania, ³Department of Medicine, Division of Hematology/Oncology, University of Pittsburgh Medical Center, Pittsburgh, Pennsylvania

Corresponding Author: Timothy Patton, DO, Department of Dermatology, University of Pittsburgh Medical Center, 3601 Fifth Avenue, Pittsburgh, PA, 15213, Ph: 412-681-1072, Fax: 412-647-4137, pattyj@upmc.edu

Abstract

Nodular cutaneous amyloidosis (NCA), the least common form of primary cutaneous amyloidosis, is characterized clinically by waxy, purpuric plaques and nodules and histologically by amyloid deposits in the dermis and subcutaneous tissue. We present a patient who developed multiple, non-contiguous NCA lesions over a three year period without evidence of systemic disease. We reviewed the literature and found few other cases of this unusual presentation.

Keywords: amyloidosis, primary cutaneous amyloidosis, cutaneous manifestations of systemic disease, cutaneous oncology

Introduction

Nodular cutaneous amyloidosis (NCA) is the least common form of primary cutaneous amyloidosis and is characterized by waxy, brown, purpuric plaques and nodules, usually involving one area of the body [1]. The pathogenesis of NCA is not precisely known, but may represent a dysfunction of localized plasma cells in the skin; the association of NCA with systemic amyloidosis is low [1, 2]. We describe a patient with multiple lesions of NCA without evidence of systemic disease.

Case Synopsis

At the time of presentation, the patient was a 59-year-old man with a two year history of skin lesions, which initially occurred on the back. The lesions were asymptomatic and relatively stable in appearance,

occasionally becoming more prominent and vesicular appearing at times, but never completely regressing. The patient had no significant past medical history and was not taking any medications. Examination demonstrated multiple irregularly shaped reddish-brown plaques on the back and chest (**Figure 1**). A biopsy was performed which demonstrated superficial dermal and perivascular deposits of eosinophilic, amorphous material, as well as a mild perivascular infiltrate composed of lymphocytes, histiocytes, and plasma cells (**Figure 2**). The deposits were positive for thioflavin-T (**Figure 3**), congo red, and both kappa and lambda light chains. Mass spectrometry confirmed AL amyloid, lambda type.

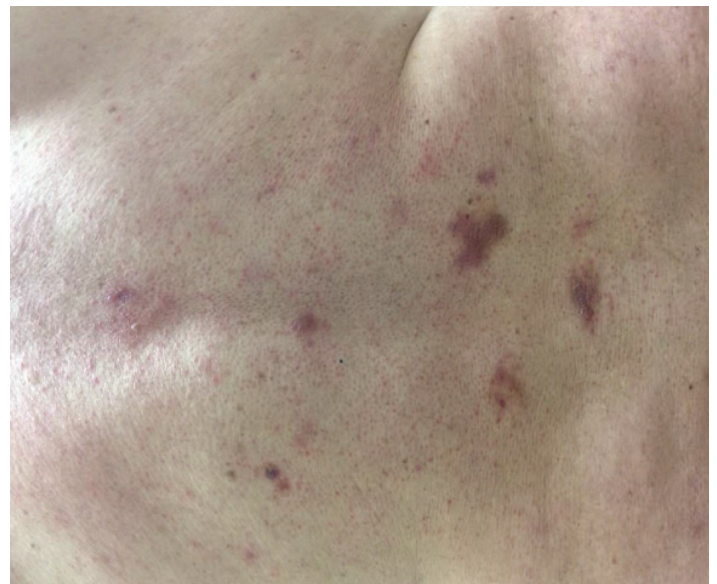

Figure 1. Multiple well demarcated irregularly shaped reddish brown plaques on the lower back.

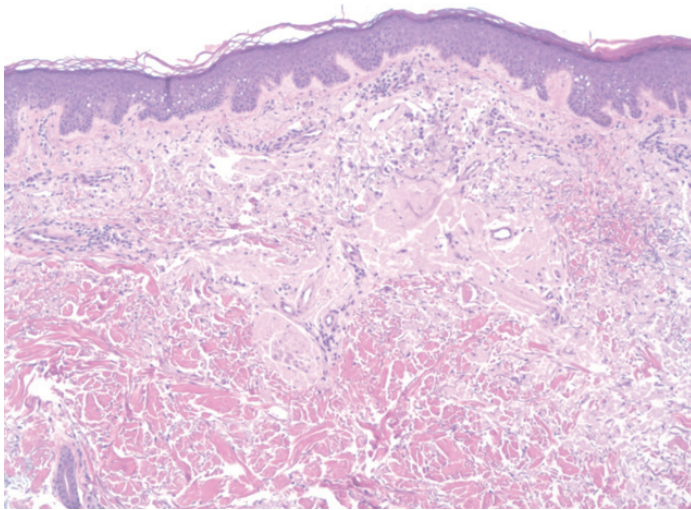


Figure 2. H&E demonstrating superficial dermal and perivascular deposits of eosinophilic, amorphous material, (200x).

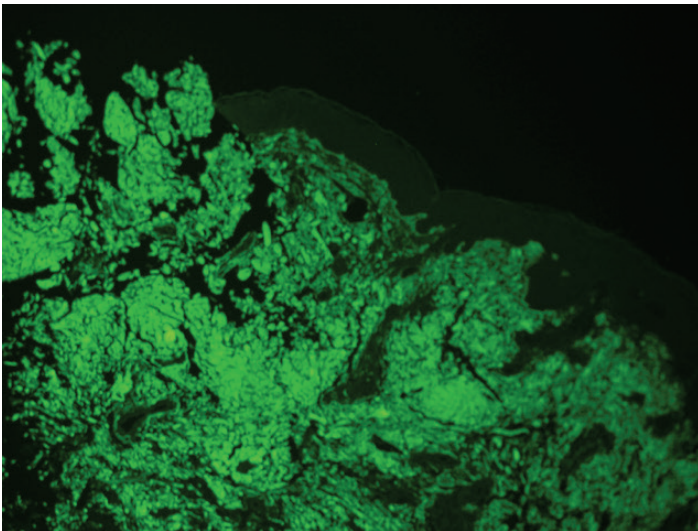


Figure 3. Positive thioflavin T immunofluorescence stain for amyloid (200x).

Laboratory workup including quantitative immunoglobulins, serum light chain levels, creatinine, troponin, CPK, BNP, NT-proBNP, and β 2-microglobulin were within normal limits. Serum and urine protein electrophoresis did not demonstrate a monoclonal protein. Bone marrow biopsy and echocardiogram were normal. Fat pad aspirate was negative for the presence of amyloid.

Over the next few months, the patient developed additional lesions on the chest but remained asymptomatic. Multiple treatments with intralesional corticosteroids did not significantly improve the appearance of the lesions and were eventually

discontinued. Systemic therapy was considered, but owing to the absence of other organ involvement and the slow progression of skin lesions, a decision was made to follow the patient clinically.

Case Discussion

Primary cutaneous amyloidosis (PCA) is divided into macular, lichenoid, and nodular forms (**Table 1**) [1]. Nodular cutaneous amyloidosis is the least common form of localized cutaneous amyloidosis with 65 cases reported in the literature as of 2013 [5]. Histologically, PCA is characterized by amyloid deposition in the dermis and subcutaneous tissue, usually accompanied by variable degrees of plasma cell infiltrate. In the majority of cases the amyloid consists of light chains that can be of kappa, lambda, or both types [2]. Genetic studies suggest that a clonal expansion of plasma cells produce the amyloid fibrils [3].

In over 60% of reported cases, nodular cutaneous amyloidosis appears in the absence of systemic amyloid deposits, multiple myeloma, or other systemic plasma cell dyscrasia [1]. Localized amyloidosis of the AL type in any organ is believed to represent a localized plasma cell disorder [4]. In cases of NCA without an inciting systemic dyscrasia, a localized amyloid-producing plasmacytoma as the cause of amyloid deposition has been hypothesized but only exceptionally found. Westermark proposed the idea of a "suicide neoplasm" whereby antigenic stimulation produces a clonal plasma cell proliferation producing amyloid that is in turn killed off by the toxic effects of amyloid oligomers [4]. Incipient systemic amyloidosis is not a likely cause of NCA as point estimates for progression to systemic disease are currently reported to be 1-7% [3, 5]. Despite prolonged observation our patient had no evidence of systemic amyloidosis or monoclonal gammopathy.

The noteworthy feature of our patient's course is the multifocal nature of the lesions in non-contiguous skin. Over three years, the patient developed new lesions involving skin distant to the sites of the initial lesions. Nodular cutaneous amyloidosis involving multiple, noncontiguous areas of skin is uncommon in the absence of systemic disease (**Table 2**). In Kalltoft's review of 65 NCA patients, only one patient developed NCA at a cutaneous site distant from the

Table 1. Forms of localized cutaneous amyloid.

	Appearance	Location	Amyloid Type	Pathology	Treatment
Lichen [9]	Pruritic (90%), hyperpigmented papules or plaques	Shins most common, also anterior thighs or forearms	Keratinocyte-derived	Hyperkeratosis, acanthosis, amyloid deposits in upper dermis	Topical or intralesional steroids, Dimethylsulfoxide, etritinate, dermabrasion, laser, UV
Macular [10]	Grey-brown 2-3 mm pruritic papules or confluent plaques with rippled pattern	Back most common, also arms, chest, thighs	Keratinocyte-derived	Same as Lichen	Same as Lichen
Biphasic	Combination of macular and lichen lesions		Keratin		
Nodular [11]	Waxy, nodular lesions or plaques	Trunk, face or extremities	AL	Plasma cell infiltrate, amyloid extends into deep dermis/subcutis and around blood vessels. Positive light chain staining	CO ₂ laser, topical or intralesional steroids

Abbreviations: mm=millimeter, AL=light chain amyloid, UV = ultraviolet, CO₂= carbon dioxide

Table 2. Reported cases of multifocal nodular cutaneous amyloid.

	Age/Sex	Locations	Course	Laboratory findings
Woolens (2001) [1]	36/M	Back lesion, then facial nodule 7 years later	NSD over 15 years	Polyclonal IgG elevation
Criado (2005) [7]	59/M	Face then trunk and arms	NSD over 6 years	None
Feito-Rodriquez (2008) [8]	30/F	Inguinal folds, axillary folds, thighs then back, chest, abdomen, vulva	NSD over 2 years	Polyclonal IgG elevation
Borowicz (2011) [6]	56/M	Right shoulder, then back, chest	NSD over 2 years	None
Kaltoft (2013) [5]	NA	NA	NA	NA
Matsumoto (2016) [current]	59/M	Back then chest	NSD over 2 years	None

Abbreviations: M=male, F=female, NSD=no evidence of systemic amyloidosis

primary lesion [5]. In Woollon’s case series, only one of the 15 patients had clearly described multifocal lesions. Three other patients had “multiple skin lesions” without a clear description of the locations [1]. There are three case reports, which describe disseminated lesions or new lesions spreading to non-contiguous locations over two to 6 years without monoclonal proteins [6, 7, 8].

Conclusion

In conclusion, multifocal NCA is a rare form of cutaneous amyloidosis. Despite having multiple,

noncontiguous lesions, systemic amyloidosis may not be diagnosed in these patients, although regular monitoring of these patients for the development of systemic amyloidosis is prudent. Understanding the mechanisms that stimulate and abolish local monoclonal light chain production in NCA may have broader implications in the field of amyloidogenesis.

References

1. Woollons A, Black MM. Nodular localized primary cutaneous amyloidosis: a long-term follow-up study. *Br J Dermatol*. 2001;145(1):105-109. [PMID: 11453916]
2. Husby G, Sletten K, Blumenkrantz N, Danielsen L. Characterization of an amyloid fibril protein from localized amyloidosis of the skin as lambda immunoglobulin light chains of variable subgroup I (A lambda I). *Clin Exp Immunol*. 1981;45:90-6. [PMID: 6796317]
3. Grunewald K, Sepp N, Weyrer K, Lhotta K, Feichtinger H, Konwalinka G, et al. Gene rearrangement studies in the diagnosis of primary systemic and nodular primary localized cutaneous amyloidosis. *J Invest Dermatol*. 1991;97:693-6. [PMID: 1940440]
4. Westermark P. Localized AL amyloidosis: a suicidal neoplasm? *Upsala journal of medical sciences*. 2012;117:244-50. [PMID: 22335280]
5. Kaltoft B, Schmidt G, Lauritzen AF, Gimsing P. Primary localised cutaneous amyloidosis--a systematic review. *Dan Med J*. 2013;60:A4727. [PMID: 24192243]
6. Borowicz J, Shama L, Miller R. Nodular cutaneous amyloidosis. *Skinmed*. 2011;9:316-8. [PMID: 22165048]
7. Criado PR, Silva CS, Vasconcellos C, Valente NY, Maito JB. Extensive nodular cutaneous amyloidosis: an unusual presentation. *J Eur Acad Dermatol Venereol*. 2005;19:481-3. [PMID: 15987299]
8. Feito-Rodriguez M, Garcia-Macarron J, Pagan-Munoz B, et al. [Disseminated nodular primary localized cutaneous amyloidosis]. *Actas Dermosifiliogr*. 2008;99(8):648-652. [PMID: 19080897]
9. Salim T, Senoi SD, Balachandran C, Mehta VR. Lichen amyloidosis: a study of clinical, histopathologic and immunofluorescence findings in 30 cases. *Indian J Dermatol Venereol Leprol*. 2005;71(3):166-169.
10. Rasi A, Khatami A, Javaheri SM. Macular amyloidosis: an assessment of prevalence, sex, and age. *Int J Dermatol*. 2004;43(12):898-899. [PMID: 15569011]
11. White F, Shvartsbeyn M, Meehan SA, Ramachandraan S. Nodular amyloidosis. *Dermatol Online J*. 2015;21(12). [PMID: 26990345]