

Photo Vignette

Pityrosporum folliculitis in an immunocompetent patient: clinical case description

Ana Carolina Dias Viana de Andrade¹, Matheus Melo Pithon², Olga Maria Oiticica³

Dermatology Online Journal 19 (8): 15

¹ **Baiana School of Medicine and Public Health, Brazil.**

² **School of Dentistry, Federal University of Rio de Janeiro – UFRJ, Brazil.**

³ **Department of Pathology, Federal University of Rio de Janeiro – UFRJ, Brazil.**

Correspondence:

Matheus Melo Pithon
Av. Otávio Santos, 395, sala 705, Centro Odontomédico Dr. Altamirando da Costa Lima
Vitória da Conquista, Bahia, Brazil
CEP: 45020-750
E-mail: matheuspithon@gmail.com

Abstract

The present report concerns *Malassezia*-related pityrosporum folliculitis in a patient without any predisposing factor. Once the diagnosis had been confirmed by histopathologic exam, the patient was treated with oral ketoconazole and selenium sulfide shampoo; complete remission of the clinical condition was obtained. Thus it could be concluded that in spite of being routinely associated with immunosuppression, this condition may be present in an immunocompetent patient.

Key Words: Malassezia; Folliculitis; Ketoconazole.

Introduction

Pityrosporum folliculitis was described in 1969 by Weary & cols and in 1973 Potter & cols recognized the entity clinically and histopathologically [1]. It is an opportunistic fungal infection caused by yeasts of the genus *Malassezia*, which generally prevails in hot and humid climates, and in immunosuppressed individuals [2]. In pityrosporum folliculitis occlusion of the follicle, replication of yeast, and folliculitis occur [3]. Clinically it is characterized by follicular papules and pustules located in the cervical region, trunk, and upper limbs. Yeasts of the genus *Malassezia* are capable of hydrolyzing free fatty acids in triglycerides, which are responsible for the inflammatory reaction in the follicle [1-3].

The following are predisposing factors for the appearance of pityrosporum folliculitis: Antibiotic therapy, AIDS, diabetes mellitus, use of corticosteroids, immunosuppression, and local occlusion, which may be responsible for the imbalance between *Malassezia* sp and its host, predisposing its occurrence. Thus its occurrence in an immunocompetent patient is an atypical situation [4,5].

Therefore, the aim of this report is to relate a clinical case of pityrosporum folliculitis in an immunocompetent adult patient, without any predisposing factor for this affection and to remind clinicians about this entity.

Clinical synopsis

A 33-year-old man related that for the past 3 years he had been developing pruritic, erythematous papules and pustules mainly on the trunk, abdomen, and upper limbs. He underwent treatments for scabies with permethrin and ivermectin without benefit. He was treated for an allergic reaction with topical corticoids and anti-histamines and he obtained slight improvement in itching. When he suspended the medications, there was a recurrence in itching, however, without obtaining any improvement in the clinical condition. He had no previous diseases. The dermatologic exam demonstrated erythematous papules and some pustules on the trunk and abdomen. He also related discomfort owing to the intense itching (Figure 1).

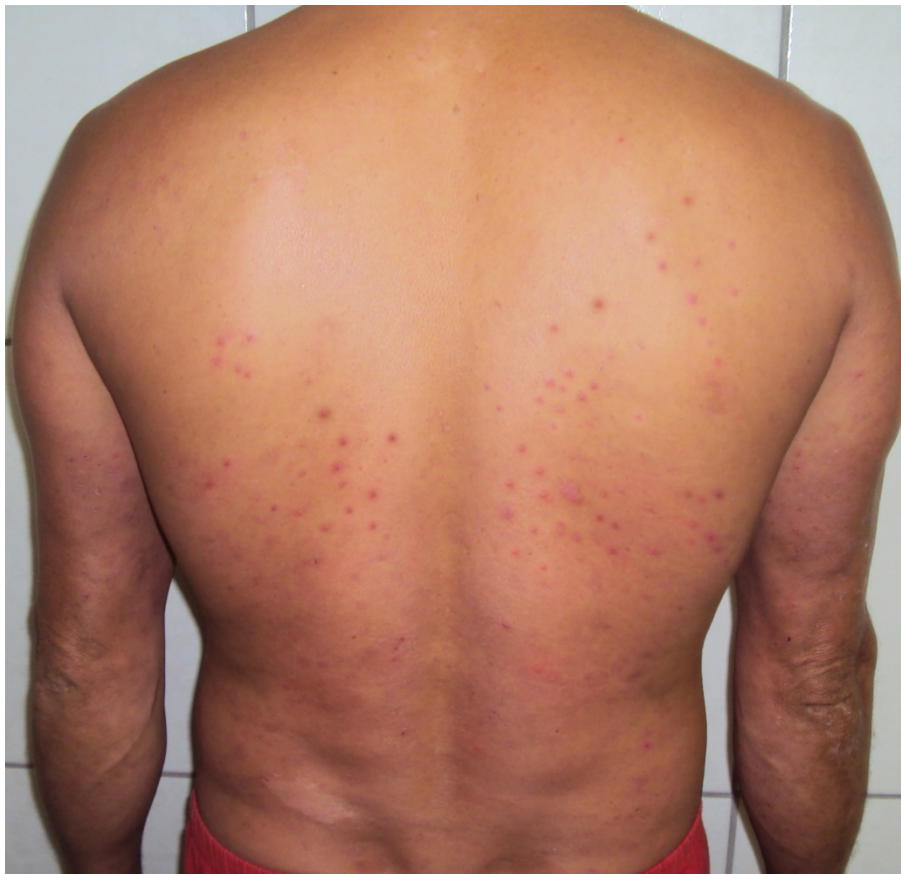

Figure 1. Clinical aspect of the lesion on the dorsum (erythematous papules and some pustules)

Based on the clinical findings and history presented by the patient, the hypotheses of acneiform eruption, bacterial folliculitis, and pityrosporum folliculitis were raised. To further investigate, biopsy of a lesion was performed.

The histopathologic exam exhibits a dermis with a dilated funnel-shaped follicle with disruption of the epithelium. The ostium is filled with inflammatory cells, with predominance of neutrophils (Figure 2). PAS staining reveals rounded elements, compatible with *Malassezia furfur* (*Pityrosporum ovale*). In addition, complete blood count, glucose level, anti HIV 1 and 2, and hepatic and renal function tests were all negative or normal. Abdominal and cervical ultrasound exams were normal.

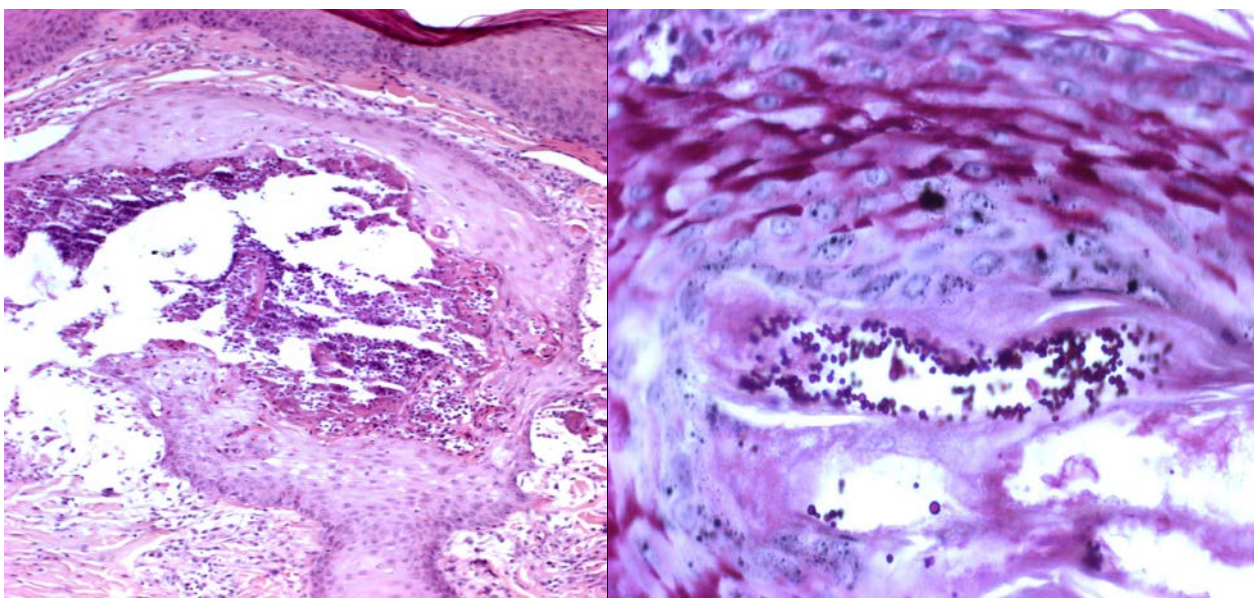


Figure 2 a-b Histopathologic cuts of the skin, exhibiting a dermis with a dilated funnel-shaped follicle with disruption of the epithelium and an ostium filled with inflammatory cells, with predominance of neutrophils. These cells are also seen in the adjacent dermis, next to lymphocytes and histiocytes. PAS staining revealed rounded elements, compatible with *Malassezia furfur* (*Pityrosporum ovale*).

Treatment was started with ketoconazole 200mg /day, loratadine 10mg /day (to relieve itching), and 2.5% selenium sulfide shampoo, resulting in complete resolution after 30 days. The patient is using the shampoo 3 times per week as a maintenance procedure.

Discussion

Although yeasts of the genus *Malassezia* spp. form part of the normal flora of the skin, in some situations the organisms may cause or aggravate diseases, including pityriasis versicolor, pityrosporum folliculitis, and seborrheic dermatitis [6,7]. In immunocompromised patients (such as in AIDS, Hodgkin's disease, chronic kidney failure, transplant patients using immunosuppressants, chronic use of steroids), *Malassezia* spp. is associated with a series of conditions as well as systemic diseases, such as fungemia related to catheter, folliculitis, and a variety of invasive infections [8-10]. As regards pityrosporum folliculitis, it is an opportunist disease, affects individuals in the age-range of 24 and 35 years, and is more frequent in tropical countries owing to heat and humidity [1,10]. Factors such as the prolonged use of antibiotics and immunodepression favor the imbalance between *Malassezia* sp. and the host, resulting in predisposition to disease.

All these conditions lead to the growth of fungus in the follicle, stimulating the production of scales and facilitating further obstruction. The fungus is capable of hydrolyzing free fatty acids in triglycerides and these lead to the inflammation in the follicle [6].

The clinical lesions are of the papule-pustular type. Uncommon forms such as nodular and cystic lesions are possible.

The diagnosis is based on direct microscopic exam, showing yeasts forms, or by means of histopathologic exam, showing suppurative folliculitis with the presence of intrafollicular yeasts.

In the case of this patient, an atypical situation was observed because he did not present any predisposing factor for the appearance of this widespread condition. The attention of dermatologists should be drawn to the fact that pityrosporum folliculitis may be an under-diagnosed form of folliculitis and it may be confounded with other dermatoses, including acne. Although pityrosporum folliculitis is associated with immunosuppression, it may occur in an immunocompetent patient.

References

1. Yaffee HS. Pityrosporum folliculitis. *Arch Dermatol* 1973;108:277. [PMID: 4724136]
2. Ayers K, Sweeney SM, Wiss K. Pityrosporum folliculitis: diagnosis and management in 6 female adolescents with acne vulgaris. *Arch Pediatr Adolesc Med* 2005;159:64-67. [PMID:15630060]
3. Alves EV, Martins JE, Ribeiro EB, Sotto MN. Pityrosporum folliculitis: renal transplantation case report. *J Dermatol* 2000;27:49-51. [PMID:10692826]
4. Parsad D, Saini R, Negi KS. Short-term treatment of pityrosporum folliculitis: a double blind placebo-controlled study. *J Eur Acad Dermatol Venereol* 1998;11:188-190. [PMID:9784054]
5. Parsad D, Saini R, Negi KS. Short term treatment of pityrosporum folliculitis with itraconazole. *Indian J Dermatol Venereol Leprol* 1999;65:122-123. [PMID:20921630]
6. Gaitanis G, Magiatis P, Hantschke M, Bassukas ID, Velegraki A. The *Malassezia* genus in skin and systemic diseases. *Clin Microbiol Rev* 2012;25:106-141. [PMID:22232373]
7. Lee YW, Kim SM, Oh BH, Lim SH, Choe YB, Ahn KJ. Isolation of 19 strains of *Malassezia dermatis* from healthy human skin in Korea. *J Dermatol* 2008;35:772-777. [PMID:19239557]
8. Mota R, Reifenberger J, Homey B, Bruch-Gerharz D. *Malassezia* folliculitis in an immunocompromised patient. *Hautarzt* 2011;62:725-727. [PMID:21915732]
9. Faergemann J, Johansson S, Back O, Scheynius A. An immunologic and cultural study of Pityrosporum folliculitis. *J Am Acad Dermatol* 1986;14:429-433.
10. Jillson OF. Pityrosporum folliculitis. *Cutis* 1985;35:226-227. [PMID:3958257]