

Photo vignette

Familial benign pemphigus atypical localization

Maria Veronica Reyes, Sabina Halac, Claudio Mainardi, María Kurpis, Alejandro Ruiz Lascano

Dermatology Online Journal 22 (4): 12

Hospital Privado de Córdoba, Argentina

Correspondence:

Maria Veronica Reyes
Department of Dermatology
Hospital Privado de Córdoba
mveroreyes@hotmail.com

Abstract

We present an atypical case of familial benign pemphigus (Hailey-Hailey disease), which presented as crusted, annular plaques limited to the back without intertriginous involvement. We could not find in the literature another patient with plaques located solely on the back without a prior history of classical disease.

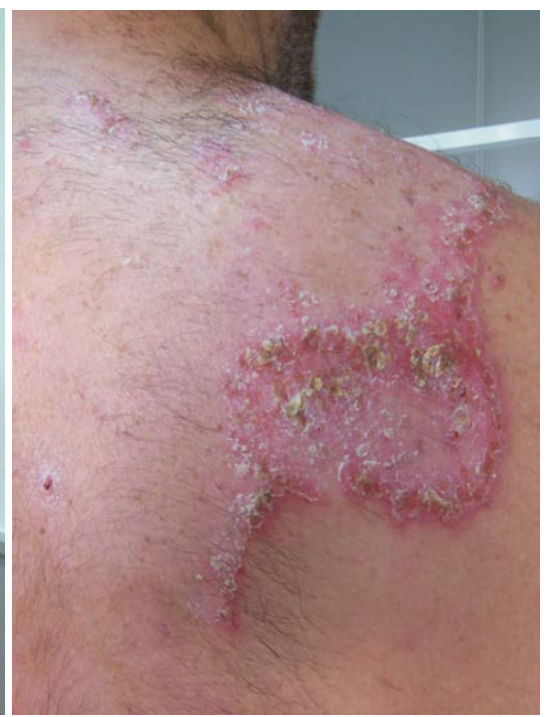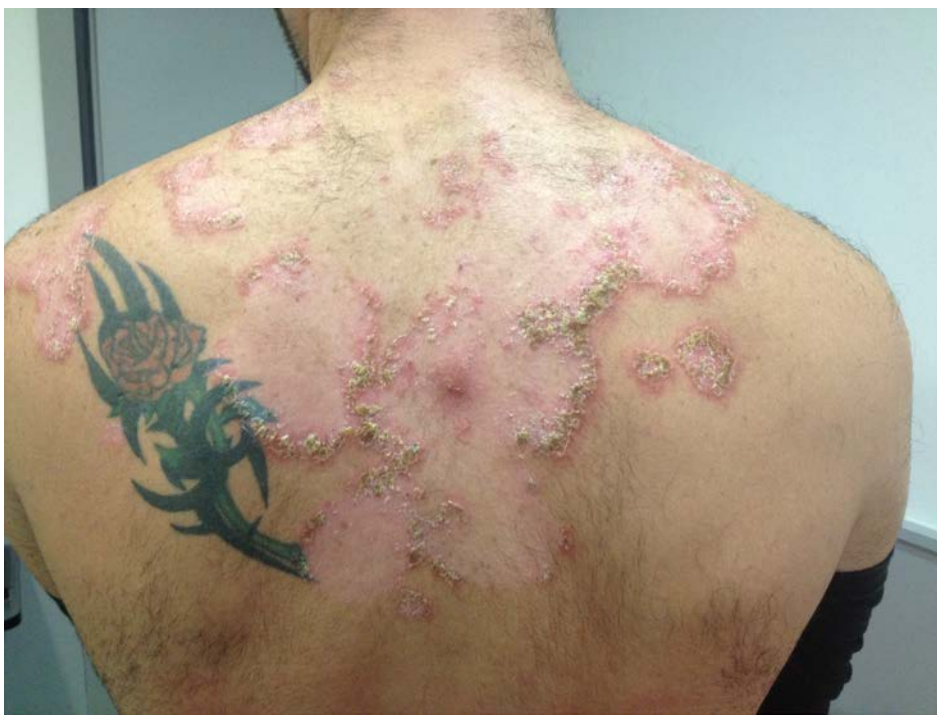Introduction

Hailey-Hailey disease (HHD), also known as benign chronic familial pemphigus, was first described by the Hailey brothers in 1939 [1]. It is an autosomal dominant disease characterized by recurrent, fragile, vesicles and erosions in intertriginous areas (axillary folds, groin, submammary region, and neck folds). Skin lesions most commonly present between the second and the fourth decades of life and can be pruritic, painful, and malodorous; recurrent lesions may lead to restricted morbidity [2]. Mutations in the ATP2C1 gene, which encodes a Golgi apparatus Ca²⁺-ATPase protein, lead to inappropriate processing of desmosomal proteins. This results in deficient cell adhesion and consequent acantholysis occurring in intertriginous sites prone to heat and friction [3].

Case synopsis

A 35-year-old man presented with a 10-year history of crusted annular plaques on the back. The lesions were stinging, burning and, sometimes, pruritic. The patient denied modifying factors, such as seasonal variation, heat, friction, or sweating. Similar lesions had never occurred in axillae, inframammary or inguinal folds, or oral mucosa. Prior treatments included topical glucocorticoids, which provided minimal relief. His sister had crusted erosions in intertriginous areas. Her illness was recently diagnosed as HHD in another hospital.

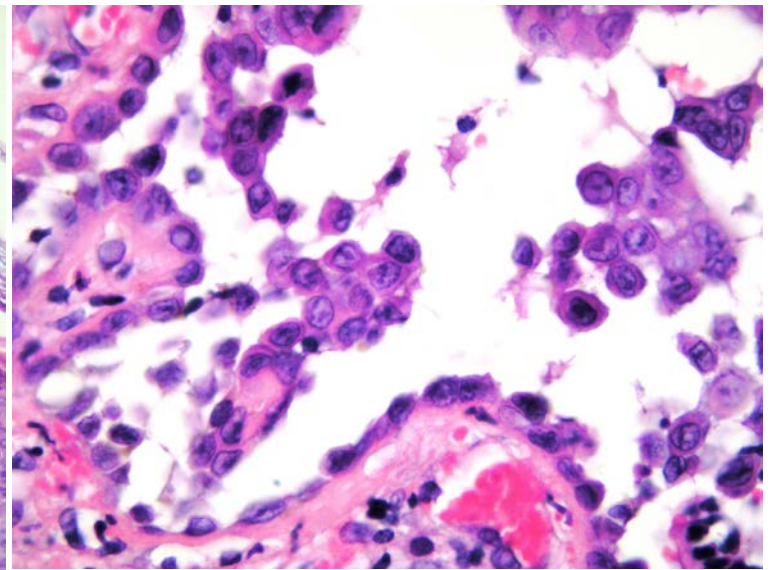
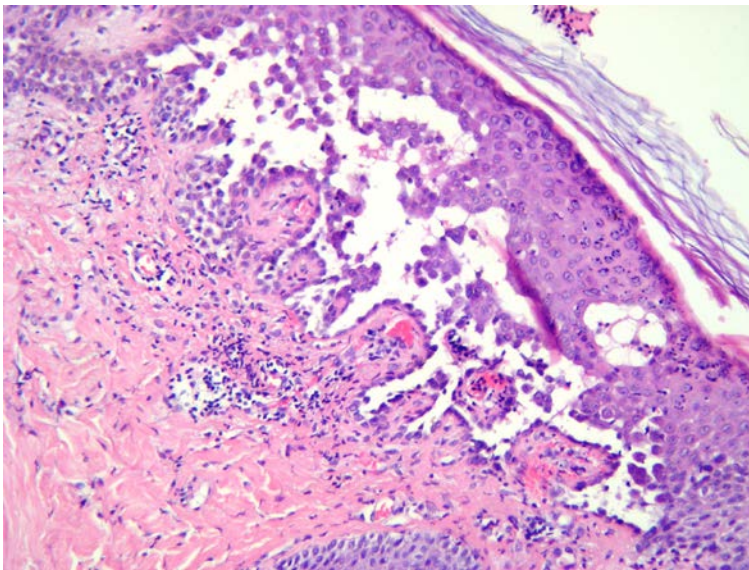
Upon physical examination, exudative, eroded, erythematous plaques and patches with crusts were present on the back. They had a symmetrical distribution and were well demarcated and annular shaped. The lesions were migratory and had centrifugal enlargement (Figures 1, 2). There were neither mucosal lesions, nor nail abnormalities such as longitudinal white bands.



Figures 1 and 2.

A complete blood count and comprehensive metabolic panel were normal. AntiRo, antiLa and antinuclear antibodies were negative. VDRL and ELISA test for HIV were not reactive. Mycological and bacteriological direct examination and culture were negative.

Histopathologic examination showed suprabasal acantholysis and crusting. Direct immunofluorescence tests were negative (Figures 3, 4).



Figures 3 and 4.

Discussion

Approximately two-thirds of patients have a positive family history. More frequently, the disease becomes apparent during puberty and intertriginous areas are preferentially affected, including axillary, inguinal, and neck folds. Mucous membranes are far less affected. A few cases of mucosal lesions in the mouth, the labia major, and the esophagus have been reported [4]. Longitudinal white lines on the nails are frequently seen. Bacterial and fungal superinfection, maceration, and frequent sweating (axillary and inguinal hyperhidrosis) are considered to be important aggravating factors [5]. A study of 58 patients with HHD in the United Kingdom indicated that predilection sites were flexure areas, including the groin, axilla, perineum, inframammary region, umbilicus, and retroauricular region, in descending order, as well as neck/nape, shoulders, chest, arms, and back [2]. Lesions are typically symmetric, although postzygotic loss of gene function can result in asymmetric type 1 or segmental type 2 disease [6].

In the literature, we found three patients with HHD in atypical locations without skin fold involvement. One patient had HHD lesions confined to the anterior upper body [7] and another one had relapsing, flaccid vesicles and erosions limited to the upper chest, anterior aspect of the neck, and anterior aspects of the arms [8]. The third patient was a 25-year-old woman who presented with erythematous crusted erosions on left malar area persistent for 12 years [9].

Involved skin displays widespread partial loss of cohesion (keratinocytes may still be linked together by adherens junctions) between suprabasal keratinocytes, with an appearance likened to a dilapidated brick wall. Clusters of loosely coherent cells float in suprabasal clefts or bullae. Necrotic keratinocytes are uncommon and direct immunofluorescence tests are negative [10].

Complications of HHD include colonization and secondary superinfection with bacterial, fungal, or viral microorganisms, including eczema herpeticum; rare instances of squamous-cell carcinoma have been noted. In general, patients experience a relapsing and remitting disease course, with a substantial impact on their quality of life [11].

Therapeutic options for HHD are many and vary in their approach to this troubling disease. Currently, there is no known cure and there are almost no treatments that provide a long-lasting positive therapeutic impact. Topical and systemic antimicrobials along with topical, intralesional, and oral glucocorticoids are routinely used to control symptoms. Anecdotal drug therapies have also been used to control the underlying inflammatory immune response associated with HHD [12]. These therapies include topical immunomodulators as pimecrolimus or tacrolimus, topical tacalcitol, topical and oral cyclosporin, intradermal botulinum toxin type A, dapsone, oral isotretinoin or alitretinoin with narrowband UVB, 5 aminolevulinic acid photodynamic therapy, alefacept, and thalidomide. In some patients, disease can be recalcitrant to medical treatments and more invasive approaches may be required, such as surgical excision of lesions or carbon dioxide laser ablation [11-15].

References

1. Hailey H, Hailey H. Familial benign chronic pemphigus. *Arch Dermatol Syph.* 1939;39: 679-85.
2. Burge SM. Hailey-Hailey disease: the clinical features, response to treatment and prognosis. *Br J Dermatol* 1992; 126:275. [PMID: 1554604]
3. D'Errico A, Bonciani D et al. Hailey-Hailey disease treated with methotrexate. *J Dermatol Case Rep.* 2012; 6: 49-51.[PMID: 22826719]
4. Dobson-Stone C, Fairclough R, Dunne E, Brown J, et al. Hailey-Hailey disease: molecular and clinical characterization of novel mutations in the ATP2C1 gene. *J Invest Dermatol.* 2002; 118:338-43. [PMID: 11841554]
5. Hamada T, Fukuda S, Sakaguchi S, Yasumoto S, Kim SC, Hashimoto T. Molecular and clinical characterization in Japanese and Korean patients with Hailey-Hailey disease: six new mutations in the ATP2C1 gene. *J Dermatol Sci* 2008; 51: 31-6. [PMID: 18372165]
6. Bittar M, Happle R. 'Atypical' cases of hailey hailey disease may represent typical examples of a type 2 segmental manifestation. *Dermatology* 2005; 210: 182-3. [PMID: 15785043]
7. Saied NK, et al. Atypical familial benign chronic pemphigus. *Cutis* 1981; 27: 666. [PMID: 7238118]
8. Hunt R, O'Reilly K, Ralston J, Kamino H, Shupack JL. Familial benign chronic pemphigus (Hailey-Hailey disease). *Dermatol Online J.* 2010; 15; 16(11):14. [PMID: 21163165]
9. Dipti D, Anupam D, Ramesh Ch, Debabrata B. Hailey Hailey disease: A Presentation out of the Ordinary. *J Turk Acad Dermatol* 2014; 8(4): 1484c7.
10. Burge S, Hovnanian A. Acantholytic Disorders of the Skin. In: Fitzpatrick's Dermatology in General Medicine 8th edition. 2008: 559.
11. Vasudevan B, Verma R, Badwal S, et al. Hailey-Hailey disease with skin lesions at unusual sites and a good response to acitretin. *Indian J Dermatol Venereol Leprol.* 2015; 81 (1):88-91. [PMID: 25566918]
12. Tchernev G, Cardoso JC. Familial benign chronic pemphigus (Hailey-Hailey Disease): use of topical immunomodulators as a modern treatment option. *Rev Med Chil.* 2011; 139(5): 633-7. [PMID: 22051715]
13. Falto-Aizpurua LA, Griffith RD, Yazdani Abyaneh MA, Nouri K. Laser therapy for the treatment of Hailey-Hailey disease: a systematic review with focus on carbon dioxide laser resurfacing. *J Eur Acad Dermatol Venereol.* 2015; 29(6):1045-52. [PMID: 25418614]
14. Vanderbeck KA, Giroux L, Murugan NJ, Karbowski LM. Combined therapeutic use of oral alitretinoin and narrowband ultraviolet-B therapy in the treatment of hailey-hailey disease. *Dermatol Reports.* 2014 3; 6(1):5604. [PMID: 25386331]
15. Ruiz Rodriguez R, et al. Photodynamic therapy with 5 aminolevulinic acid for recalcitrant familial benign pemphigus (HaileyHailey disease). *J Am Acad Dermatol* 2002; 47: 740. [PMID: 12399767]