

Nasolabial flap – alternative uses for a classic but versatile technique

Fernando Mota, Miguel Horta, Monica Caetano, Virgilio Costa, Manuela Selores

Affiliations: Department of Dermatology, Centro Hospitalar do Porto, Portugal

Corresponding Author: Fernando Mota, Rua Central, 180, Branzelo, 4515-498 Melres, Portugal, Tel: 351914529411, Email: fernandojrmota@gmail.com

Abstract

The nasolabial flap is one of the most ancient techniques used in orofacial surgery. The authors report two cases of patients with skin cancer treated surgically with variations of the classic nasolabial flap by transposition (bilateral and folded) that highlight the broad applicability of this technique.

Keywords: nasolabial flap, dermatologic surgery, oncology

Introduction

In dermatologic surgery, we are often confronted with the need to prioritize the removal of the skin cancers with adequate margins, relegating the cosmetic aspect of surgery to a secondary plan. However, whenever possible, we try to complete both objectives. The routine use of grafts and flaps have increased the possibilities for surgeons to reconstruct defects, improving outcomes and the quality of life in cancer patients. A great number of cutaneous neoplasias are located on the face. The nasolabial flap (NLF) is one of the most ancient techniques used in orofacial surgery [1]. It is a very versatile flap, with large applicability, which can be used to reconstruct defects in the nose (tip, dorsum, alae), lips, or even in the oral cavity [2-5]. Its usefulness is related not only to the anatomic areas that can be reconstructed, but also to the fact that it can be performed with relative ease with local anesthesia in co-morbid patients. The face provides good vascularization allowing for the viability of greater extension flaps. The use of the NLF in the reconstruction of nasal defects is intended to

optimize cosmetic results as the color and texture of the cheek are similar to those of the nose and the reproduction of the natural crease at the nasolabial fold results in minimal donor-site deformity [3, 4].

We report two cases of patients with skin cancer treated surgically with variations of the classic NLF by transposition (bilateral and folded NLF) that highlight the broad applicability of this technique.

Case Synopsis

The first case is of a male patient, 65-years-old, with a history of renal transplant. He was referred owing to a growing tumor located on the nose, with 4 months of evolution. Upon physical examination, he had a vegetating ulcerated tumor occupying the entirety of the nasal dorsum, extending to both nasal alae (**Figure 1a**).

A skin biopsy revealed an invasive squamous cell carcinoma. The patient was treated with surgical excision of the tumor (clear margins), followed by the reconstruction of the defect using a bilateral NLF (**Figure 1b**). He had a very good result, with preservation of the flaps and very satisfactory cosmetic and functional result (**Figure 1c-e**). The patient remains disease-free after 12 months of follow-up.

The second case is of a female patient, 71 years old, with no relevant past medical history. She was referred owing to an ulcerated cutaneous tumor of the right nasal ala with 8 months of evolution. Upon physical examination, we observed an ulcerated tumor infiltrating the full thickness of the soft tissue

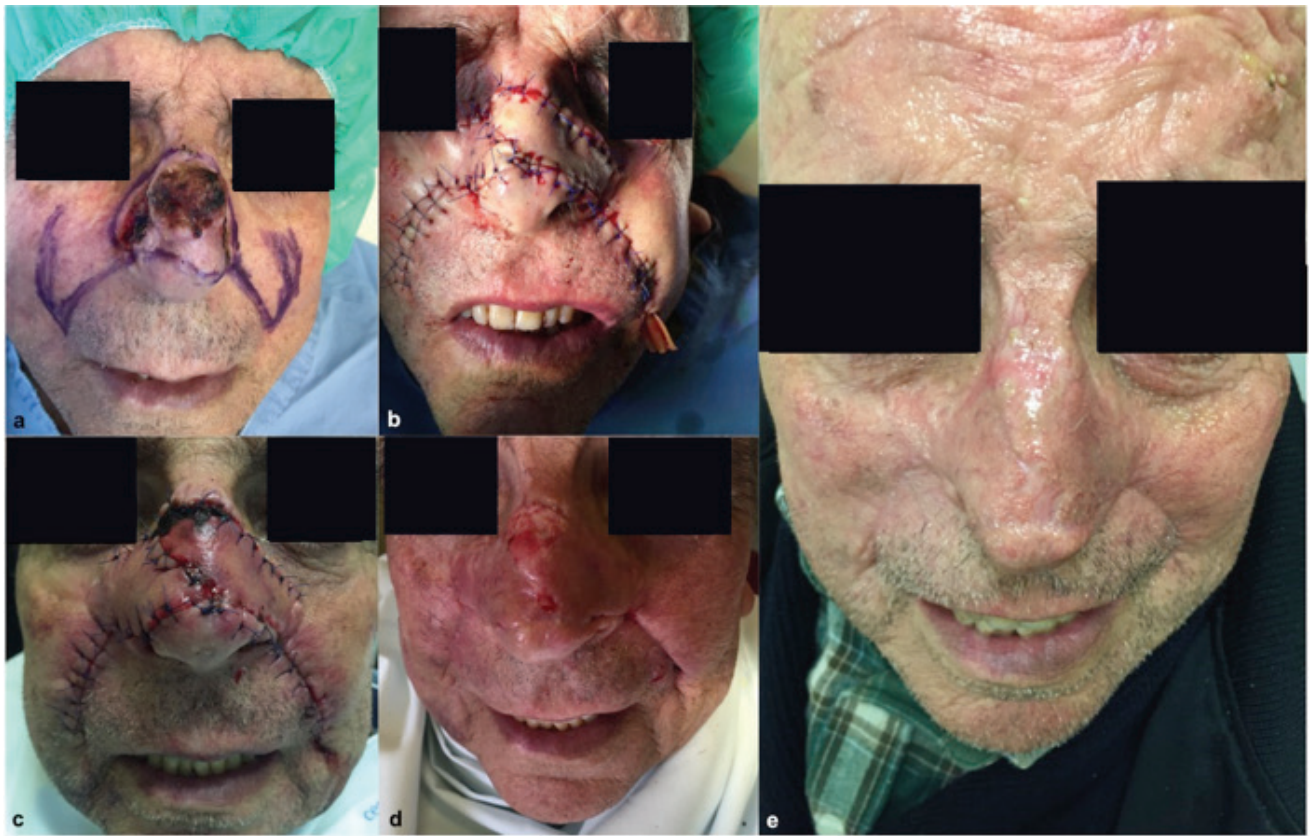


Figure 1. First patient, treated with bilateral nasolabial flap; (a) pre-operative aspect of the lesion, involving the nasal dorsum and alae; (b) immediate post-operative aspect; (c) after 6 days of follow-up, notice the small area of necrosis ate the top of the dorsum; (d) after 13 days of follow-up; (e) after 6 months of follow-up.

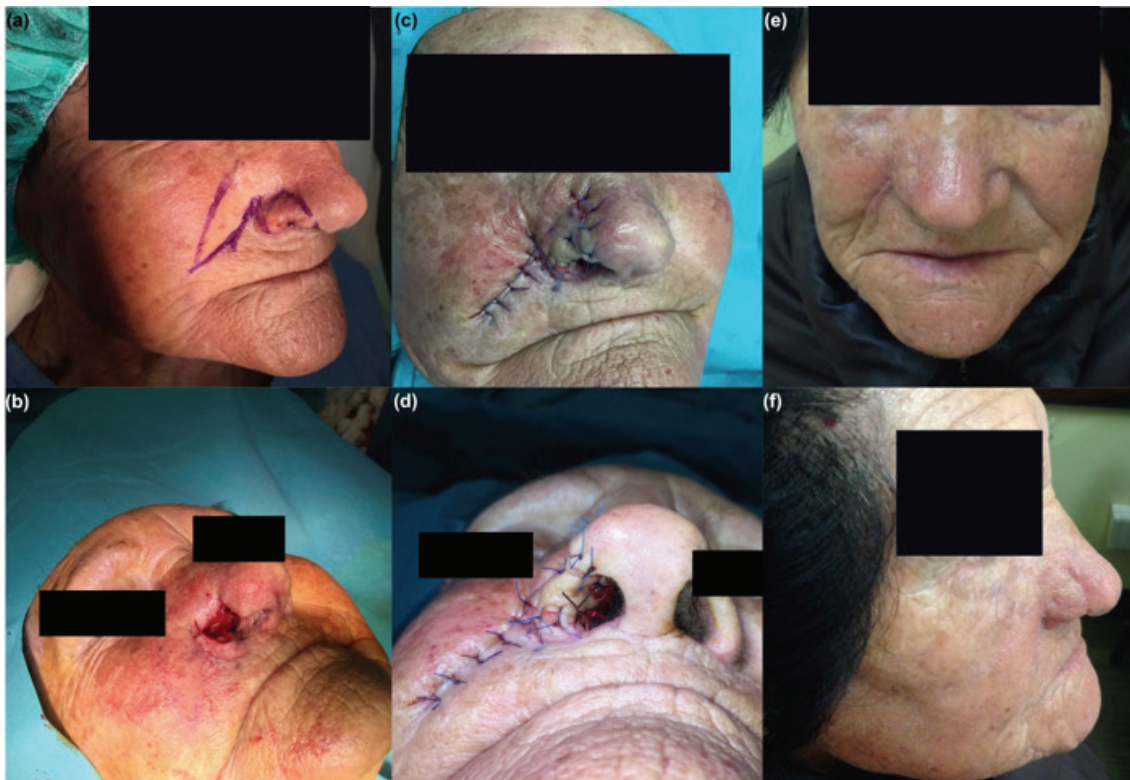


Figure 2. Second patient, treated with folded nasolabial flap; (a) pre-operative aspect of the lesion of the right nasal ala; (b) defect after excision; (c) immediate post-operative aspect, the folded flap was sutured in the center to avoid contraction due to cicatrization; (d) detail of the internal (absorbable) suture at the end of the folded flap; (e) after 4 months of follow-up (frontal view); (f) after 4 months of follow-up (lateral view).

of the right nasal ala (without cartilage involvement), (**Figure 2a**). A skin biopsy revealed an ulcerated basal cell carcinoma. The patient was treated with surgical excision of the skin cancer (clear margins) followed by the reconstruction of the nasal ala using a folded NLF (**Figure 2b-d**). No cartilage grafting was used. She had a very good result, with function preservation and a very satisfactory cosmetic result (**Figure 2e, f**). The patient remains disease-free after six months of follow-up.

Case Discussion

These cases illustrate alternative, non-classic applications of the NLF. With slight changes based on the defect characteristics, large defects involving the totality of the nasal dorsum and alae, or a full thickness defect of the nasal ala (without cartilage commitment) can be reconstructed.

Conclusion

The authors present here alternative uses for a flap once considered only for the reconstruction of partial alar and sidewall defects.

References

1. Gewirtz HS, Eilber FR, Zarem HA. Use of the nasolabial flap for reconstruction of the floor of the mouth. *Am J Surg*. 1978;136(4):508-11. [PMID: 360855].
2. Fujimori R. "Gate flap" for the total reconstruction of the lower lip. *Br J Plast Surg*. 1980;33(3):340-5. [PMID: 7426811].
3. Cameron RR, LathamWD, Dowling JA. Reconstructions of the nose and upper lip with nasolabial flaps. *Plast Reconstr Surg*. 1973;52(2): 145-150. [PMID: 4579000].
4. McLaren LR. Nasolabial flap repair for alar margin defects. *Br J Plast Surg*. 1963;16:234-238. [PMID: 14042751].
5. Rohrich RJ, Conrad MH. The superiorly based nasolabial flap for simultaneous alar and cheek reconstruction. *Plast Reconstr Surg*. 2001;108(6):1727-1730. [PMID: 11711955].