

Erythrodermic Darier disease associated with metastatic lung adenocarcinoma

Aleksi J Hendricks¹ BS, Melody Maarouf¹ MD¹, Brandy W Mills² MD, Spencer T Bertoch³ MD, Tracy L Davis⁴ MD PhD, Vivian Y Shi⁵ MD

Affiliations: ¹University of Arizona College of Medicine, Tucson, Arizona, USA, ²Texas Tech Health Sciences Center El Paso Paul L. Foster School of Medicine, El Paso, Texas, USA, ³Division of Dermatology, University of Arizona Department of Medicine, Tucson, Arizona, USA, ⁴DermPath Diagnostics, Tucson, Arizona, USA, ⁵Department of Dermatology, University of Arkansas for Medical Sciences, Little Rock, Arkansas, USA

Corresponding Author: Vivian Y Shi MD, Department of Dermatology, University of Arkansas for Medical Sciences, 4301 West Markham Street #576, Little Rock, AR 72205, Tel: 501-526-6994, Email: vivian.shi.publications@gmail.com

Abstract

We present a patient with erythrodermic Darier disease occurring in temporal association with diagnosis of metastatic lung adenocarcinoma. The patient presented with eroded and crusted keratotic papules and plaques over greater than 90% body surface area with extensive secondary impetiginization. Given a longstanding history of pruritic eruption, this presentation represents a paraneoplastic flare of an underlying genodermatosis. Near total resolution was achieved with chemotherapy and topical corticosteroids.

Keywords: Darier disease, paraneoplastic, lung adenocarcinoma, acantholysis, dyskeratosis

Introduction

Darier disease (DD) is a rare autosomal dominant disorder of keratinization attributed to a loss-of-function mutation affecting the sarcoendoplasmic reticulum calcium ATPase type 2 (SERCA2), [1]. Abnormal keratinization results in the clinical manifestations of greasy, keratotic papules and plaques in a seborrheic distribution, along with characteristic nail and mucosal involvement [2]. Disease onset is typically around puberty and follows a chronic course, with exacerbations related to heat, sun exposure, friction, and infection [2].

We present a patient with erythrodermic DD in the context of advanced lung adenocarcinoma with pleural metastases. Previous reports of paraneoplastic DD are exceedingly rare and have been documented only as acquired conditions in association with gastric adenocarcinoma [3] and undifferentiated metastatic carcinoma [4]. This case report describes a paraneoplastic erythrodermic flare of underlying DD, with improvement of the patient's dermatologic condition in the course of chemotherapy and topical corticosteroid treatment.

Case Synopsis

A 71-year-old woman with recently diagnosed stage 4 lung adenocarcinoma presented to our dermatology clinic with diffuse eroded and crusted keratotic papules and plaques on the trunk and extremities (**Figure 1**). Greater than 90% body surface area was involved with facial sparing and widespread secondary impetiginization. She reported a 50-year history of pruritic rash with intermittent flares following upper respiratory infections, which had been stable and well-controlled for many years prior to her lung cancer diagnosis. Following her lung cancer diagnosis, however, the rash progressively worsened. Initial dermatologic treatment with topical triamcinolone ointment, methylprednisolone dose pack, and a 7-day course of cephalexin yielded minimal improvement. Subsequent punch biopsy revealed

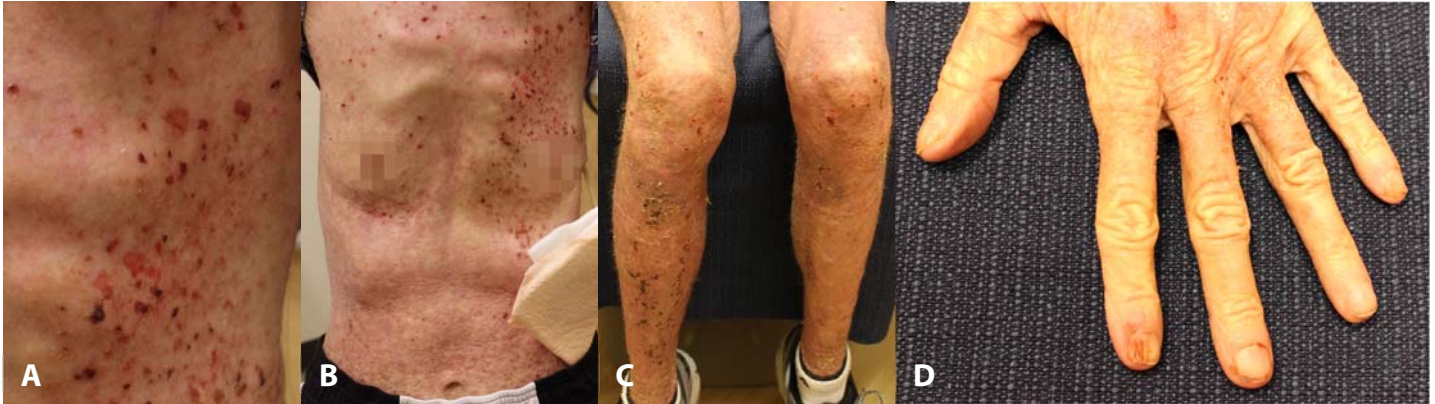

Figure 1. Clinical Findings. **A)** Widespread eroded and excoriated hyperkeratotic papules and plaques on a diffuse erythematous background covering over 90% body surface area, **B)** involving the trunk, and **C)** bilateral upper and lower extremities with lichenified and leathery skin texture. **D)** Nail findings consist of longitudinal erythronychia and distal v-shaped notching.

suprabasilar acantholytic dermatitis with corps ronds and corps grains (**Figure 2**) consistent with a diagnosis of DD. Initiation of chemotherapy with four cycles of pemetrexed, carboplatin, and pembrolizumab along with Unna wrap and topical triamcinolone led to near complete resolution of rash and symptoms within 8 weeks.

Case Discussion

Although two previous case reports have described acquired DD as a paraneoplastic phenomenon in the settings of gastric adenocarcinoma and undifferentiated metastatic carcinoma [3, 4], this case is unique in presenting erythrodermic DD in association with metastatic lung adenocarcinoma (**Table 1**). The patient's longstanding intermittent cutaneous eruption on the trunk and extremities likely represented undiagnosed DD that manifested as erythroderma related to the underlying malignancy. The exacerbation of cutaneous symptoms resolved quickly with initiation of chemotherapeutic treatment, confirming this erythrodermic presentation as a paraneoplastic flare. Post-chemotherapy PET/CT revealed decrease in size of the primary lung mass and near total resolution of nodular pleural metastases, indicating that improvement in dermatologic manifestations mirrored behavior of the internal neoplasm.

Management of DD involves use of topical corticosteroids and topical or systemic retinoids according to disease severity, with antibiotic use as

needed for impetiginization [2]. In this case, topical triamcinolone in conjunction with chemotherapy proved sufficient for control of the patient's cutaneous symptoms. Consideration of systemic retinoids would have been warranted had the patient not cleared with topical therapy. Antibiotic use is of paramount importance in cases of paraneoplastic DD, as existing immunocompromise renders these patients especially susceptible to secondary impetiginization.

The mechanisms through which DD and malignancy are related remain poorly understood. Authors of previous case reports have hypothesized that tumor-derived signaling molecules and growth factors such

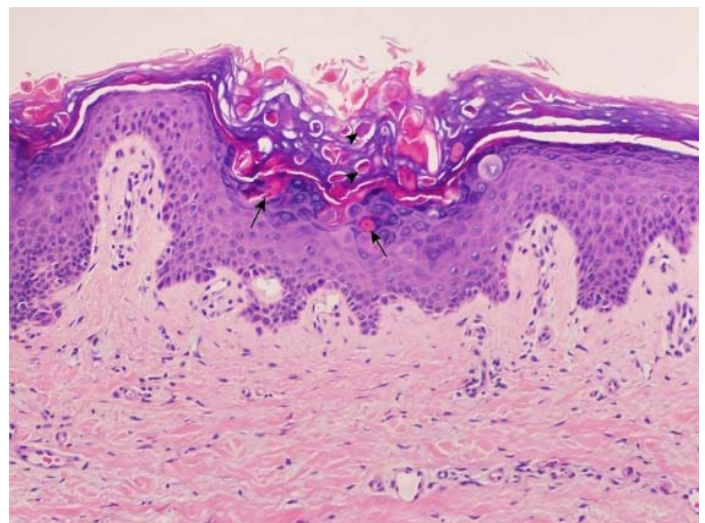


Figure 2. Histopathological Findings. A punch biopsy from the left lateral thigh demonstrates suprabasilar acantholysis with corps ronds (arrows) and corps grains (arrowheads), consistent with Darier disease. H&E, 10x.

Table 1. Presentations of Darier disease associated with internal malignancy.

Reference (Year)	Patient demographics	Associated malignancy	Dermatologic history	Biopsy findings	Therapeutic approach and clinical course
Gangopadhyay et al. (2015), [3]	62 M	Gastric adenocarcinoma	2-month history of numerous hyperpigmented warty papules over the face, neck, trunk and scalp	Suprabasal acantholytic cleft and dyskeratotic cells like corps ronds and grains	Excision of gastric tumor with subsequent significant reduction in papules
Dortzbach et al. (2003), [4]	74 M	Undifferentiated metastatic carcinoma (primary unknown)	Sudden onset of diffuse red rash, scaly hyperpigmentation and skin thickening with development of verrucous papules	Epidermal acanthosis and papillomatosis; suprabasilar acantholysis, corps ronds and grains	TCS without improvement; etretinate 25mg daily without improvement; methotrexate 10-20mg weekly without improvement
Present case	71 F	Metastatic lung adenocarcinoma	>90% BSA with diffuse eroded and crusted keratotic papules and plaques with widespread secondary impetiginization 50-year history of pruritic rash with infrequent flares	Suprabasilar acantholytic dermatitis with corps ronds and corps grains	Chemotherapy (4 cycles of pemetrexed, carboplatin and pembrolizumab) plus Unna wrap and topical TAC with near complete resolution within 8 weeks

BSA – body surface area; TAC – triamcinolone; TCS – topical corticosteroids.

as TGF β interfere with calcium homeostasis and intracellular trafficking of cell adhesion proteins [3, 4], resulting in dyskeratosis characteristic of DD. In addition to causing DD, mutations in the *ATP2A2* gene encoding SERCA2 have been associated with lung and colon cancer [5], suggesting a possible predisposition to malignancy in DD patients related to calcium dysregulation. Further investigation of the link between calcium signaling and carcinogenesis may help to elucidate the underlying mechanisms at work in paraneoplastic presentations of DD.

Conclusion

This case report documents an erythrodermic flare of underlying Darier disease occurring in temporal association with advanced lung adenocarcinoma. The patient's cutaneous symptoms improved dramatically with initiation of chemotherapy and with topical corticosteroid treatment, mirroring

reduction in size of the primary lung tumor and pleural metastases. Although this case represents a paraneoplastic exacerbation of pre-existing Darier disease with an erythrodermic flare, two prior reports describe new-onset Darier disease associated with gastric adenocarcinoma and undifferentiated metastatic carcinoma. The relationship between internal malignancy and Darier disease remains incompletely understood and warrants further investigation, although involvement of dysregulated calcium signaling has been hypothesized.

Potential conflicts of interest

Vivian Shi is a stock shareholder of Learn Health, and has served as a consultant or investigator for or has received research funding from Sanofi/Regeneron, Eli Lilly, Dermira, Novartis, AbbVie, SUN Pharma, Pfizer, Leo, Menlo Therapeutics, Altus Lab, Burt's Bees, GpSkin, and Skin Actives Scientific. The remaining authors declare no conflicts of interest.

References

1. Sakuntabhai A, Ruiz-Perez V, Carter S, et al. Mutations in ATP2A2, encoding a Ca²⁺ pump, cause Darier disease. *Nat Genet.* 1999;21:271-7. [PMID: 10080178].
2. Cooper SM, Burge SM. Darier's disease: epidemiology, pathophysiology, and management. *Am J Clin Dermatol.* 2003;4:97-105. [PMID: 12553850].
3. Gangopadhyay A, Ghosh A, Biswas S, et al. Darier's disease in gastric malignancy: an unusual paraneoplastic phenomenon. *Indian J Dermatol.* 2015;60:423. [PMID: 26288448].
4. Dortzbach KL, Seykora JT, Werth VP. Darier's disease associated with an underlying neoplasm in combination with a nodular fibroproliferative disease. *J Am Acad Dermatol.* 2003;49:S237-9. [PMID: 14576639].
5. Korosec B, Glavac D, Rott T, Ravnik-Glavac M. Alterations in the ATP2A2 gene in correlation with colon and lung cancer. *Cancer Genet Cytogenet.* 2006;171:105-11. [PMID: 17116488].