

# Pruritic papules after induction chemotherapy with daunorubicin and cytarabine

Elanee Simmons<sup>1</sup> BS, Soraya Foutouhi<sup>1</sup> MD PhD, Danielle M Tartar<sup>1</sup> MD PhD, Maija Kiuru<sup>1,2</sup> MD PhD

Affiliations: <sup>1</sup>Department of Dermatology, University of California Davis Health, Sacramento, California, USA, <sup>2</sup>Department of Pathology and Laboratory Medicine, University of California Davis Health, Sacramento, California, USA

Corresponding Author: Maija Kiuru MD PhD, Department of Dermatology, University of California Davis Health, 3301 C Street, Suite 1400, Sacramento, CA 95816, Tel: 916-551-2686, Email: [mkiuru@ucdavis.edu](mailto:mkiuru@ucdavis.edu)

## Abstract

We present a 65-year-old woman who developed a diffuse pruritic papular eruption after receiving induction chemotherapy with daunorubicin and cytarabine for newly diagnosed acute myelomonocytic leukemia. The rash improved clinically with triamcinolone treatment and chemotherapy was allowed to continue. This case adds to the growing literature of transient acantholytic dermatosis development in the setting of anti-cancer therapy and emphasizes the importance of clinicopathologic correlation in cutaneous eruptions in cancer patients.

*Keywords: acantholytic dermatosis, Grover disease, acute myeloid leukemia, acute myelomonocytic, induction chemotherapy, daunorubicin, cytarabine, papular, pruritic, transient*

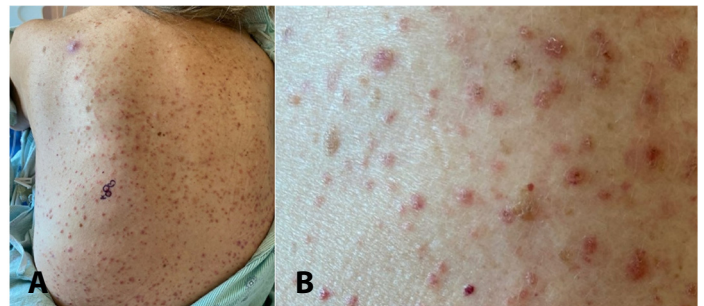
## Introduction

Transient acantholytic dermatosis (Grover disease) describes an acquired transient or persistent pruritic, crusted, skin-colored or erythematous papular and/or papulovesicular cutaneous eruption that is characterized histologically by epidermal acantholysis with or without dyskeratosis [1,2]. Transient acantholytic dermatosis (TAD) is classically described as an isomorphic response to excessive heat, sweating, or xerosis which most commonly affects the trunk of white adult males and may persist for weeks to years [3]. More recently, additional triggers for TAD have been identified such as HIV, ionizing irradiation, end-stage renal disease, solid organ transplantation, prolonged bedrest, and

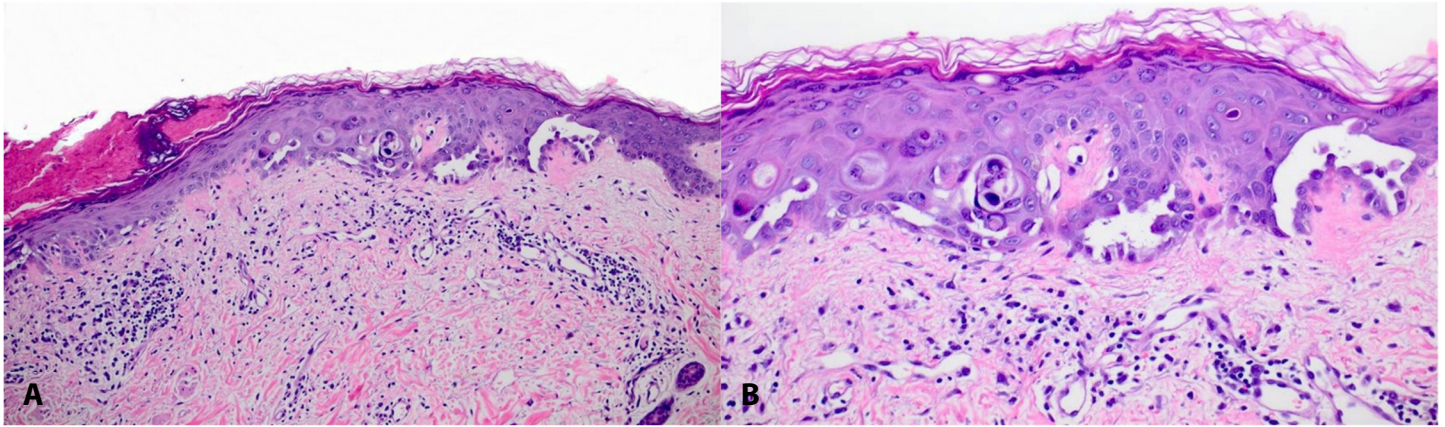
medications such as BRAF inhibitors and checkpoint inhibitors, among others [4-7]. Extensive or atypical presentations of TAD have been described and may be associated with malignancy [8]. Herein, we present a 65-year-old woman with TAD after induction chemotherapy with daunorubicin and cytarabine for newly diagnosed acute myelomonocytic leukemia (AMML).

## Case Synopsis

A 65-year-old woman on induction chemotherapy with daunorubicin and cytarabine presented to the dermatology inpatient consult service with a 10-day history of diffuse edematous and erythematous papules, some with purpuric appearance, scattered across the back (**Figure 1**), chest, abdomen, proximal upper extremities, and proximal inner thighs. The lesions were non-tender to palpation and Nikolsky sign was negative. The patient had started allopurinol and hydroxyurea therapy eight days prior to the cutaneous eruption. Her hospital course was complicated by thrombocytopenia requiring regular platelet infusion and neutropenic fever initially



**Figure 1. A)** Diffuse erythematous to violaceous papular eruption affecting the back. **B)** Crusted and edematous skin-colored-to-erythematous papules on the back.



**Figure 2.** H&E histopathology. **A)** Parakeratotic crust with mild acanthosis and acantholytic dyskeratosis, 10 $\times$ . **B)** Inset demonstrating acantholysis and dyskeratosis, 20 $\times$ .

treated with cefepime and vancomycin. Owing to persistent fever, the patient's antibiotic regimen was subsequently broadened to meropenem and vancomycin. Two days after the initiation of meropenem and vancomycin, the patient's rash worsened, becoming confluent in some areas. Failed treatment trials for the eruption at the time of dermatology consultation included topical clindamycin 1% gel, topical hydrocortisone 1% cream, and diphenhydramine. Clinical entities in the differential diagnosis included leukocytoclastic vasculitis, leukemia cutis, drug reaction, and transient acantholytic dermatosis. Two punch biopsies of mid-back lesions were performed for analysis on H&E (**Figure 2**) and direct immunofluorescence (DIF). Histopathology of this lesion revealed a parakeratotic crust with mild acanthosis, acantholysis, and dyskeratosis, with a superficial perivascular lymphocytic infiltrate; DIF was negative. These features were consistent with TAD. The patient was subsequently given triamcinolone 0.1% ointment to apply to affected areas on the trunk and extremities twice daily for two weeks, with noted gradual improvement throughout this treatment course.

## Case Discussion

We describe a woman with AMML who developed a diffuse, pruritic papular eruption following induction chemotherapy with daunorubicin and cytarabine. We suspected chemotherapy-induced TAD given the clinical context and characteristic histopathological

features. In support of this, additional rare cases of patients with acute myeloid leukemia developing TAD following induction chemotherapy have been described in the literature [9,10]. In general, chemotherapy-associated TAD is most frequently reported in the literature in association with cytotoxic chemotherapies, followed by small molecule inhibitors, as well as checkpoint inhibitors [7,11]. A well-documented association between atypical or extensive manifestations of TAD and underlying cancer further supports our patient's clinical presentation. In particular, in patients with unconventional presentations of TAD, hematologic malignancies are twice as likely as solid tumors [8]. Although the classic presentation of TAD features pruritus, previous reports of TAD associated with malignancy or chemotherapy were asymptomatic, though presented with a fever [12-14]. These trends in chemotherapy-induced TAD support a notion brought forth by Auh et al. [15] who suggested that the clinical presentation of TAD may vary depending on the etiology.

Transient acantholytic dermatosis has been described in patients with a variety of conditions with altered immunity, prompting a discussion of the role of immune status in chemotherapy-induced TAD. It has been hypothesized that T helper type two cells, whose overproduction is associated with allergic disease, may be involved in the pathogenesis of TAD [15]. Another hypothesized mechanism for TAD in this patient population is the excretion of chemotherapeutic agent from sweat glands which

then accumulates in the epidermis causing toxicity [16]. This is subsequently seen as dyskeratosis and acantholysis.

Additional etiologies of TAD that have been reported in the setting of malignancy other than antineoplastic agents include excessive perspiration, fever, occlusive immobility, and/or ionizing or UV radiation. Transient acantholytic dermatosis eruption has also coincided with the recurrence or detection of malignancy [13]. One study identified TAD in 6% of patients with leukemia, which is significant compared to a reported incidence of 0.8% in the hospital setting [17,18]. However, evidence is lacking to support a direct relationship. Of note, paraneoplastic itch may also occur in association with TAD [19].

Transient acantholytic dermatosis characteristically lacks response to any particular treatment. However, successful treatment with various regimens has been documented in case reports including low-dose systemic corticosteroids, oral retinoids, including isotretinoin, oral vitamin A, oral clindamycin, topical corticosteroids, topical tretinoin, and calcipotriol. In a recent systematic review of treatments for TAD, topical corticosteroids were found to be the most frequently employed treatment with a response rate

of 70%. The next most common treatments were systemic retinoids and corticosteroids, with response rates of 86% and 64%, respectively [20]. In our case, although the primary team's trials of topical clindamycin gel and topical hydrocortisone cream failed, our patient improved with topical triamcinolone. It is important to note that in a majority of patients with atypical or extensive TAD, symptoms have been reported to resolve within one year of presentation regardless of treatment [8,13]. However, in patients such as ours who experience severe pruritus, treatment with topical corticosteroids is a worthwhile consideration.

## Conclusion

Transient acantholytic dermatosis has been reported in a wide variety of clinical settings. Herein, we report a case of pruritic TAD associated with induction chemotherapy. This case underscores the importance of clinicopathologic correlation in accurately diagnosing and treating cutaneous eruptions in cancer patients.

## Potential conflicts of interest

The authors declare no conflicts of interest.

## References

1. Grover RW. Transient acantholytic dermatosis. *Arch Dermatol*. 1970;101:426-34. [PMID: 5440816].
2. Simon RS, Bloom D, Ackerman AB. Persistent acantholytic dermatosis. A variant of transient acantholytic dermatosis (Grover disease). *Arch Dermatol*. 1976;112:1429-31. [PMID: 786177].
3. Parsons JM. Transient acantholytic dermatosis (Grover's disease): A global perspective. *J Am Acad Dermatol*. 1996;35:653-66; quiz 67-70. [PMID: 8912557].
4. Boutli F, Voyatzi M, Lefaki I, Chaidemenos G, Kanitakis J. Transient acantholytic dermatosis (Grover's disease) in a renal transplant patient. *J Dermatol*. 2006;33:178-81. [PMID: 16620222].
5. French LE, Piletta PA, Etienne A, Salomon D, Saurat JH. Incidence of transient acantholytic dermatosis (Grover's disease) in a hospital setting. *Dermatology*. 1999;198:410-1. [PMID: 10490299].
6. Carlos G, Anforth R, Clements A, et al. Cutaneous toxic effects of BRAF inhibitors alone and in combination with MEK inhibitors for metastatic melanoma. *JAMA Dermatol*. 2015;151:1103-9. [PMID: 26200476].
7. Ellis SR, Vierra AT, Millsop JW, Lacouture ME, Kiuru M. Dermatologic toxicities to immune checkpoint inhibitor therapy: A review of histopathologic features. *J Am Acad Dermatol*. 2020;83:1130-43. [PMID: 32360716].
8. Gantz M, Butler D, Goldberg M, et al. Atypical features and systemic associations in extensive cases of Grover disease: A systematic review. *J Am Acad Dermatol*. 2017;77:952-7 e1. [PMID: 28918973].
9. Novice T, Shastry J, Guggina L. Papular eruption after induction chemotherapy for acute myeloid leukemia. *JAAD Case Rep*. 2020;6:159-60. [PMID: 32072003].
10. Zhu HJ, Clark LN, Deloney LA, McDonald JE. Grover disease (transient acantholytic dermatosis) in acute myeloid leukemia on FDG PET/CT. *Clin Nucl Med*. 2014;39:e173-5. [PMID: 24152615].
11. Beer J, Rosenbach M. Grover disease associated with chemotherapy: Review of potential pathophysiology, current treatments, and future directions. *J Drugs Dermatol*. 2020;19:1056-64. [PMID: 33196735].
12. Horn TD, Groleau GE. Transient acantholytic dermatosis in immunocompromised febrile patients with cancer. *Arch Dermatol*. 1987;123:238-40. [PMID: 3813598].
13. Guana AL, Cohen PR. Transient acantholytic dermatosis in oncology patients. *J Clin Oncol*. 1994;12:1703-9. [PMID: 8040681].
14. Davis MD, Dinneen AM, Landa N, Gibson LE. Grover's disease: Clinicopathologic review of 72 cases. *Mayo Clin Proc*. 1999;74:229-34. [PMID: 10089990].

15. Auh SL, Polcari I, Petronic-Rosic V, Sethi A. Role of immune status in chemotherapy-induced transient acantholytic dermatosis. *Skinmed*. 2017;15:483-4. [PMID: 29282194].
16. Gupta M, Huang V, Linette G, Cornelius L. Unusual complication of vemurafenib treatment of metastatic melanoma: Exacerbation of acantholytic dyskeratosis complicated by Kaposi varicelliform eruption. *Arch Dermatol*. 2012;148:966-8. [PMID: 22911209].
17. Desch JK, Smoller BR. The spectrum of cutaneous disease in leukemias. *J Cutan Pathol*. 1993;20:407-10. [PMID: 8300925].
18. French LE, Piletta PA, Etienne A, Salomon D, Saurat JH. Incidence of transient acantholytic dermatosis (Grover's disease) in a hospital setting. *Dermatology*. 1999;198:410-1. [PMID: 10490299].
19. Rowe B, Yosipovitch G. Paraneoplastic itch management. *Curr Probl Dermatol*. 2016;50:149-54. [PMID: 27578084].
20. Bellinato F, Maurelli M, Gisondi P, Girolomoni G. Clinical features and treatments of transient acantholytic dermatosis (Grover's disease): A systematic review. *J Dtsch Dermatol Ges*. 2020;18:826-33. [PMID: 32767513].