

Novel teprotumumab treatment of severe thyroid dermopathy; ototoxicity as an adverse side effect

Riya T Patel¹ MBS, Douglas J Grider^{1,2} MD, Nicholas Ramey³ MD

Affiliations: ¹Virginia Tech Carilion School of Medicine, Roanoke, Virginia, USA, ²Dermatology Section, Department of Internal Medicine, Carilion Clinic, Roanoke, Virginia, USA, ³Vistar Eye Center, Roanoke, Virginia, USA

Corresponding Author: Nicholas Ramey, 2154 McVitty Road SW, Roanoke, VA 24018, Tel: 540-344-4000, Email: nramey1@gmail.com

Abstract

Pretibial myxedema, more generally thyroid dermopathy, results from mucopolysaccharide accumulation in the dermis, typically between the knee and dorsal foot. Thyroid dermopathy presents in Graves disease, but can occur in Hashimoto thyroiditis, primary hypothyroidism, and euthyroid patients. Treatment of thyroid eye disease with teprotumumab is established in the literature, with few case reports also showing improvement in pretibial myxedema. Reported is a 76-year-old man with thyroid eye disease and pretibial myxedema treated with teprotumumab; improvement was demonstrated in both conditions. He developed "muffled" hearing as an adverse effect, a complication not widely published in the dermatology literature. At 18 months post-treatment, his symptoms are stable without recurrence, but hypoacusis persists. Given the long-term efficacy and side-effects, dermatologists should recognize the potential benefits and risks of using teprotumumab for thyroid dermopathy. A baseline audiogram may be considered prior to therapy. Additionally, longitudinal data is needed to document the benefits and risks of this novel therapy.

Keywords: Graves disease, hearing, IGF-1R, ophthalmopathy, pretibial myxedema, teprotumumab

Introduction

Pretibial myxedema (PTM), one form of thyroid dermopathy (TD), is a rare autoimmune complication

of Graves disease. The classic triad of Graves disease consists of goiter, thyroid-related orbitopathy (also referred to as thyroid eye disease (TED)), and TD. Myxedema is characterized by varying degrees of nonpitting edema with plaques or nodules, sometimes with an orange-peel appearance [1]. Although it is commonly seen in the pretibial area, ankles, and feet, myxedema can also involve elbows, knees, upper back, and neck [2]. Thyroid dermopathy usually develops after the onset of TED with co-prevalence reported as 0.15 per 10,000 people [3].

The pathophysiology of TED and TD involves thyroid-stimulating hormone (TSH) receptor autoantibodies and/or antigen-specific T cells causing activation and proliferation of fibroblasts and an inflammatory response [4,5]. Cytokines induce fibroblasts to release glycosaminoglycans, which is noted in the ophthalmopathy. Thyroid dermopathy occurs due to an accumulation of glycosaminoglycans, especially hyaluronic acid, which results in mucinous edema with fragmentation of collagen fibers [6].

Until recently, effective treatment options for TED and TD were limited, usually involving systemic or topical corticosteroids, orbital radiation, or surgery, often with incomplete responses. In 2020, teprotumumab, a human monoclonal antibody inhibitor of insulin-like growth factor 1 receptor (IGF-1R), was FDA approved for TED [7]. Two case reports have since reported early improvement in PTM in patients treated with teprotumumab for TED [8,9]. However, the long-term efficacy of teprotumumab's effects on PTM or other forms of TD have not been

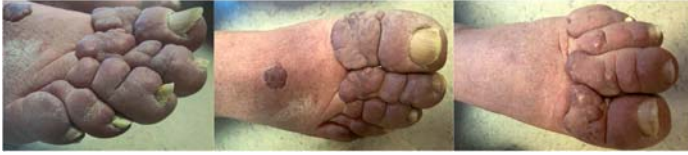

Figure 1. Thyroid dermopathy of the feet with acropexy of the toes pre-treatment.

documented. We present a patient with long-term resolution in TD (PTM with severe acropachy) after teprotumumab treatment of TED.

Case Synopsis

A 76-year-old man with longstanding stable mild proptosis and periorbital inflammation was evaluated in the oculofacial plastic surgery clinic in 2017 for increasing periorbital symptoms. In 2000, the patient was diagnosed with Graves disease and treated with radioactive iodine. At that time, he developed mild bilateral proptosis and dry eye symptoms, as well as bilateral PTM and acropachy of the toes (**Figure 1**). He was managed conservatively with lubricating eye drops and custom footwear to accommodate his enlarged feet. A confirmatory biopsy demonstrated mucopolysaccharide (mostly hyaluronic acid) deposition in the reticular dermis which was consistent with PTM (**Figure 2**). In 2016, his periorbital and lower extremity manifestations began worsening and he underwent thyroidectomy as well as orbital radiotherapy and oral selenium

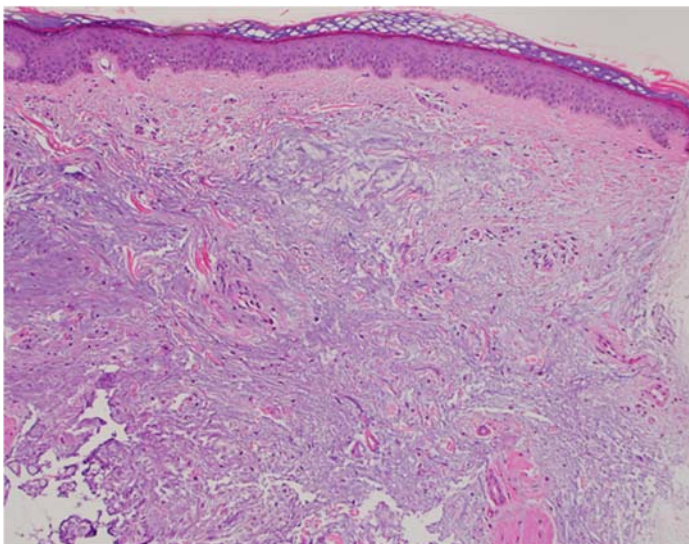


Figure 2. H&E histopathology demonstrating mucopolysaccharide deposition in the reticular dermis, 10x.

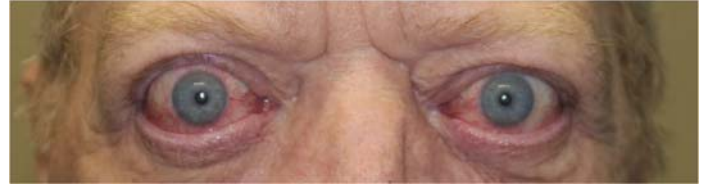

Figure 3. Bilateral exophthalmos, eyelid retraction, ocular surface exposure with conjunctival injection pre-treatment.

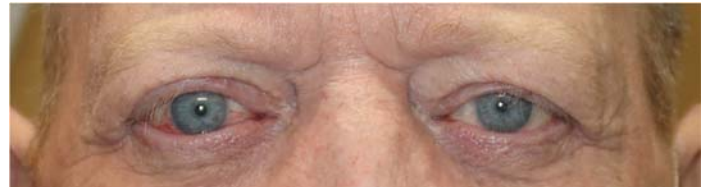

Figure 4. Improved bilateral exophthalmos and periorbital inflammation three months post-treatment with teprotumumab.

supplementation. Although his thyroid function stabilized on levothyroxine, his TED and TD continued to progress. He deferred all surgical interventions and was maintained on maximal medical therapy for ocular surface exposure symptoms. His custom footwear was adapted as needed, increasing from size 11 to 17 over the course of three years. In April 2020, the patient elected to proceed with teprotumumab treatment to reduce significant bilateral proptosis, periorbital inflammation, upper and lower lid retraction, and severe ocular surface exposure symptoms (**Figure 3**). The regimen consisted of one dose of intravenous teprotumumab at 10mg/kg followed every three weeks with 20mg/kg/dose for seven additional infusions. After the first four infusions, he noted subjective improvement in his TED and TD. He also noticed mild constant muffled hearing but elected to continue treatment because he believed the benefits to his eyes and feet substantially outweighed his hearing changes. By the completion of his treatment regimen, his proptosis, eyelid retraction, periorbital inflammation (**Figure 4**), and lower extremity edema (**Figure 5**) had significantly improved. To date, 18 months after finishing teprotumumab, his eyes and feet remain stable but he still reports muffled hearing.

Case Discussion

Our patient with TD experienced significant improvement of his lower extremity plaques after

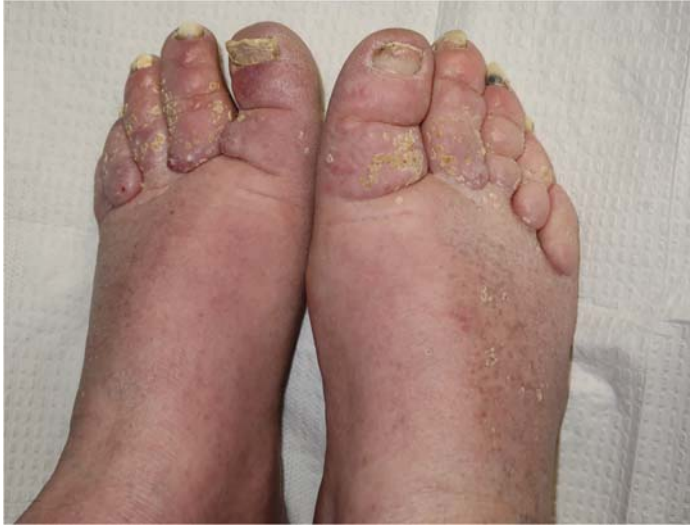

Figure 5. Improved thyroid dermopathy of the feet 18 months post-treatment with teprotumumab.

treatment with teprotumumab, the only IGF1R inhibitor approved to treat patients with thyroid eye disease. IGF1R activation enhances the effects of TSH receptor autoantibodies in orbital fibroblasts [10]. This stimulation leads to glycosaminoglycan accumulation and a T cell-mediated inflammatory cascade, resulting in the classic clinical manifestations of TED, including proptosis, extraocular muscle expansion and fibrosis, eyelid retraction, and periocular inflammation [11].

The relationship between IGF1R and PTM remains unknown. However, dermal and orbital fibroblasts may share phenotypic similarities that determine their responses to TSH receptor autoantibodies [10]. Teprotumumab may attenuate IGF1R and TSH activity in dermal fibroblasts, resulting in a reduction of proinflammatory cytokine induction and glycosaminoglycan accumulation, leading to an improvement in TD as seen in our patient [12].

Finally, although this patient experienced significant improvement in TED and TD, he did experience muffled hearing for several months after completion of teprotumumab. At 18 months, however, his

hearing changes had resolved. Altered hearing adverse events were documented in phase two and three clinical trials in up to 10% of treated patients [7,13]. As teprotumumab usage becomes more widespread, we may learn more about these hearing changes, which include hypoacusis, tinnitus, and autophony [14,15]. Currently, these authors order tympanometry and audiogram testing before treatment and after any reports of disrupted hearing [16]. Of over 60 patients treated at this institution, one patient elected to discontinue treatment (after substantial orbital improvement after three doses) due to hearing changes.

Conclusion

Graves disease is associated with characteristic ophthalmopathy and dermopathy, which may have similar pathophysiology. Both conditions traditionally have been functionally debilitating and very difficult to treat. Teprotumumab, a human monoclonal antibody inhibitor of the insulin-like growth factor type 1 receptor has proven efficacy in treating proptosis, diplopia, and inflammatory orbitopathy. This treatment also improved our patient's lower extremity dermopathy and acropachy. To date, at 18 months post-treatment, this report documents a durable response of TD to teprotumumab, with tolerable and self-normalizing hearing changes. Providers treating patients with TD are encouraged to join the multidisciplinary teams managing their patients' thyroid eye disease, as teprotumumab may offer valuable systemic therapeutic benefits.

Potential conflicts of interest

NR serves as a paid consultant on the Horizon Therapeutics Speaker Bureau.

References

1. Fatourech V. Thyroid dermopathy and acropachy. *Best Pract Res Clin Endocrinol Metab.* 2012;26:553-565. [PMID: 22863396].
2. Doshi DN, Blyumin ML, Kimball AB. Cutaneous manifestations of thyroid disease. *Clin Dermatol.* 2008;26:283-287. [PMID: 18640525].
3. Perros P, Hegedüs L, Bartalena L, et al. Graves' orbitopathy as a rare disease in Europe: a European Group on Graves' Orbitopathy (EUGOGO) position statement. *Orphanet J Rare Dis.* 2017;12:72.

- [PMID: 28427469].
4. Kahaly G, Förster G, Hansen C. Glycosaminoglycans in thyroid eye disease. *Thyroid*. 1998;8:429-432. [PMID: 9623737].
 5. Ajjan RA, Watson PF, Weetman AP. Cytokines and thyroid function. *Adv Neuroimmunol*. 1996;6:359-386. [PMID: 9183517].
 6. Shishido M, Kuroda K, Tsukifuji R, Fujita M, Shinkai H. A case of pretibial myxedema associated with Graves' disease: an immunohistochemical study of serum-derived hyaluronan-associated protein. *J Dermatol*. 1995;22:948-952. [PMID: 8648004].
 7. Smith TJ, Kahaly GJ, Ezra DG, et al. Teprotumumab for thyroid-associated ophthalmopathy. *N Engl J Med*. 2017; 376:1748-1761. [PMID: 28467880].
 8. Varma A, Rheeman C, Levitt J. Resolution of pretibial myxedema with teprotumumab in a patient with Graves disease. *JAAD Case Rep*. 2020;6:1281-1282. [PMID: 33294564].
 9. Petit L, Catinis A, Richard E, Silverberg J. A case of pretibial myxedema treated with teprotumumab. *JAAD Case Rep*. 2021;16:134-136. [PMID: 34604488].
 10. Davies TF, Andersen S, Latif R, et al. Graves' disease. *Nat Rev Dis Primers*. 2020;6:52. [PMID: 32616746].
 11. Wang Y, Patel A, Douglas RS. Thyroid Eye Disease: How A Novel Therapy May Change The Treatment Paradigm. *Ther Clin Risk Manag*. 2019;15:1305-1318. [PMID: 31814726].
 12. Chen H, Mester T, Raychaudhuri N, et al. Teprotumumab, an IGF-1R blocking monoclonal antibody inhibits TSH and IGF-1 action in fibrocytes. *J Clin Endocrinol Metab*. 2014;99: E1635-E1640. [PMID: 24878056].
 13. Douglas RS, Kahaly GJ, Patel A, et al. Teprotumumab for the Treatment of Active Thyroid Eye Disease. *N Engl J Med*. 2020;382:341-352. [PMID: 31971679].
 14. Kossler A, Sears CM, Dosiou C. Hearing Loss and Teprotumumab. *J Endocr Soc*. 2021;5(Suppl 1):A839. [PMCID: PMC8089925].
 15. Yu CY, Correa T, Simmons BA, Hansen MR, Shriver EM. Audiology findings in patients with teprotumumab associated otologic symptoms. *Am J Ophthalmol Case Rep*. 2021;24:101202. [PMID: 34585021].
 16. Belinsky I, Creighton FX Jr, Mahoney N, et al. Teprotumumab and Hearing Loss: Case Series and Proposal for Audiologic Monitoring. *Ophthalmic Plast Reconstr Surg*. 2022;38:73-78. [PMID: 34085994].