

Eruptive sebaceous hyperplasia as a side effect of oral tacrolimus in a renal transplant recipient

Katherine A. Levandoski BS, Nicholas A. Girardi MD, Manisha J. Loss MD

Affiliations: Department of Dermatology, Johns Hopkins Hospital, and Johns Hopkins University School of Medicine, Baltimore, Maryland

Corresponding Author: Katherine Levandoski, 401 Park Drive, Suite 401 East, Boston, MA 02215, Email: klevand1@jhmi.edu

Abstract

Sebaceous hyperplasia, a benign proliferation of sebaceous glands, has been well documented in organ transplant recipients treated with cyclosporine. Sebaceous hyperplasia has not been strongly associated with any other immunosuppressive medications. We report a case of eruptive sebaceous hyperplasia in a renal transplant recipient with no previous exposure to cyclosporine that was recently started on tacrolimus, mycophenolate mofetil, and prednisone. To our knowledge, this is the first report of eruptive sebaceous hyperplasia in a renal transplant recipient who was immunosuppressed with tacrolimus and had no prior exposure to cyclosporine.

Keywords: sebaceous hyperplasia; tacrolimus; renal transplant

Introduction

Sebaceous hyperplasia (SH) is a benign proliferation of sebaceous glands that most commonly presents as asymptomatic yellowish papules with central umbilication on the face [1-3]. Cyclosporine-induced SH has been well documented in organ transplant recipients [2-6]. Sebaceous hyperplasia has been reported in patients on cyclosporine immunosuppression following renal, heart, and hematopoietic stem cell transplant [2-6]. Increased rates of SH have not been observed in organ transplant recipients on other immunosuppressive medications such as azathioprine and prednisolone [5, 7]. Here, we report a case of eruptive sebaceous hyperplasia in a renal transplant recipient without a prior exposure to cyclosporine that was recently started on tacrolimus, mycophenolate mofetil, and

prednisone.

Case Synopsis

A 29-year-old Hispanic male with a history of two renal transplants for end stage renal disease secondary to an unknown etiology presented for evaluation of a rash over his forehead, cheeks, and chin. In 2006, the patient received a living unrelated renal transplant in Mexico and was immunosuppressed with unknown dosages of tacrolimus and mycophenolate mofetil. In 2009, his transplant was complicated by rejection, which was treated with thymoglobulin and oral prednisone. He developed a second episode of rejection in 2012 and was maintained on hemodialysis until 2015. In 2015, he received a deceased donor renal transplant at Johns Hopkins Hospital. At the time of the transplant the patient was started on tacrolimus 1mg twice daily, a prednisone taper starting at 20mg daily and mycophenolate mofetil 500mg four times daily. Nine days post-transplant, tacrolimus was increased to 6mg twice-daily. Approximately 2 weeks after initiation of the above triple immunosuppression regimen, the patient began to notice a rash on his face, which he presumed was acne.

He was referred to dermatology approximately two months after the onset of the rash. The patient denied having any similar appearing rashes prior to his most recent kidney transplant. Examination of the face revealed numerous small, yellowish dome-shaped papules with central umbilication scattered over the forehead, lateral/malar cheeks, and chin (**Figure 1**). The patient denied having any similar appearing lesions prior to his most recent kidney transplant. The morphology of the lesions was thought to be most consistent with either molluscum contagiosum or SH. Initially, molluscum contagiosum was favored

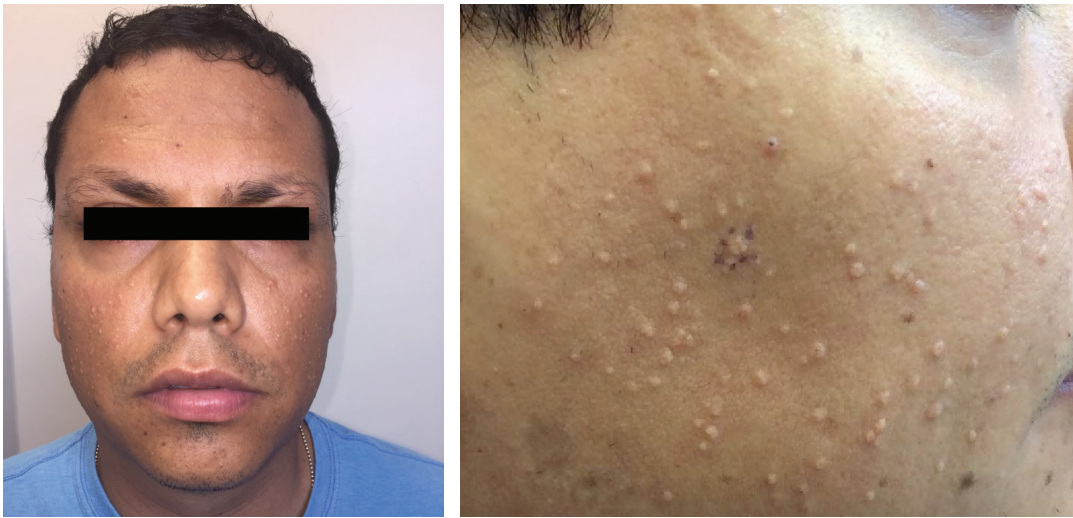

Figure 1. Clinical appearance. Sebaceous hyperplasia scattered over the forehead, cheeks, and chin.

as the more likely etiology given the acute onset in the setting of heavy immunosuppression. The patient was prescribed topical imiquimod to be applied three to five times per week. He denied any appreciable changes in the size or number of lesions after four months of use. Therefore, a shave biopsy was performed to confirm our suspicion of SH.

Pathology showed enlarged superficial sebaceous glands, each consisting of mature sebaceous lobules, surrounding a dilated central duct, consistent with SH (**Figure 2**). No evidence of molluscum was identified. The patient was started on tretinoin 0.05% cream nightly.

Case Discussion

Dermatologic complications have long been recognized in renal transplant recipients [8]. In 1986, Bencini et al. noted that pilosebaceous lesions, including SH, hypertrichosis, acne, and epidermal cysts, occur at an increased frequency in renal transplant patients [8].

In early case series of renal transplant recipients who developed SH, every patient was noted to be taking cyclosporine [3]. Cyclosporine-induced SH, which is now well-documented, occurs in up to 30% of renal transplant patients treated with cyclosporine [4]. Similar rates of SH have not been observed in renal transplant recipients not on cyclosporine [3, 7]. In one report of 151 kidney transplant recipients who were not taking cyclosporine, none developed SH [3, 7]. In another report, the prevalence of SH among renal transplant patients not on cyclosporine

was significantly lower than among patients on cyclosporine (19% versus 37%), and was comparable to rates among age and sex-matched controls (24%), [2, 4].

Sebaceous hyperplasia has been strongly associated with cyclosporine, but not any other immunosuppressive medications. Therefore, it is interesting that this patient, without any

prior exposure to cyclosporine, developed diffuse eruptive SH immediately after initiation of triple immunosuppression with tacrolimus, mycophenolate mofetil, and prednisone.

In their report of a patient who was immunosuppressed with cyclosporine and tacrolimus at different points in time, Jung et al. postulated that tacrolimus might contribute to the development of SH [3]. As calcineurin inhibitors, cyclosporine and tacrolimus share similar mechanisms of action and physiochemical properties [3]. Both inhibit proinflammatory cytokines and are highly lipid soluble, which allows for cutaneous accumulation [3]. Cyclosporine has a stimulatory effect on undifferentiated sebocytes, thus inducing hyperproliferation and the development of SH [2]. Tacrolimus may have a similar effect on sebaceous glands.

Although the patient we report was immunosuppressed with tacrolimus after his first transplant, he did not develop SH until after his second transplant. There have been reports of patients on cyclosporine immunosuppression that did not develop SH until years after starting the medication, suggesting that drug-induced SH may be time- or dose-dependent [9].

There have been a handful of reports of SH in patients with chronic renal failure. Yamamoto et al. and Terui et al. each reported two patients with chronic renal failure who developed multiple SH but never received immunosuppression or renal transplantation [1,

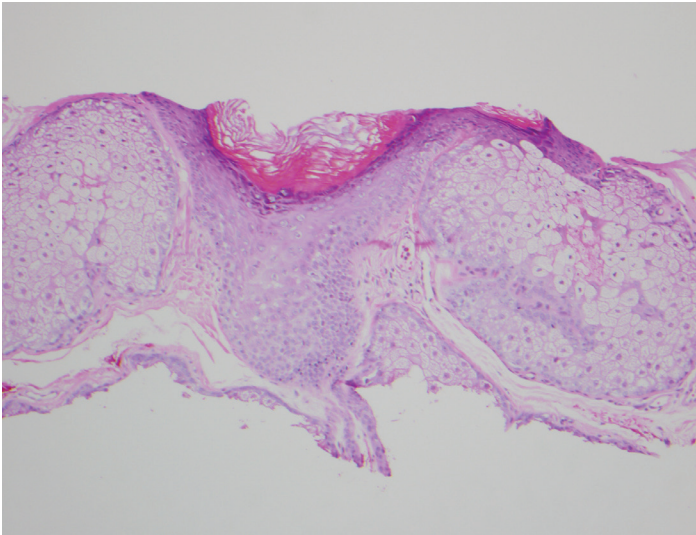


Figure 2. Histopathology of shave biopsy shows enlarged superficial sebaceous glands, each consisting of mature sebaceous lobules, surrounding a dilated central duct, consistent with sebaceous hyperplasia.

10]. Although many dermatologic features are associated with renal dysfunction, multiple SH have been reported only rarely in this setting, making underlying renal disease an unlikely precipitant of this patient's SH.

Reported effective treatments for cyclosporine-induced SH in renal transplant recipients include oral isotretinoin and topical photodynamic therapy [3]. Other treatment options for SH that have been described in immunocompetent individuals include surgical excision/curettage, topical retinoids, cryotherapy, electrodesiccation, laser treatment (pulsed-dye, CO₂, and diode), and chemical peels (trichloroacetic and bichloroacetic acids), [2].

Although cyclosporine-induced SH has been well documented in the literature, there have been few reports of SH in organ transplant recipients on other immunosuppressive medications. To our knowledge, this is the first report of eruptive SH in a renal transplant recipient who was immunosuppressed with tacrolimus and with no prior exposure to cyclosporine.

References

1. Yamamoto T, Takayama K, Igawa K, Yamanaka M, Ueno M, Yokozeki H. Eruptive sebaceous hyperplasia in association with chronic renal failure. *Clin Exp Dermatol*. 2009;34(7):e244–5. [PMID: 19508575]
2. Wilken R, Fung MA, Shi VY, Cheng MY, Patel F, Sultani H, et al. Cyclosporine-induced sebaceous hyperplasia in a hematopoietic stem cell transplant patient: delayed onset of a common adverse

- event. *Dermatol Online J*. 2016;22(1). [PMID: 26990469]
3. Jung HY, Kim M, Cho BK, Park HJ. A Case of Cyclosporine-Induced Sebaceous Hyperplasia in a Renal Transplant Patient Successfully Treated with Isotretinoin. *Ann Dermatol*. 2016;28(2):271–2. [PMID: 27081287]
4. Salim A, Reece SM, Smith AG, Harrison D, Ramsay HM, Harden PN, et al. Sebaceous hyperplasia and skin cancer in patients undergoing renal transplant. *J Am Acad Dermatol*. 2006;55(5):878–81. [PMID: 17052497]
5. de Berker DA, Taylor AE, Quinn AG, Simpson NB. Sebaceous hyperplasia in organ transplant recipients: shared aspects of hyperplastic and dysplastic processes? *J Am Acad Dermatol*. 1996;35(5 Pt 1):696–9. [PMID: 8912563]
6. Marini M, Saponaro A, Remorino L, Lynch P, Magariños G. Eruptive lesions in a patient with bone marrow transplantation. *Int J Dermatol*. 2001;40(2):133–5. [PMID: 11328396]
7. Taylor AE, Shuster S. Skin cancer after renal transplantation: the causal role of azathioprine. *Acta Derm Venereol*. 1992;72(2):115–9. [PMID: 1350395]
8. Bencini PL, Montagnino G, Sala F, De Vecchi A, Crosti C, Tarantino A. Cutaneous lesions in 67 cyclosporin-treated renal transplant recipients. *Dermatologica*. 1986;172(1):24–30. [PMID: 2937664]
9. Chin M, Anstey A. Sebaceous hyperplasia in a renal transplant patient on sirolimus. *J Am Acad Dermatol*. 2013;68(4, Supplement 1):AB141.
10. Terui T, Takahashi M. Sebaceous hyperplasia observed in hemodialysis patient (in Japanese). *Rinsho Derma*. 1986;28:193–6.