

**Case report**

**Marginal vitiligo: an unusual depigmenting disorder**

**Ritika Trikha BS<sup>1</sup>, Nancye McCowan MD<sup>2</sup>, Jeremy Jackson MD<sup>2</sup>, Robert T. Brodell MD<sup>2,3</sup>**

**Dermatology Online Journal 21 (3): 7**

<sup>1</sup>**Chicago Medical School, North Chicago, IL**

<sup>2</sup>**University of Mississippi Medical Center, Jackson, Mississippi**

<sup>3</sup>**University of Rochester School of Medicine and Dentistry, Rochester New York**

**Correspondence:**

Robert T. Brodell, M.D.  
Department of Dermatology  
University of Mississippi Medical Center  
2500 North State Street  
Jackson, Mississippi 39216  
Email: rbrodell@umc.edu  
Office: 601-815-8000  
Cell: 330-883 5302  
Fax: 601-918-8080

---

**Abstract**

**Background:** Marginal vitiligo, or inflammatory vitiligo with raised borders is a unique subset of vitiligo vulgaris presenting with scattered depigmented, pruritic patches surrounded by a raised, erythematous border. Alternative diagnoses include discoid lupus erythematosus and cutaneous T-cell lymphoma.

**Purpose:** To properly guide treatment, it is important to exclude other conditions that present with a similar pattern of depigmentation. This requires the ability to identify specific cutaneous and histologic clues that support this diagnosis.

**Material and Methods:** A 22 year-old man presented with a history of depigmented, pruritic patches and surrounding raised, erythematous borders. Several areas of depigmentation on the scalp were associated with alopecia. Punch biopsy of the rim of a patch was performed and sent for routine hematoxylin and eosin staining and direct immunofluorescence.

**Results and Conclusion:** Histopathology revealed a spongiotic dermatitis with superficial dermal lymphocytic infiltrate and eosinophils; DIF demonstrated no immunoreactants. A diagnosis of inflammatory vitiligo with raised borders was thus made based on consistent clinical and histopathologic features. The symptoms improved with topical clobetasol 0.05% cream twice daily.

**Keywords:** vitiligo, lupus, CTCL, mycosis fungoides

**Abbreviations and Acronyms:**

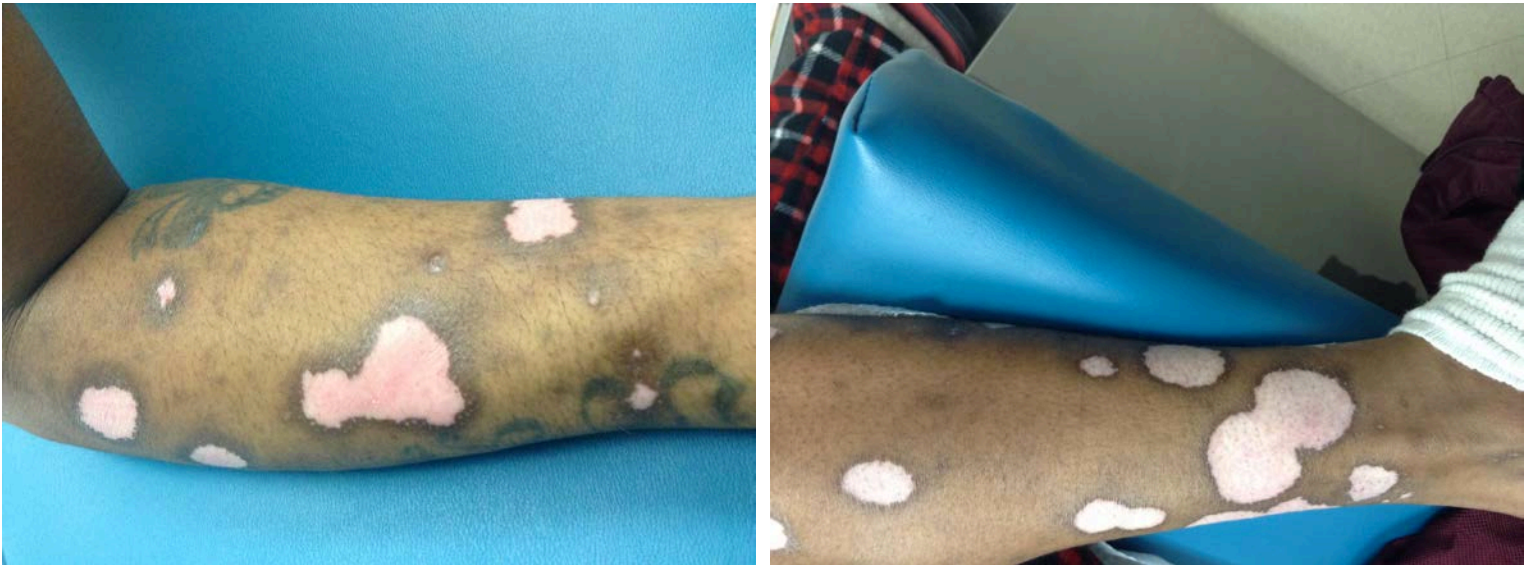DIF: Direct immunofluorescence  
DLE: Discoid lupus erythematosus  
H&E: Hematoxylin and eosin  
HIV: Human immunodeficiency virus  
IVRB: Inflammatory vitiligo with raised borders  
MART1: Melanoma antigen recognized by T cells 1  
MF: Mycosis fungoides  
PUVA: Psoralen ultraviolet A  
UV: Ultraviolet

## Introduction

Marginal vitiligo or inflammatory vitiligo with raised borders (IVRB) is a rare subset of vitiligo vulgaris. Depigmented patches are surrounded by a raised, erythematous, sometimes hyperpigmented, border. Lesions are often associated with pruritus [1,2]. Understanding the diagnostic features of IVRB is critical to permit it to be differentiated from other unrelated conditions presenting with depigmentation. A case of IVRB is presented emphasizing specific cutaneous and histologic clues that support this diagnosis.

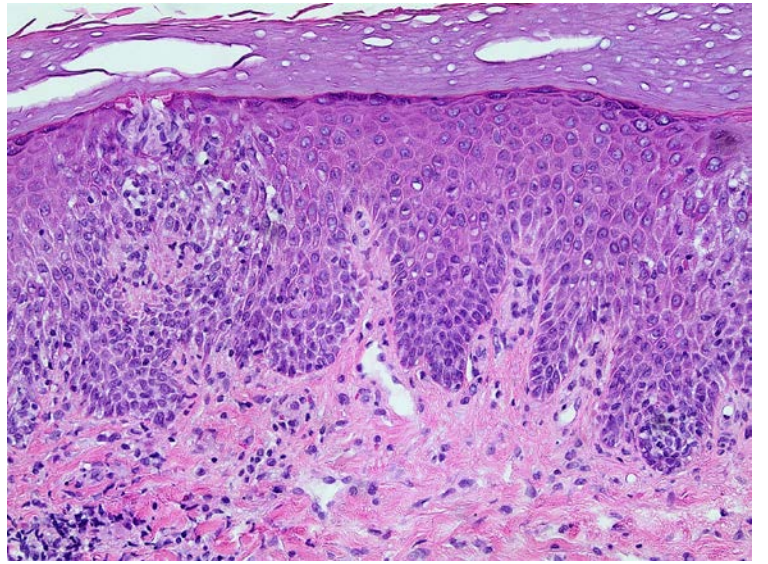
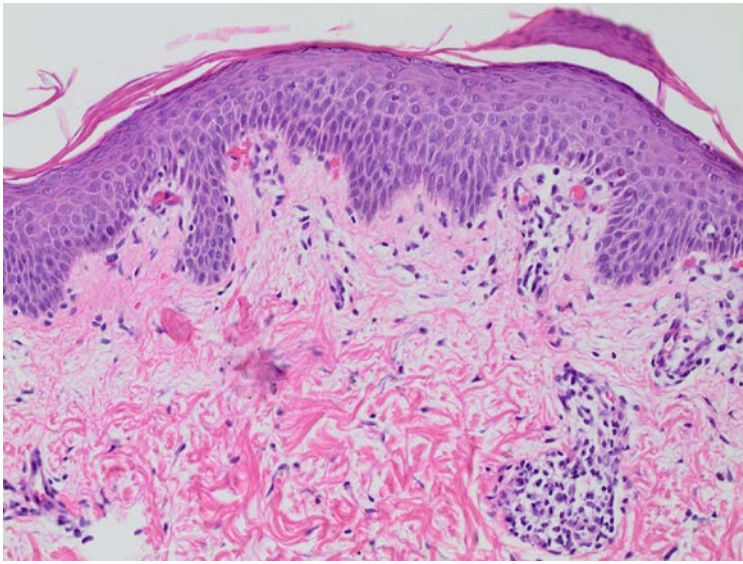
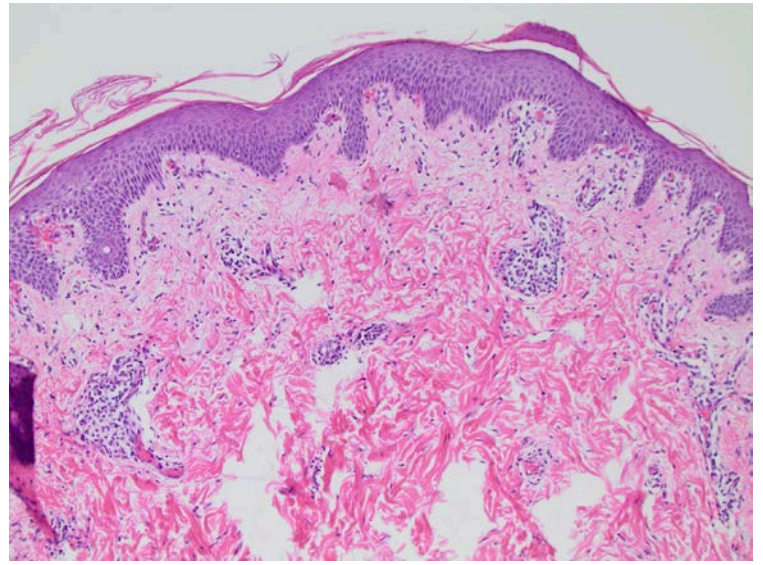
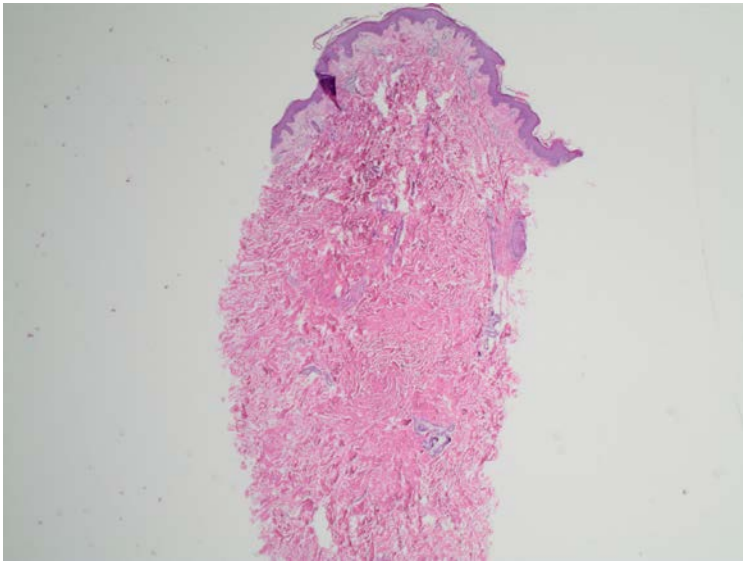
## Case synopsis

A 22 year-old man with Human Immunodeficiency Virus (HIV), presented to the dermatology clinic with a ten-month history of progressively worsening, mildly pruritic patches of depigmented skin. The patient's HIV status had been stable on efavirenz/emtricitabine/tenovir (Atripla™). The CD4+ T cell percentage was 68% and viral load was less than 20. He was taking prophylactic sulfamethoxazole/trimethoprim (Bactrim™) and using topical dibucaine as needed for the itching. Though working as a janitor, the patient was not aware of any specific exposures that may have aggravated his skin condition. Physical examination revealed scattered 2-3 cm depigmented patches bilaterally on the upper and lower extremities surrounded by raised, hyperpigmented and slightly erythematous borders (Figure 1a and 1b). Two 3 cm depigmented patches in the scalp were associated with complete hair loss. However, hair follicles were preserved.



**Figure 1a and 1b.** Multiple 2-3 mm depigmented patches with raised, annular borders are present on the lower extremities. Similar lesions were present on the arms and scalp.

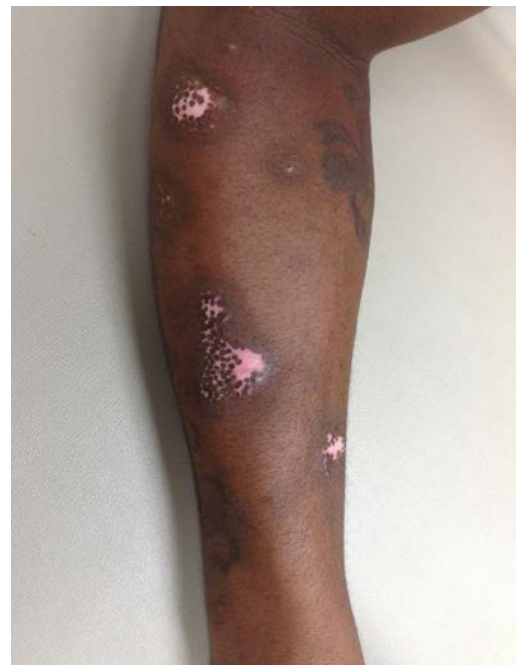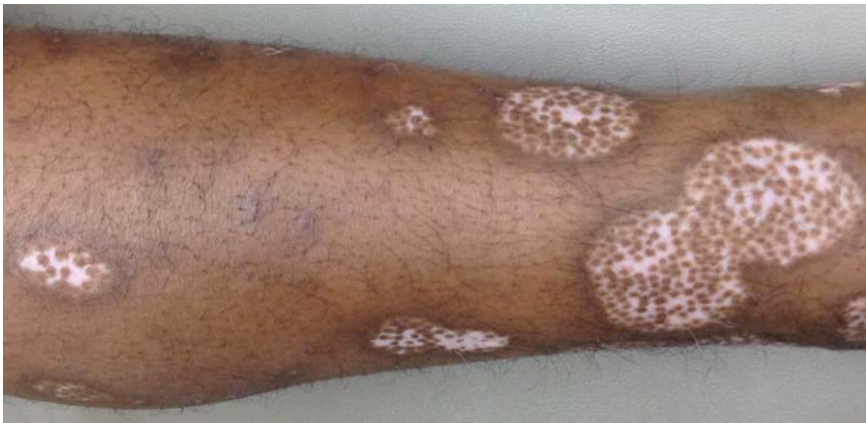*Histopathology:* The rim of a representative patch was sampled with a 6 mm punch biopsy, half submitted for routine hematoxylin and eosin staining and half for direct immunofluorescence (DIF). A spongiotic dermatitis with superficial dermal lymphocytic infiltrate and eosinophils was identified (Figure 2a-d). DIF demonstrated no immunoreactants.



**Figure 2a, 2b, 2c, 2d.** Hematoxylin-eosin staining of specimen taken from the erythematous, annular border of depigmented skin lesions with increasing magnification (40x, 100x, 200x, 400x, respectively). Sections show mild acanthosis and mild intercellular spongiosis. Underlying superficial perivascular and interstitial inflammation is comprised of lymphocytes, histiocytes, and scattered eosinophils.

The characteristic cutaneous findings and the distinguishing histopathologic features led to a diagnosis of IVRB.

*Treatment:* The patient was treated with topical clobetasol 0.05% cream twice daily. Within eight weeks, considerable perifollicular repigmentation was noted in all patches and pruritus was controlled (Figure 3a and 3b).



**Figure 3a and 3b.** Perifollicular repigmentation of lesions on the upper and lower extremities following eight weeks of treatment with a superpotent topical corticosteroid

## Discussion

IVRB is a rare form of vitiligo manifesting as 1-3 cm patchy, depigmented skin surrounded by a discrete, erythematous, sometimes hyperpigmented, raised border [1,2,3]. The patches can become confluent and pruritus is often present [3,4]. Common vitiligo, on the other hand, demonstrates little in the way of signs or symptoms of inflammation, and the skin may appear completely normal aside from the absence of melanocytes in depigmented skin patches confirmed by melanin histochemical stains and immunostains such as S-100 and MART 1. Biopsies from the erythematous rim of IVRB, however, demonstrate a dermal lymphocytic infiltrate, exocytosis of lymphocytes, focal spongiosis, and more rarely, an interface dermatitis (Table 1) [1,2,3,4].

**Table 1.** Comparing the histologic and clinical features, and treatments of the various alternative diagnoses of marginal vitiligo

Differential Diagnoses	Clinical Features	Histologic Features	Treatment
Discoid Lupus Erythematosus	Early lesion- sharply demarcated, coin-shaped plaques with dilated follicular orifices Late lesion- expanding lesion with peripheral hyperpigmentation, central atrophic scarring and hypopigmentation; causes scarring alopecia <sup>18</sup>	Follicular plugging, thickened basement membrane, hyperkeratosis, vacuolar alteration of the basal cell layer, dermal lymphocytic infiltrate <sup>18</sup> ; immunoglobulin or complement deposition at the dermal-epidermal junction (lupus band)	Antimalarials (hydroxychloroquine, chloroquine, quinacrine); topical corticosteroids; immunosuppressives (methotrexate, mycophenolate mofetil, azathioprine) <sup>18</sup>
Hypopigmented mycosis fungoides	Patches or plaques of hypo- or depigmentation; may consist of areas of atrophy, hyperpigmentation, and telangiectasias; later stages involve tumors of 5mm elevation above skin surface <sup>12</sup>	Band-like lymphocytic infiltrate in the papillary dermis, coarse wiry fibrosis <sup>11</sup> ; Pautrier microabscesses	Topical corticosteroids; topical retinoids (bexarotene); topical chemotherapy (carmustine); systemic phototherapy (UV-B light treatment or UV-A light treatment enhanced with psoralen [PUVA]) <sup>12</sup>
Marginal vitiligo	Patches of depigmentation, ranging from 1-3cm, circumscribed by a raised, erythematous periphery	Dermal lymphocytic infiltration, exocytosis of lymphocytes, focal spongiosis, interface dermatitis <sup>1,2,3,4</sup>	Topical corticosteroids; topical immunomodulators; vitamin D analogues; systemic steroids; excimer laser therapy; systemic phototherapy (narrow band UV-B, PUVA) <sup>1,2,3</sup>

The differential diagnosis of IVRB includes DLE. In fact, the patches of depigmentation with peripheral erythema, hyperpigmentation, and alopecia in the scalp with associated depigmentation, further suggested the possibility of DLE in this patient. It is not unusual, however, for patients with IVRB to demonstrate the co-localization of alopecia and vitiligo [5,6,7,8,9,10]. Furthermore, the preservation of follicular orifices and absence of cutaneous atrophy suggested a non-scarring process such as IVRB, rather than DLE. Vitiligo associated with alopecia areata was considered, but the co-localization of the alopecia and depigmentation support the diagnosis of IVRB.

Histopathology from the rim of hyperpigmentation of a representative patch demonstrated none of the features of DLE. Specifically, follicular plugging, reduplication of the basement membrane, hyperkeratosis, vacuolar alteration of the basal cell layer, and a dermal lymphocytic infiltrate of DLE were not present (Table 1). Furthermore, direct immunofluorescence demonstrated no immunoglobulin or complement deposition at the dermal-epidermal junction (lupus band test negative).

A second diagnosis was considered: cutaneous T-cell lymphoma, specifically, hypopigmented mycosis fungoides (MF). In a report published by Soro et al, both vitiligo and hypopigmented MF share similar histopathological features [11]. Distinguishing features include: 1) a complete absence of melanocytes in vitiligo; 2) dermal wiry fibrosis in hypopigmented MF; 3) a higher density band-like dermal lymphocytic infiltrate in hypopigmented MF; 4) atypical lymphocytes accumulating in the epidermis in several patterns, including linear, single cell, or the characteristic clustering of lymphocytes (Pautrier microabscesses) in MF [11,12] (Table 1).

Immunohistochemistry is sometimes helpful in the diagnoses of mycosis fungoides. Classical MF lesions are composed primarily of CD4+ T cells, whereas hypopigmented MF and vitiligo lesions both have a predominance of CD8+ T cells making it difficult to distinguish the two entities by immunohistochemistry alone [13]. In some patients a T cell gene rearrangement study is useful for the confirmation of MF, although sensitivity and specificity are both low [7,11]. The findings in our case were fully compatible with IVRB, and features of MF were not present.

The pathogenetic mechanism responsible for vitiligo, and specifically IVRB, remains unknown. Environmental triggers may induce or exacerbate an autoimmune reaction in genetically predisposed individuals. In this case, IVRB could have been initiated by phenolic cleansers used by the patient in janitorial work [14]. These chemicals are structurally similar to tyrosine, a precursor of melanin. These derivatives are converted to free radicals as they compete with tyrosine for hydroxylation by tyrosinase. Apoptosis results in the destruction of melanocytes producing the characteristic depigmented patches of vitiligo [15]. Our patient, however, denied any history of splashing chemicals on his arms and legs.

An interesting histopathologic feature in this case was the presence of eosinophils in the inflammatory infiltrate (Figure 2d). Eosinophils in the inflammatory infiltrate of patients with vitiligo have been described [16]. Eosinophils play a role in adaptive immunity, serving as an antigen-presenting cell through expression of major histocompatibility complex class II. A retrospective study detected eosinophils in biopsies taken from 10% of patients with non-segmental vitiligo from both the edges of active vitiliginous lesions and from normal skin on the ipsilateral uninvolved skin [16].

Because marginal vitiligo, DLE, and hypopigmented MF respond to distinct therapeutic modalities, a precise diagnosis is required to successfully treat these patients. Acute IVRB may be more likely to respond to treatment than chronic “burned out” vitiligo. The acute inflammatory nature of IVRB could be a clue that melanocytes left along the basal lamina of deep portions of hair follicles may not yet be completely destroyed. These areas form the nidus of repigmentation after treatment with superpotent topical steroids such as clobetasol [4]. In addition, UV-B laser, narrow band UV-B, and Psoralin and UV-A (PUVA) are contraindicated in DLE, but are efficacious in the treatment of both hypopigmented MF and vitiligo (Table 1). The effective treatment of DLE usually requires hydroxychloroquine or other systemic agents. Cutaneous T-cell Lymphoma is commonly treated with bexarotene or phototherapy such as narrow band UV-B or PUVA. Our patient rapidly responded to topical clobetasol to suppress the inflammatory response of vitiligo leading to repigmentation in all patches after eight weeks of therapy.

In conclusion, several conditions can present with depigmented patches including marginal vitiligo, DLE, and hypopigmented MF. Distinct histopathologic features permit these conditions to be easily differentiated. IVRB in our patient responded quickly to monotherapy with superpotent topical steroids.

## References

1. Sugita K, Izu K, Tokura Y. Vitiligo with inflammatory raised borders, associated with atopic dermatitis. *Clin Exp Dermatol*. 2006 Jan;31(1):80-2. [PMID: 16309491].
2. Tanioka M, Takahashi K, Miyachi Y. Narrowband ultraviolet B phototherapy for inflammatory vitiligo with raised borders associated with Sjogren's syndrome. *Clin Exp Dermatol*. 2008; 34:402-425. [PMID: 19120387].
3. Shin J, Lee J, Kim M, Kim D, Hann S, Oh S. New suggestive clue to the mechanism of vitiligo: Inflammatory vitiligo showing prominent leukocytoclasia at the erythematous rim. *J Dermatol*. 2013 Jun;40(6):488-90. [PMID: 23621749].
4. Verma SB. Inflammatory vitiligo with raised borders and psoriasiform histopathology. *Dermatol Online J*. 2005 Dec 1;11(3):13. [PMID: 16409909].
5. Ramot Y, Thomaidou E, Mali A, Zlotogorski A. An extraordinary colocalization of alopecia areata and vitiligo. *Int J Trichology*. 2010 July;2(2):108-9. [PMID: 21712899].
6. Adams BB, Lucky AW. Colocalization of alopecia areata and vitiligo. *Pediatr Dermatol*. 1999 Sep-Oct;16(5):364-6. [PMID: 10571834].
7. Ozcan D, Cevlik Aydoğan F. Concurrence of alopecia areata and vitiligo at the same anatomical site. *Australas J Dermatol*. 2012 Aug;53(3):e61-3. [PMID: 22881476].
8. Kumar S, Mittal J, Mahajan BB. Colocalization of Vitiligo and Alopecia Areata: Coincidence or Consequence?, *Int J Trichology*. 2013 Jan-Mar; 5(1): 50-52. [PMID: 23960402].
9. Krishnam AS, Saigal A, Adityan B. Alopecia areata - Vitiligo overlap syndrome: An emerging clinical variant. *Indian J Dermatol Venereol Leprol*. 2013 Jul-Aug;79(4):535-7. [PMID: 23760330].
10. Cho M, Cohen PR, Duvic M. Vitiligo and alopecia areata in patients with human immunodeficiency virus infection. *South Med J*. 1995 Apr;88(4):489-91. [PMID: 7716609].
11. Soro L, Gust A, Purcell S. Inflammatory vitiligo versus hypopigmented mycosis fungoides in a 58-year-old Indian female. *Indian Dermatol Online J*. 2013 Oct;4(4):321-5. [PMID: 24350017].
12. Furlan FC, Sanches JA. Hypopigmented mycosis fungoides: a review of its clinical features and pathophysiology. *An Bras Dermatol*. 2013 Nov-Dec; 88(6): 954–960. [PMID: 24474105].
13. El-Darouti MA, Marzouk SA, et al. Vitiligo vs. hypopigmented mycosis fungoides (histopathological and immunohistochemical study, univariate analysis). *Eur J Dermatol*. 2006 Jan-Feb;16(1):17-22. [PMID: 16436337].
14. Boissy R, Manga P. On the etiology of contact/occupational vitiligo. *Pigment Cell Res*. 2004 Jun;17(3):208-14. [PMID: 15140065].
15. Toosi S, Orlow S, Manga P. Vitiligo inducing phenols activate the unfolded protein response in melanocytes resulting in upregulation of IL6 and IL8. *J Invest Dermatol*. Nov 2012; 132(11): 2601-2609. [PMID: 22696056].
16. Anbar T, Abdel-Raouf S, Awad S. Presence of eosinophils in the inflammatory infiltrate of nonsegmental vitiligo: a retrospective study. *Clin Exp Dermatol*. 2009; 34: e496-497. [PMID: 19747329].
17. Duvic M, Rapini R, Hoots WK, Mansell PW. Human immunodeficiency virus-associated vitiligo: expression of autoimmunity with immunodeficiency?. *J Am Acad Dermatol*. 1987 Oct; 17(4):656-62. [PMID: 3668011].
18. Turan E, Sinem Bagci I, Turgut Erdemir A, Salih Gurel M. Successful treatment of generalized discoid lupus erythematosus with imiquimod cream 5%: a case report and review of the literature. *Acta Dermatovenerol Croat*. 2014;22(2):150-9. [PMID: 25102804].