

# Lichenoid inflammation of DSAP lesions following treatment with durvalumab, olaparib and paclitaxel: A potential diagnostic pitfall mimicking lichenoid drug eruptions associated with PDL-1 inhibitors

Anastasia Shakhbazova<sup>1</sup> BA, Brian Hinds<sup>2</sup> MD, Amanda F Marsch<sup>2</sup> MD

Affiliations: <sup>1</sup>School of Medicine, University of California Riverside, Riverside, California, USA, <sup>2</sup>Department of Dermatology, University of California San Diego, La Jolla, California, USA

Corresponding Author: Amanda F Marsch, 8899 University Center Lane, Suite 350, San Diego, CA 92121, Tel: 858-657-8322 Email: [amarsch@health.ucsd.edu](mailto:amarsch@health.ucsd.edu)

## Abstract

Disseminated superficial actinic porokeratosis (DSAP) is an uncommon skin condition that can be inherited or may occur sporadically with multiple red-brown, thin plaques in a photodistribution. The condition more often affects middle-aged women and is often recalcitrant to therapy. In rare literature reports, systemic medications can trigger exacerbation or promote inflammation in pre-existing lesions of DSAP. We present a novel case of chemotherapy-associated DSAP inflammation in a 66-year-old woman after triple therapy with durvalumab (PD-L1 inhibitor), olaparib (PARP inhibitor) and paclitaxel, showing similarities to primary lichen planus-like eruption from immune checkpoint inhibitors.

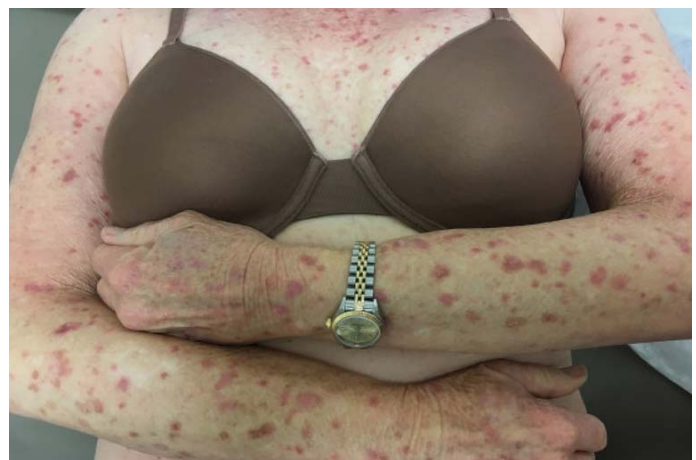**Keywords:** disseminated superficial actinic porokeratosis, lichenoid drug eruption, PDL-1 inhibitors, PD-1 inhibitors, taxol, olaparib

## Introduction

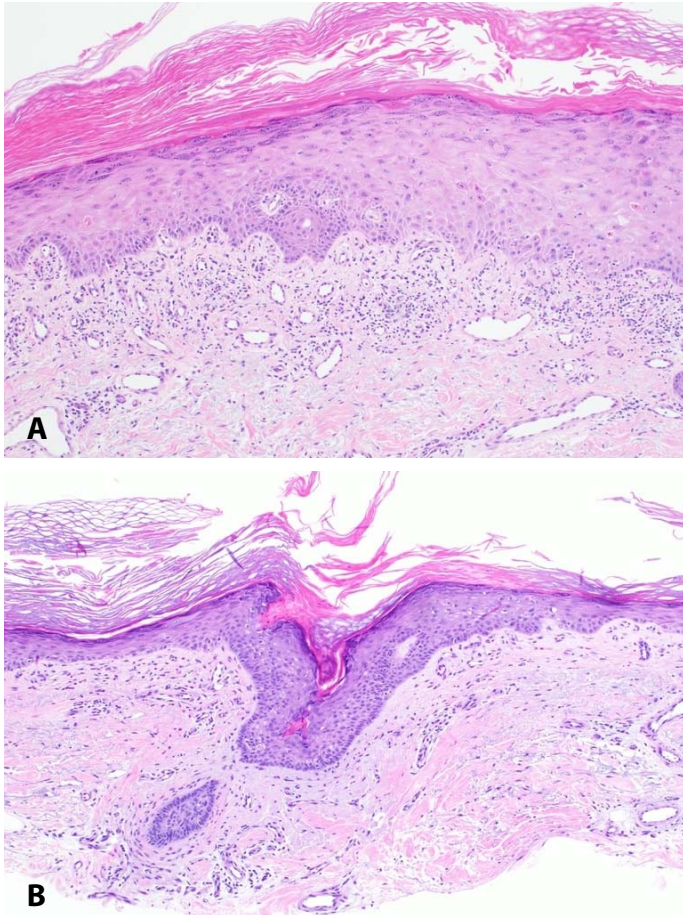
Disseminated superficial actinic porokeratosis, one of the most common variants of porokeratosis, is a skin condition with a genetic component that can be provoked with chronic sun exposure [1]. In this report, we describe a patient with longstanding disseminated superficial actinic porokeratosis (DSAP) who developed Her2/Neu-positive invasive ductal carcinoma of the left breast and subsequently

underwent treatment with durvalumab, olaparib and paclitaxel. Durvalumab is an anti-programmed cell death ligand 1 (PD-L1) antibody currently FDA-approved for the treatment of advanced urothelial carcinoma; it is also used in other solid tumors as an adjuvant with platinum-containing chemotherapy. Olaparib is a poly ADP-ribose polymerase (PARP) inhibitor (an enzyme involved in DNA repair) for ovarian breast and prostate cancer.

Although inflammation of pre-existing DSAP has been described previously in the literature, namely with temozolomide (an alkylating agent) and



**Figure 1.** Chemotherapy-induced inflammation of disseminated superficial actinic porokeratosis (DSAP): Exam revealed a numerous amount of scattered inflamed appearing reddish-brown thin papules with collarettes of scale distributed on the chest, arms and legs occurring 1 week after initiation of chemotherapy.



**Figure 2.** H&E histopathology. Dysmaturation of keratinocytes is evident in the spinous layer and singly necrotic keratinocytes are present throughout the epidermis akin to a toxic erythema-like interface reaction, 100 $\times$ . **B)** A cornoid lamellae is emanating from an infundibular ostium, 100 $\times$ .

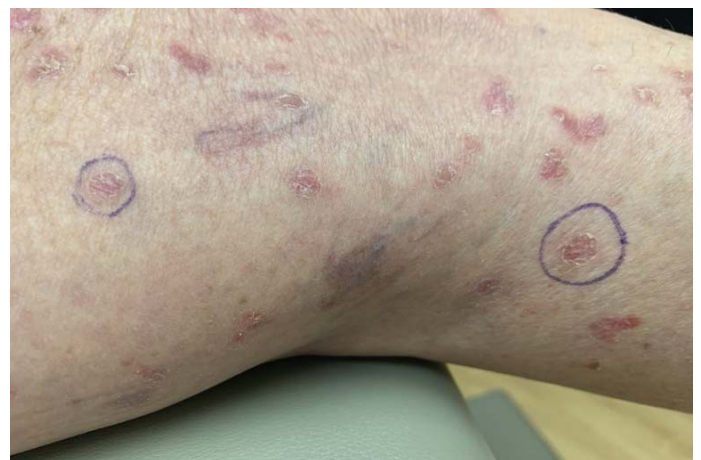palifermin (a keratinocyte growth factor), this unusual phenomenon has yet to be reported with PD-L1 inhibitors or taxols. Clinical documentation of pre-existing DSAP lesions is key to avoid confusion with lichen planus-like eruptions associated with immune checkpoint inhibitors. Medical practitioners should be aware of the possibility of DSAP lesion exacerbation after the initiation of chemotherapy to avoid confusion and to prevent unnecessary discontinuation of chemotherapy.

### Case Synopsis

A 66-year-old woman with a 20-year history of DSAP, basal cell carcinoma and recently diagnosed Her2/Neu-positive invasive ductal carcinoma of the left breast was referred by her oncologist with

“worsening rash.” In the past few decades, she had visited the dermatology clinic for DSAP lesional treatment with topical imiquimod, topical 5-fluorouracil, and photodynamic therapy with variable improvement, although relapsed consistently after treatment cessation.

One week after initiating treatment with durvalumab/olaparib/paclitaxel, the previously documented lesions of DSAP became inflamed and deeply erythematous (**Figure 1**). Interestingly, she denied pruritus or pain. Review of systems was negative for fevers, chills, joint pain, photosensitivity, blisters, or oral lesions. Physical examination revealed scattered red-brown, thin papules and plaques with thread-like scale at the perimeter, widely distributed on the chest, arms, and legs with sparing of the back, abdomen, head, palms, and soles (**Figure 1**). Punch biopsy from the right thigh showed variable acanthosis and keratinocyte dysmaturation with random bizarre nuclei in concert with dyskeratotic keratinocytes (**Figure 2A**). A subtle tier of parakeratosis was also apparent. There was initial concern for toxic erythema of chemotherapy or PD-1-induced lichenoid drug eruption purely based on histopathologic findings. Additional shave biopsies were taken at a follow-up appointment in-between the patient’s chemotherapy cycles and showed classic coronoid lamellae on several sections without keratinocyte dysmaturation (**Figure 2B**). Three weeks after her first chemotherapy cycle, all



**Figure 3.** Between chemotherapy cycles (given every 6 weeks), the patient’s skin lesions appeared less inflamed and resembled her baseline exam, showing light erythematous to pink thin papules with a distinctive peripheral keratotic ridge.

**Table 1.** Prior reports of chemotherapy-induced inflammation of disseminated superficial actinic porokeratosis (DSAP) or chemotherapy-induced DSAP.

Medication	Pre-existing DSAP	Disease being treated	Distribution	Bx	Age/Sex	Follow-up	Reference
Palifermin	Yes	CNS lymphoma	Forearms & lower legs	No	68M	Sustained improvement	[4]
Temozolomide	Yes	Glioblastoma	Forearms	Yes-Coronoid lamella	47M	NA	[5]
Certolizumab/ Methotrexate	No	Psoriasis and psoriatic arthritis	Trunk & extremities	Yes- Coronoid lamella	62F	Resolved 6 weeks after d/c certolizumab	[6]
Durvalumab/ Olapartib/ Paclitaxol	Yes	BRCA	Upper & lower extremities	Yes- Coronoid lamella and lichenoid inflammation	66F		Present case

lesions resembled the patient's baseline exam, showing light erythematous to pink thin papules with a distinctive peripheral keratotic ridge (**Figure 3**). However, her DSAP lesions continued to flare after each subsequent cycle of chemotherapy. A diagnosis of chemotherapy-induced inflammation of DSAP was rendered based on prior history, documented distribution of lesions in the same areas as her prior DSAP, and compilation of histopathologic findings. The patient was treated with topical emollients and counseled on photoprotective measures.

## Case Discussion

The pathogenesis of porokeratosis is believed to relate to clonal proliferation of atypical keratinocytes [2]. Onset of DSAP is common around middle adulthood and among the six variants of porokeratosis, it tends to be the most generalized variant. The lesions are regarded as precancerous with 7.5% to 10% transformation risk to squamous cell carcinoma or basal cell carcinoma [3, 4]. The skin manifestations commonly consist of pink-brown annular keratotic papules and plaques that usually occur on sun-exposed areas of the body, sparing the palms and soles [1]. Histologically, the coronoid lamella is the microscopic hallmark for diagnosis [2]. The current treatment for DSAP includes imiquimod,

ingenol mebutate, cryosurgery, photodynamic therapy, and topical or systemic therapy with retinoids, although all these treatments have limited success [1].

Chemotherapy-induced inflammation of actinic keratoses has been reported with several medications, including paclitaxel, 5-fluorouracil, doxorubicin, dacarbazine, vincristine, carboplatin, panitumumab and capecitabine [1]. However, chemotherapy-induced inflammation of DSAP has been rarely reported (**Table 1**) in independent reports with temozolomide and palifermin [4, 5]. Of note, treatment with the adjuvant palifermin during chemotherapy in a patient with DSAP eventually led to sustained clinical improvement and/or regression of DSAP lesions [4]. There has been one report of new onset DSAP after initiation of methotrexate and certolizumab pegol for psoriatic arthritis; the lesions regressed after certolizumab was discontinued [6]. Lichenoid inflammation commonly occurs in lesions of DSAP. The keratinocyte dysmaturation observed in our case is unique, as prior reports have not described "toxic erythema of chemotherapy-like" reaction in concert with lichenoid interface reaction. We attribute the dysmaturation seen on histopathology to the effects of taxol, although the lymphocytic infiltrate could be stemming from taxol, PDL-1 inhibitor, or PARP inhibitor.

On balance, we suspect the PDL-1 agent to be the most intriguing culprit, based on overlap with prior immune checkpoint inhibitor-associated lichenoid drug eruptions. In the current case, the lack of a clear-cut coronoid lamella in the first sample (despite level sections) led to additional sampling because of overall concern for a lichenoid drug eruption. Conventional lichenoid drug eruption was excluded based on the fact that the patient's subsequent biopsies displayed a coronoid lamella and all skin lesions only involved sites of prior DSAP involvement. The presence of lichenoid inflammation on histopathology could have been further misconstrued as eruptive DSAP with concomitant lichenoid drug eruption if the patient did not have prior clinical documentation of DSAP. Given that most oncologists are unfamiliar with DSAP, this could be a potential pitfall in managing cancer patients with sun-damaged skin who are being treated with immunotherapy.

## References

1. Skupsky H, Skupsky J, Goldenberg G. Disseminated superficial actinic porokeratosis: a treatment review. *J Dermatolog Treat.* 2012;23:52-6. [PMID: 20964569].
2. Shumack SP, Commens CA. Disseminated superficial actinic porokeratosis: a clinical study. *J Am Acad Dermatol.* 1989;20:1015-22. [PMID: 2754051].
3. Shoimer I, Robertson LH, Storwick G, et al. Eruptive disseminated porokeratosis: a new classification system. *J Am Acad Dermatol.* 2014;71:398-400. [PMID: 25037793].
4. Howard M, Hall A. A report and follow up of a patient with disseminated superficial actinic porokeratosis (DSAP) undergoing novel systemic treatment with palifermin (a keratinocyte growth factor) during chemotherapy. *Dermatol Online J.* 2018;24. [PMID: 29630163].
5. Lee DE, Kaffenberger BH, Gru AA, et al. Temozolomide-induced inflammation of disseminated superficial actinic porokeratosis. *Dermatol Online J.* 2018;24. [PMID: 29634886].
6. Brauer JA, Mandal R, Walters R, et al. Disseminated superficial porokeratosis. *Dermatol Online J.* 2010;16:20. [PMID: 21163171].

## Conclusion

A patient treated with durvalumab/olaparib/paclitaxel experienced an exacerbation of her DSAP lesions. Histopathology showed lichenoid inflammation which could have been misinterpreted as a lichenoid drug eruption. Her pre-existing history of DSAP, distribution localized to previously involved sites of DSAP, and the presence of a coronoid lamella histopathologically helped to confirm the diagnosis. Medical practitioners should be aware of the possibility of DSAP lesion exacerbation after the initiation of chemotherapy with durvalumab/olaparib/paclitaxel to prevent misdiagnosis of lichenoid drug eruption and the unnecessary discontinuation of the chemotherapeutic intervention.

## Potential conflicts of interest

The authors declare no conflicts of interests.