

**Case Presentation**

**Netherton syndrome with ichthyosis linearis circumflexa and trichorrhexis invaginatam**

**Elise Ng MD, Christopher S. Hale MD, Shane A. Meehan MD, and David E. Cohen MD, MPH**

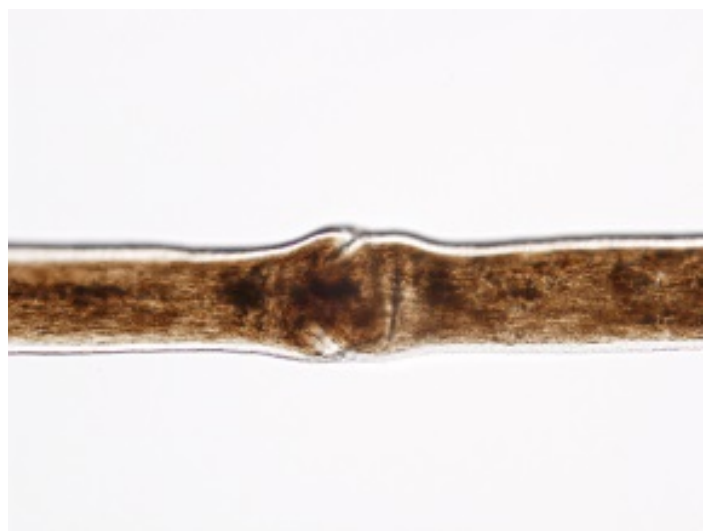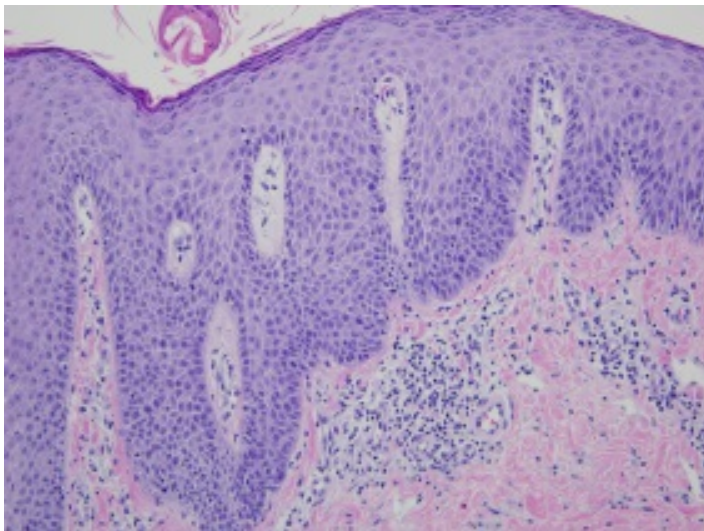
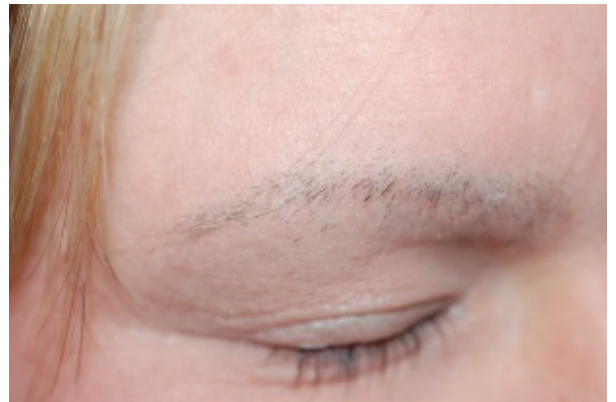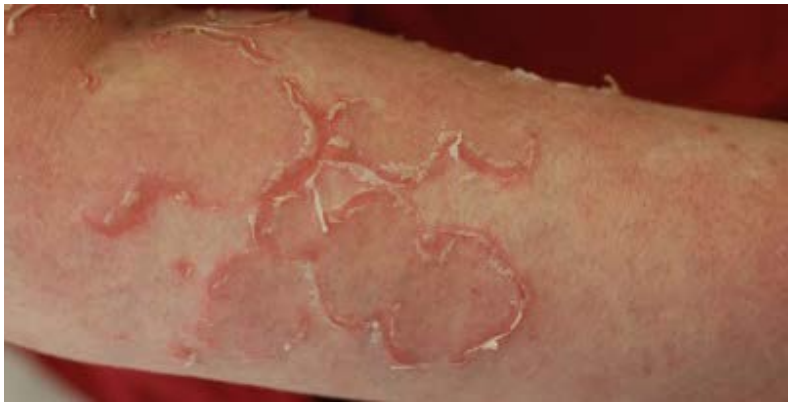**Dermatology Online Journal 20 (12): 7**

**New York University School of Medicine**

**Special Guest Editor: Nicholas A. Soter, MD**

**Abstract**

Netherton syndrome is a rare, autosomal recessive disorder that is characterized by congenital ichthyosis, trichorrhexis invaginata, and atopic diathesis. Ichthyosis presents at birth with erythroderma and subsequently evolves into ichthyosis linearis circumflexa; hair shaft abnormalities tend to present later. The disorder is caused by loss-of-function mutations in the SPINK5 (serine protease inhibitor Kazal-type 5) gene that encodes LEKTI (lympho-epithelial Kazal-type related inhibitor), which is a protease inhibitor that counteracts epidermal proteases involved in desquamation. Use of topical medications is limited by potential for systemic absorption and toxicity in the setting of a defective skin barrier. Therapeutic options include topical glucocorticoids and retinoids, oral retinoids, and narrowband ultraviolet B phototherapy. Topical tacrolimus has been shown to be efficacious and may be used safely with careful laboratory monitoring.



## Case synopsis

**History:** A 24-year-old woman presented to NYU Dermatology Associates for evaluation of a skin condition of her entire body. The patient had a history of generalized redness and scale of her skin since birth that had been treated with emollients, topical glucocorticoids, and tazarotene cream. However, her condition started to flare more frequently despite the above therapies. Prior to presentation, she had recently discontinued a regimen of twice daily topical glucocorticoid applications because she was requiring large amounts with only little improvement and had started to note nausea, dizziness, excessive weight gain, and new striae. In addition to her skin complaints, she also reported coarse, brittle hair. She had a history of urinary tract infections and an allergy to sulfonamide. Her medications included amoxicillin and oral contraceptive pills. There was no family history of similar dermatologic conditions.

**Physical examination:** The patient was overweight and had a Cushingoid appearance. On the trunk and extremities, there were widespread, polycyclic, serpiginous, erythematous plaques with double-edged scale. Striae were noted in flexural areas. On the scalp, there were light brown, coarse, brittle, straight hairs of various lengths. Eyebrow hairs were very sparse and less than 5mm in length.

**Laboratory data:** A complete blood count, comprehensive metabolic panel, lipid panel, thyroid stimulating hormone, and 25-hydroxy vitamin D were normal. IgE level was elevated at 14884 IU/ml (normal range 0 to 100 IU/ml). IgM and IgA were normal.

**Histopathology:** Psoriasiform epidermal hyperplasia with spongiosis and a perivascular infiltrate of lymphocytes and occasional eosinophils was present. A trichogram shows nodal swellings, in which there is invagination of the distal hair into the proximal end in a ball-and-glove configuration.

## Discussion

**Diagnosis:** Netherton syndrome with ichthyosis linearis circumflexa and trichorrhexis invaginata

**Comment:** Netherton syndrome, which was initially described by Comel in 1949 and Netherton in 1958, is a rare, autosomal recessive disorder, which is characterized by congenital ichthyosis, trichorrhexis invaginata (bamboo hair), and atopy. It typically presents in neonates with generalized scale and erythroderma, which may lead to hypernatremic dehydration, hypothermia, failure to thrive, and infection. The ichthyosis usually evolves gradually into serpiginous, erythematous plaques that are bordered by double-edged scale, which is termed ichthyosis linearis circumflexa [1]. Trichorrhexis invaginata is the pathognomonic hair shaft defect and may vary greatly in extent and severity. Hair shaft abnormalities are often absent initially and tend to present after ten months of age [2]. Atopic manifestations include rhinitis, atopic dermatitis, various food allergies, hypereosinophilia, and elevated IgE levels, which usually range from 100 to >10,000 IU/ml [3].

Loss-of-function mutations in the *SPINK5* (serine protease inhibitor Kazal-type 5) gene, which encodes for the serine protease inhibitor LEKTI (lympho-epithelial Kazal-type related inhibitor), cause Netherton syndrome [4]. LEKTI, which originally was described in thymus epithelium, is a protein that is secreted into the extracellular spaces of the superficial stratum granulosum, where it inhibits epidermal proteases that are involved in desquamation, in particular kallikrein (KLK) 5 and KLK7. Deficiency of LEKTI, as observed in Netherton syndrome, leads to unopposed kallikrein proteolysis of intercellular adhesion molecules in the stratum corneum, which include desmoglein 1. This process results in the severely defective skin barrier that is observed [5]. In one study, severity of the cutaneous phenotype was correlated directly with the magnitude of serine protease activation and inversely with residual LEKTI expression [6]. Kallikreins also are thought to be involved in the production of inflammatory cytokines that create a pro-allergic Th2 microenvironment. Their unrestrained activity in the absence of LEKTI, when combined with the increased permeability to exogenous agents that a defective skin barrier causes, may explain the atopic diathesis that has been described in patients [7]. To date, more than 60 distinct loss-of-function mutations in *SPINK5* have been identified in patients with Netherton syndrome [8, 9]. Recent studies also have linked polymorphisms in *SPINK5* to atopic disease [10-12].

Up to 18% of cases of congenital erythroderma, which is defined as persistent generalized skin erythema that affects at least 90% of the body surface, are attributed to Netherton syndrome [1]. Other causes of neonatal erythroderma from which Netherton syndrome must be distinguished include ichthyoses, such as congenital ichthyosiform erythroderma; primary immunodeficiency syndromes, such as Omenn syndrome; erythrodermic psoriasis; and, very rarely, metabolic disorders; congenital cutaneous candidiasis; or drug-related erythroderma [2]. In addition to the clinical presentation and elevated IgE, the diagnosis of Netherton syndrome is supported by light microscopic examination of a skin biopsy specimen and hairs, which should be cut rather than plucked. Histopathologic features often show psoriasiform acanthosis, hypogranulosis, parakeratotic hyperkeratosis, and occasionally spongiosis that progresses to microvesiculation. Specimens also may be stained for a polyclonal antibody to LEKTI.

Examination of hairs shows trichorrhexis invaginata, which appears as telescoping of the distal hair shaft into the proximal segment. This change is thought to occur secondary to the incomplete conversion of –SH to S-S bonds, which result in weak keratin crosslinks. Other hair abnormalities include trichorrhexis nodosa, pili torti, and helical hairs. Genetic testing also could be used for diagnosis but is not currently widely available [1, 13].

Treatment of Netherton syndrome is complicated by the potential for systemic toxicity from increased absorption of topical medications through an impaired skin barrier. Topical emollients, keratolytics, glucocorticoids, tretinoin, and calcipotriol have been used with variable efficacy [14-16]. However, use of topical glucocorticoids is limited by the risk of Cushing syndrome after extensive use, which has been reported in Netherton syndrome [17]; the use of tretinoin frequently is limited by skin irritation. Success with oral retinoids has been reported, but their long-term use also is limited by a toxicity profile that includes hypertriglyceridemia, hepatitis, and diffuse idiopathic skeletal hyperostosis [18].

More recent reports have focused on narrowband ultraviolet B phototherapy and topical calcineurin inhibitors, both of which have been shown to produce improvement in certain cases [19-21]. Notably, Netherton syndrome currently is listed as a contraindication for topical tacrolimus use owing to concern for increased absorption. Indeed, one paper reported three cases of appreciable systemic absorption within or even above the therapeutic trough range for oral tacrolimus in organ transplant recipients [22]. However, multiple subsequent reports demonstrated successful treatment with low-to-undetectable tacrolimus blood levels with the use of more dilute formulations. In this patient, who failed topical glucocorticoids and could not tolerate phototherapy or tretinoin, topical tacrolimus was used successfully and safely with close laboratory monitoring [23-26].

## References

1. Sun J, Linden K. Netherton syndrome: a case report and review of the literature. *Int J Dermatol* 2006; 45: 693 [PMID: 16796630]
2. Fraitag S, Bodemer C. Neonatal erythroderma. *Curr Opin Pediatr* 2010; 22: 438 [PMID: 20616730]
3. Gabriele R, Ringpfeil F. Comel-Netherton syndrome. In: Bologna JL, *et al*, eds. *Dermatology*, 3<sup>rd</sup> ed. Philadelphia: Saunders; 2012: 857
4. Chavanas S, *et al*. Mutations in SPINK5, encoding a serine protease inhibitor, cause Netherton syndrome. *Nat Genet* 2000; 25: 141 [PMID: 10835624]
5. Ishida-Yamamoto A, *et al*. LEKTI is localized in lamellar granules, separated from KLK5 and KLK7, and is secreted in the extracellular spaces of the superficial stratum granulosum. *J Invest Dermatol* 2005; 124: 360 [PMID: 15675955]
6. Hachem J, *et al*. Serine protease activity and residual LEKTI expression determine phenotype in Netherton syndrome. *J Invest Dermatol* 2006; 126: 1609 [PMID: 16601670]
7. Furio L, Havnianian A. When activity requires breaking up: LEKTI proteolytic activation cascade for specific proteinase inhibition. *J Invest Dermatol* 2011; 131: 2169 [PMID: 21997416]
8. Bitoun E, *et al*. Netherton syndrome: disease expression and spectrum of SPINK5 mutations in 21 families. *J Invest Dermatol* 2002; 118: 352 [PMID: 11841556]
9. Lacroix M, *et al*. Clinical exexpression and new SPINK5 splicing defects in Netherton syndrome: unmasking a frequent founder synonymous mutation and unconventional intronic mutations. *J Invest Dermatol* 2012; 132: 575 [PMID: 22089833]
10. Liu Q, *et al*. A functional polymorphism in the SPINK5 gene is associated with asthma in a Chinese Han population. *BMC Med Genetic* 2009; 17: 59 [PMID: 19534795]
11. Kato A, *et al*. Association of SPINK5 gene polymorphisms with atopic dermatitis in the Japanese population. *Br J Dermatol* 2003; 148: 665 [PMID: 12752122]
12. Walley A, *et al*. Gene polymorphism in Netherton and common atopic disease. *Nat Genet* 2001; 29: 175 [PMID: 11544479]
13. Seraly M, *et al*. Netherton syndrome revisited. *Pediatr Dermatol* 1994; 11: 61 [PMID: 8170853]
14. Godic A, Dragos V. Successful treatment of Netherton's syndrome with topical calcipotriol. *Eur J Dermatol* 2004; 14: 115 [PMID: 15197002]
15. Happle R, *et al*. Retinoids in disorders of keratinization: their use in adults. *Dermatologica* 1987; 175: 107 [PMID: 2961628]
16. Wehr R, *et al*. Effective treatment of Netherton's syndrome with 12% lactate lotion. *J Am Acad Dermatol* 1988; 19: 140 [PMID: 3403739]
17. Halverstam C, *et al*. Cushing syndrome from percutaneous absorption of 1% hydrocortisone ointment in Netherton syndrome. *Pediatr Dermatol* 2007; 24: 42 [PMID: 17300648]
18. Lazaridou E, *et al*. Netherton's syndrome: successful treatment with isotretinoin. *J Eur Acad Dermatol Venereol* 2009; 23: 210 [PMID: 18482312]
19. Kaminska E, *et al*. Narrowband UVB phototherapy as a novel treatment for Netherton syndrome. *Photodermatol* 2012; 28: 162 [PMID: 22548400]
20. Maatouk I, *et al*. Narrowband ultraviolet B phototherapy associated with improvement in Netherton syndrome. *Clin Exp Dermatol* 2012; 37: 364 [PMID: 22582910]
21. Suga Y, *et al*. A case of ichthyosis linearis circumflexa successfully treated with topical tacrolimus. *J Am Acad Dermatol* 2000; 42: 520 [PMID: 10688732]

22. Allen A, *et al.* Significant absorption of topical tacrolimus in 3 patients with Netherton syndrome. *Arch Dermatol* 2001; 137: 747 [PMID: 11405764]
23. Bens G, *et al.* Topical treatment of Netherton's syndrome with tacrolimus ointment without significant systemic absorption. *Br J Dermatol* 2003; 149: 224 [PMID:12890237]
24. Saif G, Al-Khenaizan. Netherton syndrome: successful use of topical tacrolimus and pimecrolimus in four siblings. *Int J Dermatol* 2007; 46: 290 [PMID: 17343588]
25. Shah K, Yan A. Low but detectable serum levels of tacrolimus seen with the use of very dilute, extemporaneously compounded formulations of tacrolimus ointment in the treatment of patients with Netherton syndrome. *Arch Dermatol* 2006; 112: 184 [PMID: 17043199]
26. Yan A, *et al.* The safety and efficacy of pimecrolimus, 1%, cream for the treatment of Netherton syndrome. *Arch Dermatol* 2010; 146: 57 [PMID: 20083693]