

Case presentation

Pressure-induced isomorphmic sclerodermoid graft-versus-host disease from brassiere underwire and tight-fitting watch.

Colton Nielson, Garth R Fraga MD, Ryan Fischer MD, Anand Rajpara MD

Dermatology Online Journal 21 (11): 10

University of Kansas Medical Center

Correspondence:

Colton Nielson
University of Kansas Medical Center
cnielson@kumc.edu

Abstract

Sclerodermoid chronic graft-versus-host disease (scGVHD) is a rare form of cGVHD with an estimated prevalence of 3% to 11% in patients receiving allogeneic bone marrow transplants. scGVHD is believed to be an immune-mediated response characterized by aberrant T-cell function and dysregulation of tyrosine kinase cascades. Published literature on scGVHD is still limited and the mechanisms are yet to be fully understood. Thus, successful treatment of scGVHD remains largely unknown and many current options are hindered by potential side effects. This case provides an example of scGVHD localizing to areas of trauma and friction as a potential mechanism behind scGVHD and provides several case reports that document similar findings.

Keywords: scGVHD, Sclerodermoid GVHD, Isomorphmic response

Introduction

Graft-versus-host disease (GVHD) is a major complication of allogenic, as well as autologous stem cell transplantations. It affects nearly 50% of patients post-transplant [1]. Skin and mucous membranes are affected in more than 90% of chronic GVHD cases and skin is often the earliest affected organ [1]. Chronic graft-versus-host disease (cGVHD) can mimic skin lesions observed during lichen planus (lichenoid GVHD), lichen sclerosus, or morphea (sclerodermoid GVHD) [1]. This case involves a woman with scGVHD localizing to areas of friction.

Case synopsis

A 68-year-old woman with a significant past medical history of non-Hodgkin's lymphoma with autologous peripheral stem cell transplants in 2007 and 2013, presented to the dermatology clinic with a three-month history of an indurated violaceous eruption over the left wrist, abdomen, neck, and inframammary areas. The left wrist eruption corresponded to the area where she wore a tight watch. The inframammary areas corresponded to where the underwire of her brassiere contacted the skin. The patient described an occasional burning pain in the areas of the eruption. Review of systems was positive for myalgias and arthralgias in the forearms, skin color change across the forearms, neck, umbilicus, and breasts, and a general feeling of nervousness/anxiety. Physical exam revealed indurated, hyperpigmented/violaceous plaques on left ventral forearm (Figure 1), suprapubic area, and under both breasts (especially the left inframammary area) (Figure 2).

The clinical differential diagnosis included sclerodermoid graft-versus-host disease and morphea. A 4-mm punch biopsy was obtained, which demonstrated lichenoid interface dermatitis and papillary fibrosis (Figure 3). The dermal collagen bundles were swollen and associated with loss of the adipose tissue around the eccrine gland (Figure 4). The subcutaneous fat exhibited

liquefactive fat necrosis (Figure 5). There was sparse perivascular, adnexal, and lobular lymphoplasmacytic inflammation (Figure 5). Given these biopsy results, we diagnosed sclerodermoid graft-versus-host disease.

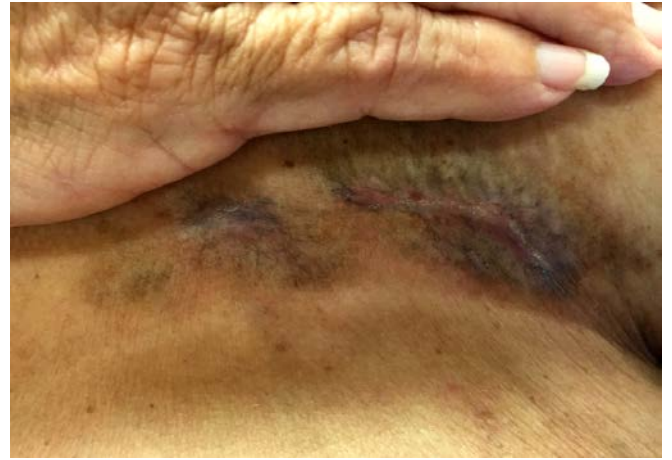
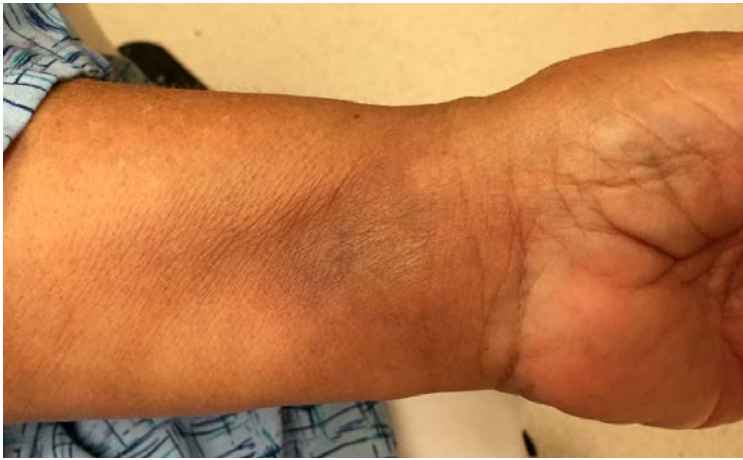

Figure 1. Indurated, hyperpigmented and violaceous plaques on left ventral forearm. **Figure 2.** Indurated, hyperpigmented and violaceous plaques under left breast

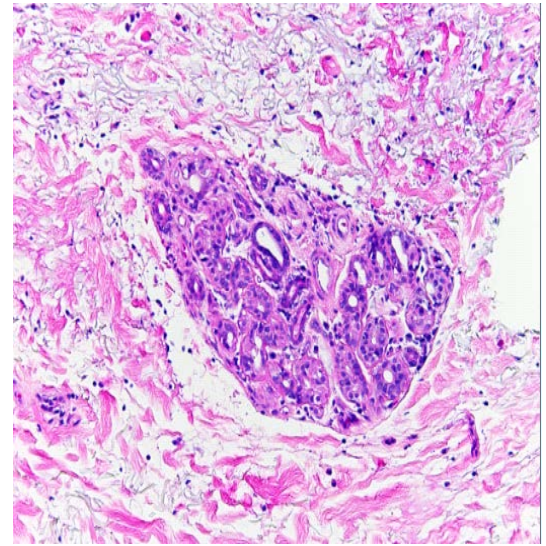
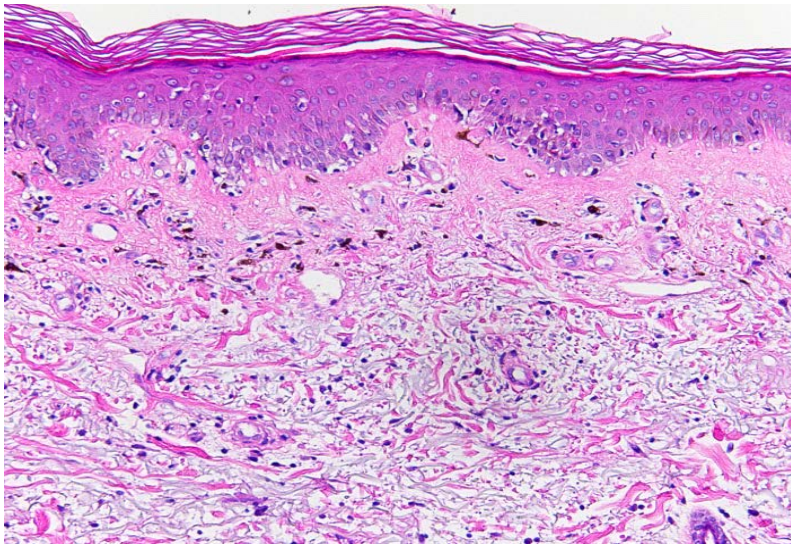


Figure 3. Biopsy demonstrates burned out lichenoid interface dermatitis with basal vacuolization, papillary fibrosis and superficial melanoderma (H and E, 100X original magnification) **Figure 4.** There is loss of the peri-eccrine adipose tissue (H and E, 100X original magnification)

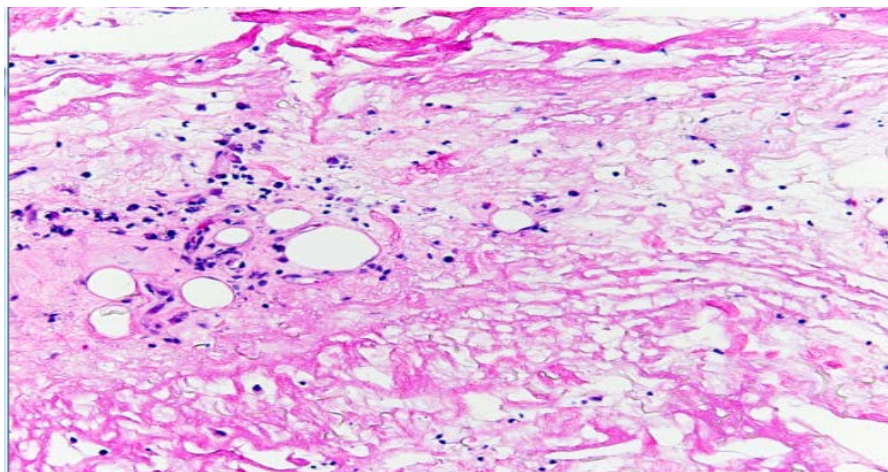


Figure 5. Liquefactive fat necrosis of the hypodermis with sparse lymphoplasmacytic inflammation (H and E, 100X original magnification).

The patient was prescribed topical clobetasol ointment, as she preferred to start treating in a conservative manner. Given the diagnosis of GVHD, she continued to follow with the bone marrow transplant service. She was subsequently started on imatinib for cGVHD and meloxicam for joint pains related to contractures. Two weeks into treatment, the patient developed tingling and

"electricity-like" pain in her fingers, so the imatinib was discontinued and prednisone was started. After two weeks of treatment with prednisone, our patient did note some improvement in the induration and pain. We also informed her to avoid tight-fitting clothes, undergarments, and accessories.

Discussion

Sclerodermoid chronic graft-versus-host disease (scGVHD) is a rare form of cGVHD with an estimated prevalence of 3% to 11% in patients receiving allogeneic bone marrow transplants [2, 3, 5]. scGVHD is believed to be an immune-mediated response characterized by aberrant T-cell function and dysregulation of tyrosine kinase cascades [6]. Recently, the profibrotic cytokine transforming growth factor B and stimulatory autoantibodies against the platelet-derived growth factor receptor have been implicated in the pathogenesis of scGVHD [6].

scGVHD may be localized or generalized. It often presents as morphea-like plaques with induration, loss of skin markings and appendages, joint contractures, pain, chronic ulceration, generalized wasting, and pyogenic infection [1,4]. scGVHD can eventually progress to generalized scleroderma or present with lichen-sclerosus-like features in a genital or extra genital distribution [1,4].

Localization of scGVHD may occur after various forms of skin injury [7]. The Koebner isomorphic response describes the appearance of a skin lesion at a site of injury that is morphologically similar to an existing skin disease [7, 8]. In 1995, Wolf et al defined the term isotopic as the occurrence of a new, unrelated disease in the same location as a previously healed disease [7, 8]. Recognition of this phenomenon may be helpful for the early diagnosis of sclerotic disease [7]. Interestingly, morphea and lichen sclerosus, two disorders that resemble cGVHD, are also associated with an isomorphic response, suggesting a common pathogenesis [7, 8].

The mechanism by which relatively minor external trauma triggers the complex immunologic cascade that results in skin fibrosis is unclear. Recently, total body irradiation has been proposed as an important risk factor for the subsequent development of scGVHD [9]. Specific mechanisms that may account for scGVHD after irradiation include: production of type I interferon (alpha/beta), radiotherapy produced elevation of interferon gamma (which along with interferon-inducible chemokines is upregulated in scGVHD skin), and promotion and maintenance of T-cell cytotoxicity secondary to local production of interferon and downstream factors [9].

Cutaneous cGVHD has been described not only at the location of a previous unrelated and healed skin disease, as an isotopic response, but also at the cutaneous site of earlier exposure to radiotherapy or ultraviolet radiation as an isoradiotopic response in a cutaneous immunocompromised district (ICD) [9]. An ICD is a skin area more vulnerable than the rest of the body for genetic or acquired reasons [10]. Its vulnerability may be due to local dysregulation of the immune control, which often facilitates the local onset of immunity related eruptions or skin disorders [10]. Regardless, the immunologic behavior of an ICD is different from that of the rest of the body [10].

Cohen describes a patient who developed GVHD localized to areas of skin friction from the waistband of his pants after previously receiving two stem cell transplants [9]. Isomorphic chronic cutaneous GVHD has been described in many more patients with sclerotic-type GVHD skin lesions [9]. Martires et al. recently provided four case reports describing the development of scGVHD at the site of skin injuries (ionizing radiotherapy, repeated needle sticks, central catheter site, and varicella-zoster virus infection) [7]. Vassallo et al. provided four more case reports, two children and two adults each with a prior history of cutaneous cGVHD [11]. The photo-induced cutaneous manifestations occurred within a few hours from the sun/UVB exposure and were characterized by severe erythematous rash on sun-exposed areas. In the narrow-band UVB treated child case, the development of blisters was observed [11]. In addition, cGVHD with sclerotic-type skin lesions has been observed to occur at the healed sites of prior acute GVHD [9]. Each case suggests that the phenomenon of cGVHD at the site of skin injury may provide an important clue to the pathogenesis of cutaneous cGVHD [7].

Conclusions

Published literature on scGVHD is still limited and the mechanisms are yet to be fully understood. Thus, successful treatment of scGVHD remains largely unknown and many current options are hindered by potential side effects. This case provides an example of scGVHD localizing to areas of trauma and friction as a potential mechanism behind scGVHD and provides several case reports that document similar findings. It is our hope that by working to unveil the intricate mechanisms behind scGVHD, successful treatment can be developed in the future.

References

1. Osmola-Mankowska, A., W. Silny, A. Danczak-Pazdrowska, A. Polanska, K. Olek-Hrab, A. Sadowska-Przytocka, R. Zaba, and D. Jenerowicz. "Assessment of Chronic Sclerodermoid Graft-versus-Host Disease Patients, Using 20 MHz High-frequency Ultrasonography and Cutometer Methods." *Skin Res Technol* (2012): E417-422. Web. [PMID: 22882597]
2. Häusermann, Peter, Roland B. Walter, Jörg Halter, Barbara C. Biedermann, André Tichelli, Peter Itin, and Alois Gratwohl. "Cutaneous Graft-versus-Host Disease: A Guide for the Dermatologist." *Dermatology* 216.4 (2008): 287-304. Web. [PMID: 18230976]
3. Wetzig, T., M. Sticherling, J-C Simon, U. Hegenbart, D. Niederwieser, and H. K. Al-Ali. "Medium Dose Long-wavelength Ultraviolet A (UVA1) Phototherapy for the Treatment of Acute and Chronic Graft-versus-host Disease of the Skin." *Bone Marrow Transplantation* 35.5 (2005): 515-19. Web. [PMID: 15665847]
4. Currie, Donald M., Gudbjorg Kristin Ludvigsdottir, Carlos A. Diaz, and Naynesh Kamani. "Topical Treatment of Sclerodermoid Chronic Graft vs. Host Disease." *American Journal of Physical Medicine & Rehabilitation* 81.2 (2002): 143-49. Web [PMID: 11807351]
5. Skert, Cristina, Francesca Patriarca, Alessandra Sperotto, Michela Cerno, Carla Fili, Francesco Zaja, Raffaella Stocchi, Antonella Geromin, Daniela Damiani, and Renato Fanin. "Sclerodermatous Chronic Graft-versus-host Disease after Allogeneic Hematopoietic Stem Cell Transplantation: Incidence, Predictors and Outcome." *Haematologica* (2006): n. pag. Web. PMID: [16461315]
6. Lazar, Jozef, Tasneem Poonawalla, and Joyce M.c.Teng. "A Case of Sclerodermatous Graft-versus-Host Disease Responsive to Imatinib Therapy." *Pediatric Dermatology* 28.2 (2011): 172-75. Web. [PMID: 21504445]
7. Martires, K. J., K. Baird, D. E. Citrin, F. T. Hakim, S. Z. Pavletic, and E. W. Cowen. "Localization of Sclerotic-type Chronic Graft-vs-Host Disease to Sites of Skin Injury: Potential Insight Into the Mechanism of Isomorphic and Isotopic Responses." *Archives of Dermatology* 147.9 (2011): 1081-086. Web. [PMID: 21931046]
8. Patel, A. R., S. Z. Pavletic, M. L. Turner, and E. W. Cowen. "The Isomorphic Response in Morphealike Chronic Graft-vs-Host Disease." *Archives of Dermatology* 144.9 (2008): 1229-231. Web. [PMID: 18794477]
9. Cohen, Philip R. "Isomorphic Sclerotic-Type Cutaneous Chronic Graft-Versus-Host Disease: Report and Review of Chronic Graft-Versus-Host Disease in a Cutaneous Immunocompromised District." *Dermatology and Therapy* 3.2 (2013): 215-22. Web. [PMID: 24318412]
10. Ruocco, Vincenzo, Eleonora Ruocco, Vincenzo Piccolo, Giampiero Brunetti, Luigi Pio Guerrera, and Ronni Wolf. "The Immunocompromised District in Dermatology: A Unifying Pathogenic View of the Regional Immune Dysregulation." *Clinics in Dermatology* 32.5 (2014): 569-76. Web. [PMID: 25160098]
11. Vassallo, C., V. Brazzelli, M. Zecca, F. Locatelli, PeAlessandrino, and G. Borroni. "Isomorphic Cutaneous Graft-versus-host Disease Reaction after Ultraviolet Exposure: Clinical, Histological and Direct Immunofluorescence Studies of Four Allografted Patients." *Journal of the European Academy of Dermatology and Venereology* 23.8 (2009): 913-18. Web. [PMID: 19586515]