

**Photo vignette**

**Dermoscopy of acral angioma serpiginosum**

**Azael Freites-Martinez<sup>1</sup>, Diego Martinez-Sanchez<sup>1</sup>, Juan Carlos Tardío<sup>2</sup>, Maria Huerta-Brogeras<sup>1</sup>, Jesús Borbujo<sup>1</sup>**

**Dermatology Online Journal 21 (2): 14**

**<sup>1</sup>Department of Dermatology, <sup>2</sup>Department of Pathology, Hospital Universitario de Fuenlabrada, Madrid**

**Correspondence:**

Azael Freites-Martinez MD  
Dermatology Department  
University Hospital of Fuenlabrada  
Camino del Molino 2. 28942.  
Madrid, Spain.  
azaelfreites@yahoo.com

---

**Abstract**

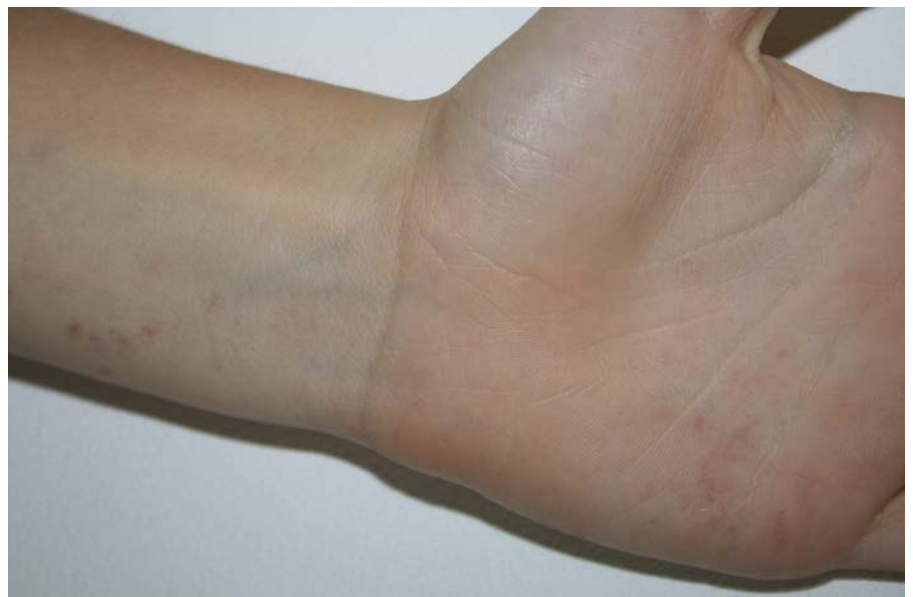Angioma serpiginosum (AS) is an unusual vascular disorder that typically affects female patients, begins in childhood, and stabilizes in adulthood. It not frequently involves acral skin. We herein present a 13 year-old girl with asymptomatic erythematous punctuate papules, noticed on the right palm for the last three years. During that time there was a proximal serpiginous progression up onto the forearm. Dermoscopy showed an erythematous parallel ridge pattern with some red globules and dots spreading in a linear arrangement; acrosyringial openings were not affected. Histopathological study showed dilated capillaries in the dermal papillae. These features are consistent with angioma serpiginosum (AS). This report shows a dermoscopic image of a palmar AS. The dermoscopic pattern described in this case could aid in the diagnosis of AS and could add value in diagnosing vascular lesions on acral skin.

**Case synopsis**

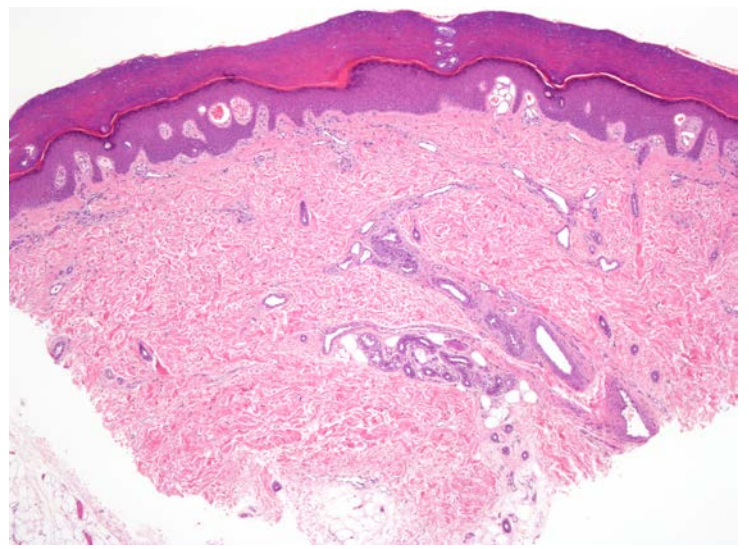
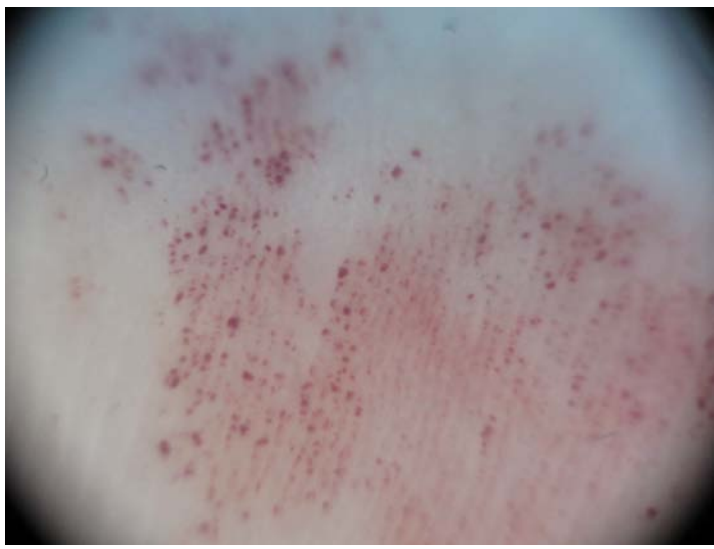A 13 year-old girl first noticed asymptomatic erythematous, punctuate, right palmar papules about 3 years prior to presentation. Over the 3 years there was proximal serpiginous progression up onto the forearm. On examination there were non-blanching erythematous punctuate papules on the palm and the inner aspect of right hand and forearm in a somewhat linear array (Figure 1).

**Dermoscopy appearance**

Dermoscopy showed an erythematous parallel ridge pattern with some red globules and dots spreading in a linear arrangement; acrosyringial openings were not affected (Figure 2).



**Figure 1.** Angioma serpiginosum. Clinical image. Erythematous punctate papules on the palm and the inner aspect of right hand and forearm.



**Figure 2.** Angioma serpiginosum. Dermoscopic image. Note an erythematous parallel ridge pattern with some red globules and dots. The acrosyringial openings are not affected. **Figure 3.** Angioma serpiginosum. Histologic image. Dilated capillaries in the dermal papillae. (Hematoxylin-eosin stain)

## Histologic diagnosis

A skin biopsy was performed, which showed dilated capillaries in the dermal papillae. This feature is consistent with angioma serpiginosum (AS) (Figure 3).

## Discussion

AS is an unusual vascular disorder that typically affects female patients that begins in childhood and stabilizes in adulthood. Partial or complete regression is infrequent. The arrangement and extension of the lesions may produce a serpiginous pattern. It rarely affects the mucocutaneous junction and acral or volar skin [1]. The histopathology is characterized by a vascular proliferation located at the papillary dermis, which is composed of dilated capillaries. In the current case, dermoscopic examination showed an erythematous parallel ridge pattern with some red globules and dots in a linear arrangement. This dermoscopic pattern might represent the glomerular proliferation of dilated capillaries observed in the papillary dermis. Furthermore, in vascular malformations two different dermoscopic patterns have been described: 1. a superficial blob pattern of red dots and globules, which corresponds to localized dilated capillaries in the superficial dermis, and 2. a deeper pattern composed of annular structures that are related to reddish ectatic vessels located horizontally in the deep vascular plexus. The characteristic findings of AS dermoscopy are small and relatively well-demarcated round to oval red dots and globules [2]. This case shows a dermoscopic image of an acral AS. The dermoscopic pattern described in this case could aid in the diagnosis of AS and add a valuable clue for the diagnosis of vascular lesions on acral skin.

## References

1. Ohnishi T, Nagayama T, Morita T, Miyazaki T, Okada H, Ohara K, Watanabe S. Angioma serpiginosum: a report of 2 cases identified using epiluminescence microscopy. *Arch Dermatol* 1999;135:1366-68. [PMID: 10566835]
2. Ilknur T, Fetil E, Akarsu S, Altiner DD, Ulukus C, Gunes A. Angioma serpiginosum: dermoscopy for diagnosis, pulsed dye laser for treatment. *J Dermatol* 2006; 33:252-55. [PMID: 16674788]