

## Photo Vignette

### Recurrent, pruritic papules on the legs

John A. Vigilante MD, Jane Scribner MD

Dermatology Online Journal 21 (1): 13

Captain James A. Lovell Federal Health Care Center, North Chicago, Illinois

### Correspondence:

John A. Vigilante, MD  
330 N Jefferson St Apt 1404  
Chicago, Illinois 60661  
Phone: 312-523-8164  
Fax: 847-688-2721  
Email: john.vigilante@gmail.com

---

## Abstract

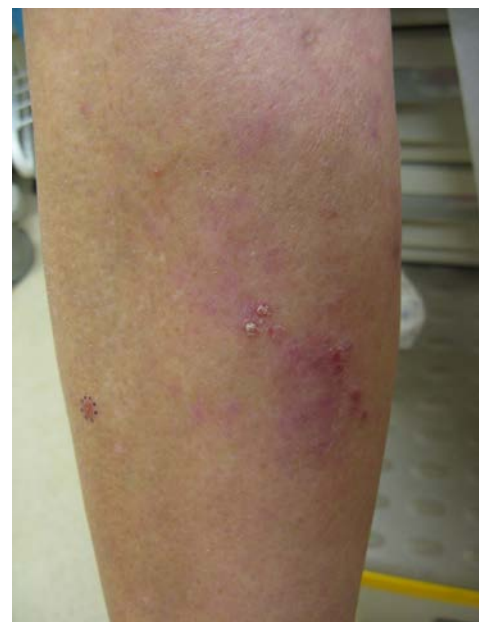We present a patient with recurrent, pruritic, erythematous papules to the legs.

**Keywords:** lymphomatoid papulosis; lymphoproliferative disorders; cutaneous lymphoma; dermatopathology; case report

## Case synopsis

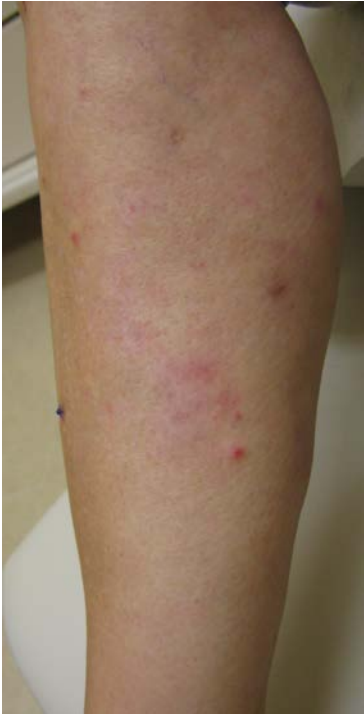A 57-year-old woman presented to the dermatology service with a three-month history of recurrent, pruritic papules on her lower extremities. She initially presented to the primary care department with a crusted papule on her right dorsal foot, which was thought to be an arthropod bite. However, she continued to develop crops of papules; some would spontaneously heal, leaving pink scars.

Physical examination revealed crops of erythematous papules on her legs, slightly blanching, some with a collarette of scale (Figure 1). There was no appreciable lymphadenopathy or hepatosplenomegaly. The patient's medical history was otherwise unremarkable and she denied any systemic symptoms. Complete blood count with peripheral smear, basic metabolic panel, erythrocyte sedimentation rate, antinuclear antibody titer, rheumatoid factor, lactate dehydrogenase, and HIV testing were normal. On examination two weeks later the patient had spontaneous resolution of previous lesions, some with residual pink macular scarring, as well as the development of new papules (Figure 2). A 4-mm punch biopsy was obtained from a recent papule on her right shin and histologic analysis was performed, revealing a normal epidermis with a dense perivascular and interstitial infiltrate occupying the superficial and mid dermis (Figure 3). The infiltrate was composed of large atypical lymphocytes mixed with smaller normal appearing lymphocytes and numerous neutrophils. The atypical lymphocytes displayed characteristic cytoplasmic staining for CD30. There was minimal staining

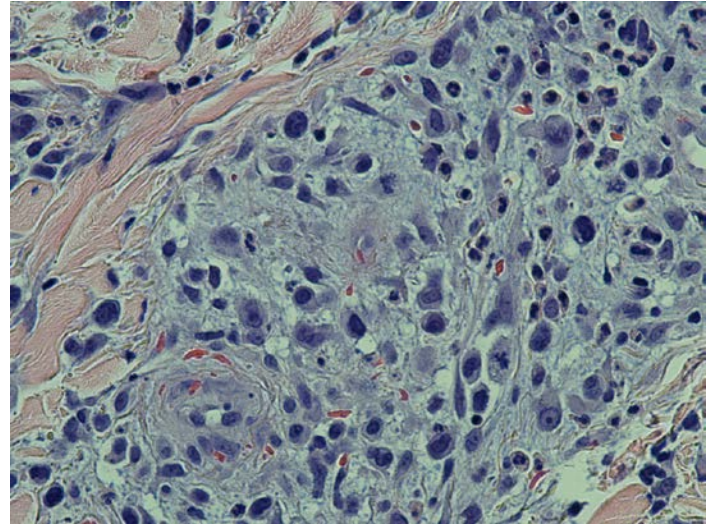
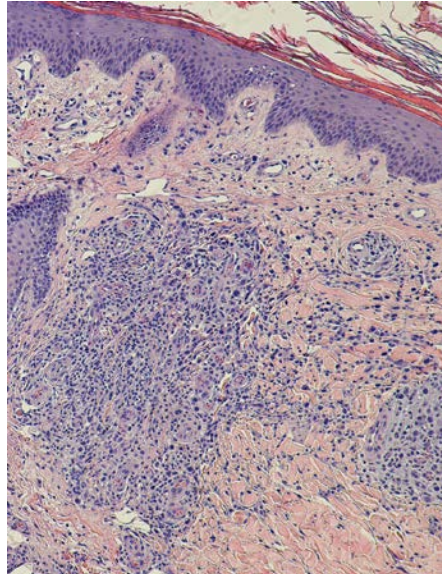


**Figure 1.** Erythematous, minimally blanching papules of the right shin with biopsy site outlined

with CD8 that was confined to the small lymphocytes. Histologic findings, in the context of the patients' clinical course, were consistent with type A lymphomatoid papulosis (LyP).



**Figure 2.** Two weeks later, right shin demonstrating new erythematous papules and interval resolution of some papules with varioliform scarring



**Figure 3.** Punch biopsy specimen with normal epidermis and a dense perivascular and interstitial infiltrate of the superficial and mid dermis composed of large, atypical lymphocytes as well as smaller lymphocytes and numerous neutrophils (A: H&E, original magnification x10, B: H&E, original magnification x40)

## Discussion

First described by Macaulay in 1968 [1], LyP is an uncommon disorder characterized by recurrent, self-healing papules and nodules composed of atypical lymphocytes. It is classified as a primary cutaneous CD30<sup>+</sup> lymphoproliferative disorder, a group that represents a spectrum of

diseases including LyP, cutaneous anaplastic large cell lymphoma, and borderline cases [2,3]. Although considered a benign entity, up to 40% of patients with LyP may develop cutaneous or nodal lymphoma occurring prior to, concurrently with, or after the appearance of LyP [4]. The lymphomas described have been most commonly mycosis fungoides or Hodgkin lymphoma [5]. Some have termed LyP a “pseudolymphoma” [6] and long-term monitoring of these patients is required. LyP has an excellent prognosis; 5- and 10-year survival rates of 92% have been reported [7].

Lymphomatoid papulosis generally presents in adults with mean age of 44, but can occur at any age, including childhood [3]. Crops of papules and nodules form, with lesions that are generally smaller than 2 cm in diameter. Some become necrotic over days to weeks, then spontaneously resolve, leaving varioliform, hyperpigmented, or hypopigmented scars. Lesions are usually diffuse, but may be localized to one anatomic region [8], and generally number between 10 to 20 at any given time, although cases of hundreds of papules have been reported [9]. The eruption may be pruritic, but is often asymptomatic. Systemic symptoms are absent in LyP and their presence should raise suspicion for associated malignancy. The duration of disease is highly variable. Characteristic histologic findings generally confirm the diagnosis, although it can be difficult to discern between LyP and other lymphoproliferative disorders also containing CD30<sup>+</sup> cells.

Numerous agents have been used with varying levels of success, including potent topical corticosteroids, topical bexarotene, oral antibiotics, psoralen-UVA, and both broadband and narrowband UVB. The most efficacious has been low-dose methotrexate, with 87% of patients achieving significant clinical improvement [10]. As there is no evidence that treatment alters the risk of progression to secondary lymphoma [3], therapy is generally reserved for symptomatic individuals in which benefits outweigh the potential complications. Unfortunately, recurrence is common after cessation of treatment. Further, owing to the association between LyP and malignancy, regular follow-up is needed to monitor for changes in cutaneous symptoms or new systemic complaints; this may require an interdisciplinary approach.

## References

1. Macaulay WL. Lymphomatoid papulosis: a continuing self-healing eruption, clinically benign-histologically malignant. *Arch Dermatol.* 1968 Jan;97(1):23-30. [PMID: 5634442]

2. Willemze R, Jaffe ES, Burg G, et al. WHO-EORTC classification for cutaneous lymphomas. *Blood*. 2005 May 15;105(10):3768-85. [PMID: 15692063]
3. Bekkenk M, Geelen FAMJ, van Voorst Vader PC, et al. Primary and secondary cutaneous CD30-positive lymphoproliferative disorders: long term follow-up data of 219 patients and guidelines for diagnosis and treatment. A report from the Dutch Cutaneous Lymphoma Group. *Blood*. 2000 Jun 15;95(12):3653-61. [PMID: 10845893]
4. Zackheim HS, Jones C, LeBoit PE, et al. Lymphomatoid papulosis associated with mycosis fungoides: a study of 21 patients including analyses for clonality. *J Am Acad Dermatol*. 2003 Oct;49(4):620-3. [PMID: 14512906]
5. Thomsen K, Wantzin GL. Lymphomatoid papulosis. A follow-up study of 30 patients. *J Am Acad Dermatol*. 1987 Oct;17(4):632-6. [PMID 2889756]
6. Ploysangam T, Breneman DL, Mutasim DF. Cutaneous pseudolymphomas. *J Am Acad Dermatol*. 1998 Jun;38(6 Pt 1):877-95. [PMID 9631994]
7. Liu HL, Hoppe RT, Kohler S, et al. CD30+ cutaneous lymphoproliferative disorders: the Stanford experience in lymphomatoid papulosis and primary cutaneous anaplastic large cell lymphoma. *J Am Acad Dermatol*. 2003 Dec;49(6):1049-58. [PMID 14639383]
8. Hsu YJ, Su LH, Hsu YL, et al. Localized lymphomatoid papulosis. *J Am Acad Dermatol*. 2010 Feb;62(2):353-6. [PMID 20115961]
9. Zirbel GM, Gellis SE, Kadin ME, Esterly NB. Lymphomatoid papulosis in children. *J Am Acad Dermatol*. 1995 Nov;33(5 Pt 1):741-8. [PMID 7593772]
10. Vonderheid EC, Sajjadian A, Kadin ME. Methotrexate is effective therapy for lymphomatoid papulosis and other primary cutaneous CD30-positive lymphoproliferative disorders. *J Am Acad Dermatol*. 1996 Mar;34(3):470-81. [PMID 8609262]