

## Case Presentation

### Vegetative pyoderma gangrenosum

Randie H. Kim MD PhD, Jesse Lewin MD, Christopher S. Hale MD, Shane A. Meehan MD, Jennifer Stein MD, and Sarika Ramachandran MD

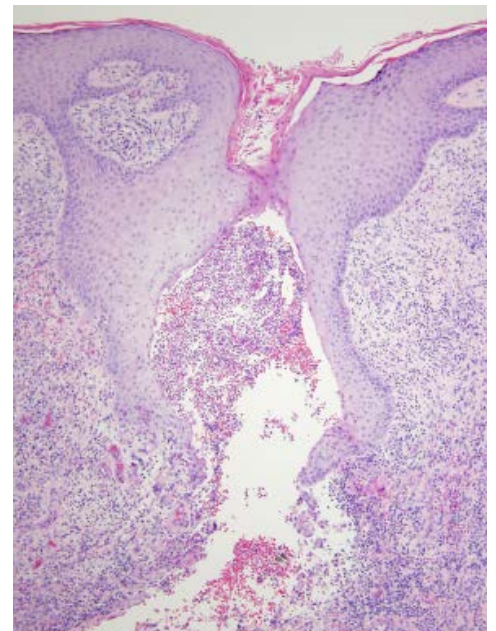
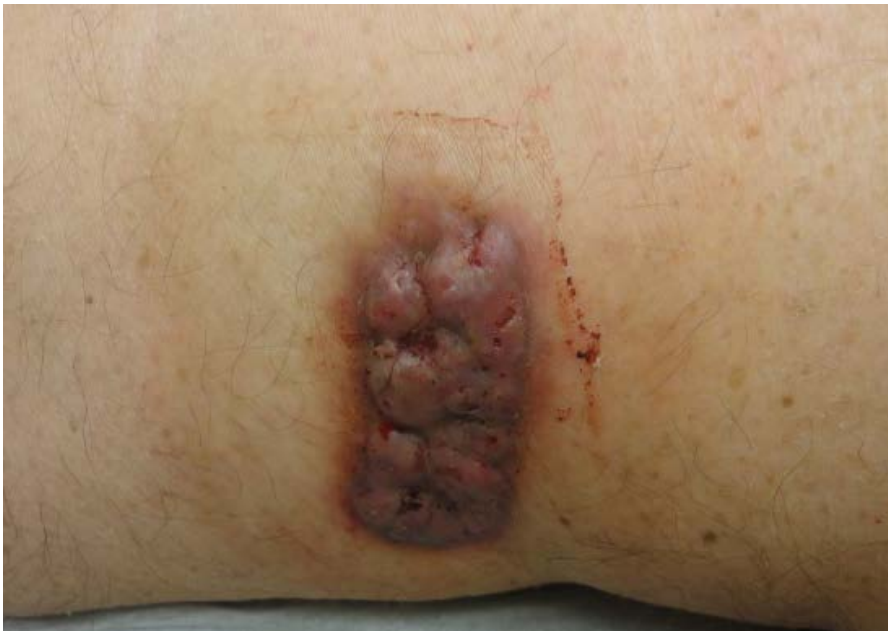Dermatology Online Journal 20 (12): 11

New York University School of Medicine

Special Guest Editor: Nicholas A. Soter, MD

## Abstract

Vegetative pyoderma gangrenosum is a rare, superficial variant of pyoderma gangrenosum that is more commonly found on the trunk as single or multiple, non-painful lesions. There is typically no associated underlying systemic disease. Compared to classic pyoderma gangrenosum, vegetative lesions are more likely to heal without the use of systemic glucocorticoids, although up to 39% of patients required a short course of prednisone in a review of 46 cases. Treatments for vegetative pyoderma gangrenosum include topical and intralesional glucocorticoids, minocycline or doxycycline, dapsone, colchicine, and, rarely, alternative steroid-sparing immunosuppressants. We present a case of multiple vegetative pyoderma gangrenosum lesions arising in prior surgical sites in a patient found to have IgA monoclonal gammopathy and abnormal urinary protein electrophoresis.



## Case synopsis

**History:** A 73-year-old man presented to the Skin and Cancer Unit for evaluation of a single, non-healing lesion at the excision site of a dime-sized epithelioma cuniculatum. The surgery had been performed at an outside hospital six months prior. He did not recall any trauma to the site before the appearance of the initial lesion. The surgical scar slowly increased in size and was associated with persistent bleeding. A biopsy performed by an outside dermatologist showed post-suppurative granulomatous

dermatitis with pseudocarcinomatous epithelial hyperplasia that was suspicious for infection. However, acid-fast bacilli, Fite, Periodic Acid-Schiff, and Gomori Methenamine-Silver stains were negative. Fungal and acid-fast bacilli cultures were also negative. Past medical history includes hypertension, cardiac arrhythmia status post ablation, prostate cancer status post prostatectomy, benign pituitary tumor status post resection, scarlet fever, gout, and basal-cell carcinoma. There were no known drug allergies. His medications included aspirin, allopurinol, lisinopril, and amlodipine. Punch biopsies were obtained for hematoxylin and eosin staining. Tissue was obtained for bacterial, fungal, and acid-fast bacilli cultures. In addition to local wound care with vaseline impregnated gauze, the patient received monthly intralesional triamcinolone injections, topical glucocorticoids, and doxycycline.

**Physical examination:** On the left posterior thigh, there was a single, 5.5 x 2-cm, hyperpigmented, multi-lobular, smooth plaque with multiple, punctate, bleeding foci. On the left upper back, there were grouped, friable, verrucous, papules at the site of a surgical scar.

**Laboratory data:** A complete blood count, basic metabolic panel, liver function tests, and lactate dehydrogenase were normal. Antibodies to antinuclear antibody, rheumatoid factor, and anti-neutrophil cytoplasmic antibody were absent. Erythrocyte sedimentation rate was elevated to 12 mm/hr (reference range 0 to 10mm/hr). C-reactive protein was 6 mg/L (reference range 0 to 9 mg/L). Human immunodeficiency virus was negative. Hepatitis B and C serologies were non-reactive. Serum beta globulin was elevated to 1.39 g/dL (reference range 0.48 to 1.10 g/dL); serum IgA was elevated to 794 mg/dL (reference range 68 to 378 mg/dL); serum IgG was 900 mg/dL (reference range 768 to 1632 mg/dL); serum IgM was 96 mg/dL (reference range 60 to 263 mg/dL). Urinary free kappa light chains were elevated to 4.13 mg/dL (reference range 0.14 to 2.42 mg/dL). Urinary free lambda light chains were 0.10 mg/dL (reference range 0.02 to 0.67 mg/dL).

Computed tomography of the abdomen and pelvis showed no lymphadenopathy and stable scattered pulmonary nodules. Tissue culture from the lesion was positive for *Corynebacterium amycolatum* and rare *Enterobacter aerogenes*. Fungal and AFB cultures were negative.

**Histopathology:** There is irregular epidermal hyperplasia and a nodular, mixed-cell infiltrate of neutrophils, plasma cells, eosinophils, and histiocytes, many of which are multinucleated. Periodic acid-Schiff with diastase, acid-fast bacilli, and Gram stains are negative for microorganisms. There is no polarizable material with examination under polarized light.

## Discussion

**Diagnosis:** Vegetative pyoderma gangrenosum

**Comment:** Pyoderma gangrenosum (PG) is an ulcerating neutrophilic dermatosis that typically begins as a painful papule, pustule, or nodule that enlarges and ulcerates with an undermined edge and peripheral erythema. Lesions often develop at sites of trauma and particularly affect the lower extremities. PG is known to be associated with a number of systemic disorders, which include inflammatory bowel disease, arthritis, hematologic malignant conditions, and monoclonal gammopathy [1].

The pathogenesis of PG remains unclear. The presence of dense, neutrophilic infiltrates on histopathologic examination has pointed to neutrophilic dysregulation as a contributor to the development of lesions [2]. Furthermore, the association with other inflammatory systemic diseases [3] and elevations in serum inflammatory markers [4] suggest that PG is a manifestation of systemic autoinflammatory disease. As such, treatments for PG often require multiple modalities to target wound healing, inflammation, and pain. Systemic glucocorticoids or cyclosporine are used as first-line agents for large and rapidly progressing lesions. Steroid-sparing immunosuppressant drugs, such as mycophenolate mofetil, azathiopurine, methotrexate, and biologics have been used as alternative agents [1]. Inhibition of neutrophil chemotaxis with colchicine [5], dapsone [6], and the tetracycline class of antibiotics [7] may be effective.

Five subtypes of PG have been described: classic (ulcerative), bullous, pustular, peristomal, and vegetative. Vegetative PG is a rare, superficial form of PG first described in 1988. Reportedly, this form healed without the use of systemic glucocorticoid therapy [8]. Most commonly found on the trunk, vegetative PG begins as a single papule, nodule, or plaque that slowly evolves into a granulomatous or vegetative lesion or ulcer. Edges may be hemorrhagic, crusted, or verrucous. Sinus tracts may form and, over time, may lead to cribiform scars. Lesions may be single or multiple and are usually not so painful as classic PG lesions.

Histopathologic findings show a superficial or deep abscess that is surrounded by histiocytes or giant cells. Reactive epidermal changes include acanthosis and pseudoepitheliomatous hyperplasia. Granulation tissue, plasmacytosis, eosinophils, or hemorrhage also may be prominent features [8]. The major histopathologic conditions in the differential diagnosis for vegetative PG are blastomycosis-like pyoderma, pyoderma vegetans, and other deep fungal or atypical mycobacterial infections. Blastomycosis-like

pyoderma may be differentiated from vegetative PG by cultures that, in the former, are positive for streptococci, staphylococci, or other pathogenic Gram-negative bacteria. Pyoderma vegetans is more commonly observed in patients with underlying immunosuppression and may be on the same clinical spectrum as vegetative PG. Diagnosis of vegetative PG is based on history, clinical presentation, histopathologic features, and, importantly, negative bacterial and fungal cultures and stains [9].

To date, 46 cases of vegetative PG have been reported in the literature. The mean age of patients in reported cases was 50.2 years (range: 8 to 82 years). There was a slight male predominance of 1.2:1. Evaluation of the site preference showed the following: 52% of lesions were located on the trunk, 31% on the extremities, 9% on the face, 5% in the groin, and 2% on the scalp [9].

Unlike classic PG, vegetative PG typically is not associated with underlying systemic conditions. In 46 reported cases, only 18% of patients had other comorbid conditions [9], which included Behcet's disease [10], myelodysplastic syndrome [11], chronic renal failure [12], diabetes mellitus, uveitis, scleritis, rheumatoid arthritis, pulmonary sarcoidosis, vitiligo, polymyalgia, chronic lymphocytic leukemia, IgA paraproteinemia, splenectomy, lichen planus, cystic acne, polycythemia vera, and uterine myomata [9].

Treatments used for vegetative PG have included glucocorticoids (topical, intralesional, and oral), cyclosporine, dapsone, sulfonamides, sulfapyridine, tetracyclines, clofazamine, thalidomide, tacrolimus (topical and oral), topical disodium chromoglycate, and hyperbaric oxygen. A review of 46 reported cases showed that 39% of patients required prednisone for a short duration, 11% received intralesional triamcinolone, 31% were given minocycline, and 15% were given dapsone. Lesions resolved between three weeks and 12 years of treatment initiation. In 35% of patients, lesions healed within six months [9].

A review of the prior excision and biopsies of our patient consistently showed pseudoepitheliomatous hyperplasia and suppurative and granulomatous infiltrate with negative stains for bacteria, acid-fast bacilli, and fungi, which lead to our diagnosis of vegetative pyoderma gangrenosum. Although *Corynebacterium* and rare *Enterobacter* were identified by culture, they likely represent colonization and bacterial drift to the posterior thigh rather than an indication of pathogenicity. Although vegetative PG typically is not associated with underlying systemic disease, our patient was found to have an IgA monoclonal gammopathy in addition to the presence of free urinary kappa light chains. He has subsequently been referred for further hematologic evaluation. A short course of oral glucocorticoids may be indicated if no response is seen to conservative therapy.

## References

1. Ahronowitz I, et al. Etiology and management of pyoderma gangrenosum: a comprehensive review. *Am J Clin Dermatol* 2012;13:191 [PMID: 22356259]
2. Adachi Y, et al. Aberrant neutrophil trafficking and metabolic oscillations in severe pyoderma gangrenosum. *J Invest Dermatol* 1998;111:259 [PMID: 9699727]
3. Ruocco E, et al. Pyoderma gangrenosum: an updated review. *J Eur Acad Dermatol Venereol* 2009;23:1008 [PMID: 19470075]
4. Weenig RH, et al. Skin ulcers misdiagnosed as pyoderma gangrenosum. *N Engl J Med* 2002;347:1412 [PMID: 12409543]
5. Kontochristopoulos GJ, et al. Treatment of pyoderma gangrenosum with low-dose colchicine. *Dermatology* 2004;209:233 [PMID: 15459540]
6. Brown RE, et al. Bilateral pyoderma gangrenosum of the hand: treatment with dapsone. *J Hand Surg Br* 1993;18:119 [PMID: 8436847]
7. Lynch WS, Bergfeld WF. Pyoderma gangrenosum responsive to minocycline hydrochloride. *Cutis* 1978;21:535 [PMID: 639572]
8. Wilson-Jones E, Winkelmann RK. Superficial granulomatous pyoderma: a localized vegetative form of pyoderma gangrenosum. *J Am Acad Dermatol* 1988;18:511 [PMID: 3351014]
9. Langan SM, Powell FC. Vegetative pyoderma gangrenosum: a report of two new cases and a review of the literature. *Int J Dermatol* 2005;44:623 [PMID: 16101860]
10. Kim JW, et al. Vegetative pyoderma gangrenosum in Behcet's disease. *Acta Derm Venereol* 2007;87:365 [PMID: 17598044]
11. Murata J, et al. Multiple nodules on the face and in the nasal cavity are the symptoms of vegetative pyoderma gangrenosum complicated with myelodysplastic syndrome. *Clin Exp Dermatol* 2006;31:74 [PMID: 16309489]
12. Goto M, et al. Vegetative pyoderma gangrenosum in chronic renal failure. *Br J Dermatol* 2002;146:141 [PMID: 11841382]