

Case Presentation

Localized acne induced by radiation therapy

Hubiche T¹, Sibaud V²

Dermatology Online Journal 20 (2): 12

Dermatology departments. ¹Intercommunity Hospital - Frejus-Saint Raphael, France.

²Claudius REGAUD Institute, Comprehensive Cancer Center – Toulouse, France

Correspondence:

Vincent Sibaud
Claudius REGAUD Institute, Comprehensive Cancer Center
20-24 rue du Pont Saint-Pierre - 31052 Toulouse, France.
Phone number: +33 5 61 42 46 17
Fax: +33 5 61 42 46 21
sibaud.vincent@claudiusregaud.fr

Abstract

The appearance of localized acne or comedo reaction during or shortly after radiotherapy is an unusual adverse event, but one that is probably underestimated. It can manifest as an inflammatory (papules, pustules, nodules), comedonal (open and closed comedones, Favre-Racouchot-like syndrome), or mixed presentation. We report two new cases of radiation-induced acne with different clinical aspects and discuss the main known features of this adverse event.

Key words: ionizing radiation, comedones, acne, pustules, comedo reaction

Introduction

Radiation therapy is a mainstay of cancer treatment. However, despite the substantial technical improvement that has been achieved in the type of ionizing radiation used and the related monitoring, radiation skin injury is still a concerning problem. Patients may be affected primarily by acute radiation dermatitis of varying degree, but sometimes also by delayed complications that occur at a later stage after the radiotherapy [1,2]. The occurrence of radiation-induced acne or comedo reaction, during or shortly after radiotherapy, has been far less commonly reported. We report here two different clinical presentations of localized acne induced by radiation therapy.

Case synopsis

Case #1: A 49-year-old male patient presented with the recent onset of inflammatory papules on the neck, centered located at the sites of hair follicles. These had appeared 10 days after the end of treatment for a squamous cell carcinoma of the tonsil involving adjuvant intensity-modulated radiotherapy (66 grays, 2.2 grays per session, 5 days a week for 6 weeks) and chemotherapy with cisplatin and 5 fluorouracil. The lesions were strictly confined to the radiation field. Dermatological examination also revealed a few closed comedones and rare pustules (Figure 1). All the lesions regressed rapidly following topical treatment with retinoids over 6 weeks

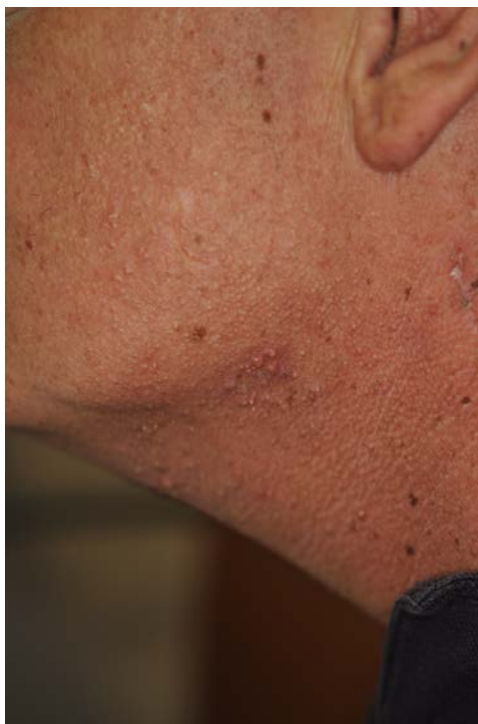

Figure 1. Radiation-induced acne with follicular papules with few pustules and closed comedones

Case #2: A 58-year-old man was undergoing treatment for a locally advanced mucosal melanoma of the nasal cavity. Treatment initially combined cisplatin chemotherapy with radiotherapy confined to the tumor bed (66 grays in total, 2.2 grays per session, 5 days a week for 6 weeks). After 3 weeks of radiotherapy, a number of open comedones, microcysts, and closed comedones appeared in the radiotherapy field (Figure 2). There were no associated papular or pustular inflammatory acne lesions. Histological examination revealed open and closed comedones containing keratin plugs (Figure 3). All the comedones lesions regressed within a few weeks after physical extraction.

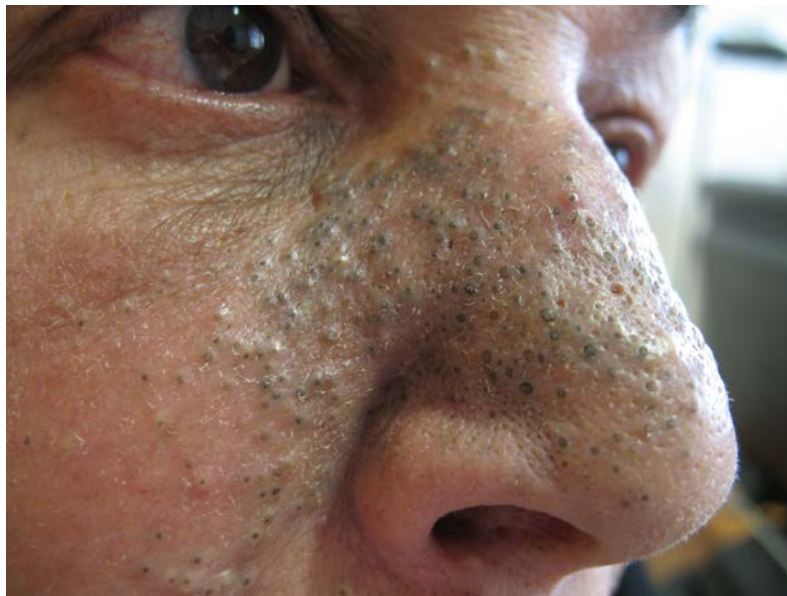

Figure 2. Comedo reaction restricted to the radiation field

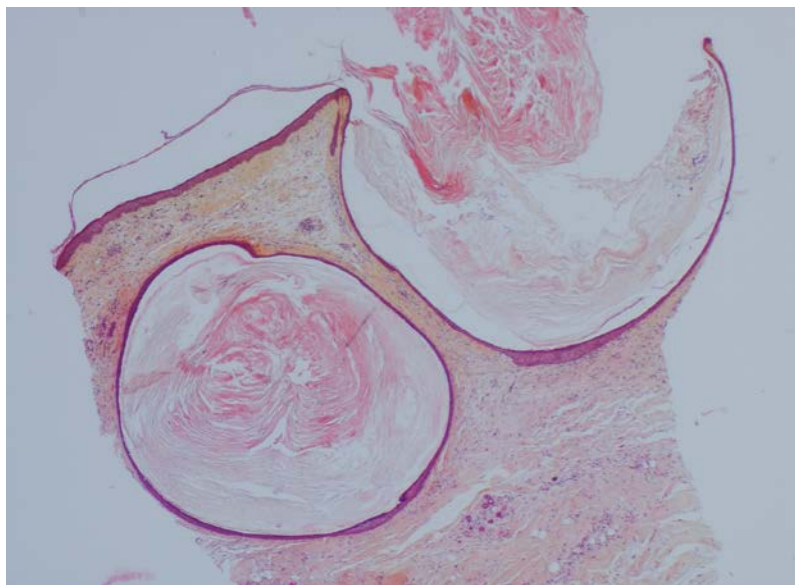


Figure 3. Biopsy analysis showed comedones with follicular plugging and dense keratotic material.

Discussion

Radiation-induced acne or comedo skin reaction has only very rarely been reported in the literature, but its incidence is undoubtedly underestimated. It may exhibit various acneiform clinical presentations, primarily a comedonal picture (closed comedones, open comedones) [3]. However, sometimes inflammatory lesions (papules, pustules, nodules) or a mixture of inflammatory and comedonal lesions are exhibited [4-7]. The most characteristic presentation, however, is that of Favre-Racouchot syndrome [3,8,9] on the face, combining comedones and deep furrows. It can occur in a variety of cancers and in different areas, but most frequently on the scalp, neck, and face [2,6,7,9], as in our two patients. The lesions always remain strictly confined to the radiation fields. Although the lesions usually develop 2 weeks to 6 months after the end of radiotherapy [3,7], they can also appear during radiotherapy [3]. Radiation-induced acne has been described with several types of radiation, including deep cobalt therapy, megavoltage therapy, and superficial X-ray therapy [6,7]. The majority of cases, however, have been reported with the latter [5] and with cobalt therapy [3, 7]. The pathophysiology of radiation-induced acne is currently unknown. It has been postulated that radiation therapy might affect the quantity and composition of the sebum produced [3,7]. Similarly, ionizing radiation might induce chronic follicular inflammation [3,8] with secondary follicular hyperkeratosis and the production of comedones. The radiation-induced local increase in TGF- β expression might also potentially be involved [2, 6]. A foreign body inflammatory reaction directed against the pilosebaceous remnants post ionizing radiation has also been suggested [3, 5, 6]. Conversely, a previous personal history of acne does not appear to be a predisposing factor [7]. Acute radiation dermatitis has not been associated with the development of acne lesions [6]. Lastly, total dose, radiation dose to the skin, fractionation timing, type of beam, treated volume, and irradiation site may affect the degree of severity of the lesions [1, 2].

The diagnosis can usually be made considering the clinical presentation and the context. In principle, EPPER (*eosinophilic, polymorphic and pruritic eruption associated with radiotherapy*) [10] and radiation-induced Grover disease [11] might be considered in the purely inflammatory forms.

Therapeutic management is based primarily on local treatments, including the use of topical retinoids, benzoyl peroxide, or physical extraction of the comedones [3, 6, 7, 9]. The patient should also be informed of the both benign and transient nature of these lesions. Lastly, better identification of this adverse event should enable the clinician to reassure the patient and to avoid invasive investigations.

References

1. Ryan JL. Ionizing radiation: the good, the bad, and the ugly. *J Invest Dermatol.* 2012 Mar;132(3 Pt 2):985-93.[PMID:22217743]
2. Hymes SR, Strom EA, Fife C. Radiation dermatitis: clinical presentation, pathophysiology, and treatment 2006. *J Am Acad Dermatol.* 2006 Jan;54(1):28-46.[PMID:16384753]
3. Demirsoy EO, Kiran R, Öztürk B, Özkara Kaçar S, Sikar Aktürk A. Comedogenic acne following radiation therapy. *Eur J Dermatol.* 2011 Nov-Dec;21(6):1017-8.[PMID:21914588]
4. Adriaans B, du Vivier A. Acne in an irradiated area. *Arch Dermatol.* 1989 Jul;125(7):1005.[PMID:2525894]
5. Song Jy, Ha SJ, Kim CW, Kim HO. A case of localized acne following radiation therapy. *Acta Derm Venereol.* 2002;82(1):69-70.[PMID:12013210]

6. Balagula Y, Hensley JR, Gerami P, Lacouture ME. Acneiform rash as a reaction to radiotherapy in a breast cancer patient. *J Support Oncol*. 2010 Nov-Dec;8(6):268-71. [PMID:21265395]
7. Martin WM, Bardsley AF. The comedo skin reaction to radiotherapy. *Br J Radiol*. 2002 May;75(893):478-481. [PMID:12036846]
8. Friedman SJ, Su WP. Favre-Racouchot syndrome associated with radiation therapy. *Cutis*. 1983 Mar;31(3):306-10. [PMID:6301762]
9. Breit S, Flaig MJ, Wolff H, Plewig G. Favre-Racouchot-like disease after radiation therapy. *J Am Acad Dermatol*. 2003 Jul;49(1):117-9. [PMID:12833021]
10. Lee DJ, Kim YCA. Pustular form of eosinophilic, polymorphic, and pruritic eruption associated with radiotherapy. *J Am Acad Dermatol*. 2011 Aug;65(2):e51-3. [PMID:21763551]
11. Held JL. Acne in an irradiated area. *Arch Dermatol*. 1990 Jan;126(1):120. [PMID:2136986]