

**Case presentation**

**Ustekinumab for treatment of cutaneous Crohn's disease**

**Rana Abdat<sup>1</sup> MD, Alina Markova<sup>1</sup> MD, Francis A. Farraye<sup>2</sup> MD, MSc, Michael K. Lichtman<sup>1</sup> MD**

**Dermatology Online Journal 22 (10): 7**

**<sup>1</sup> Department of Dermatology, Boston University School of Medicine, Boston, MA**

**<sup>2</sup> Section of Gastroenterology, Boston University School of Medicine, Boston, MA**

**Correspondence:**

Michael K. Lichtman, MD  
Boston University School of Medicine  
Department of Dermatology  
609 Albany Street  
Boston, MA, 02118  
Email: mk120@bu.edu

---

**Abstract**

Cutaneous Crohn disease (CD) affecting the vulva, perineum, and perianal skin, is a rare entity, which may accompany or precede gastrointestinal CD. Vulvar involvement, if untreated, may ultimately require extensive surgery including vulvectomy to gain control of the disease. Both gastrointestinal and cutaneous CD respond to biologics, which block TNF $\alpha$ . In addition, ustekinumab, which targets both IL-12 and IL-23 cytokines, is effective in patients with gastrointestinal CD who fail TNF blockade. However, it is unclear if ustekinumab is effective for cutaneous CD. Herein we present a patient with cutaneous CD affecting the vulva and perianal skin, which, at seven months, had a marked response to ustekinumab administered at higher doses than typically used for psoriasis.

**Keywords: Ustekinumab; Crohn disease; genital lesion**

**Introduction**

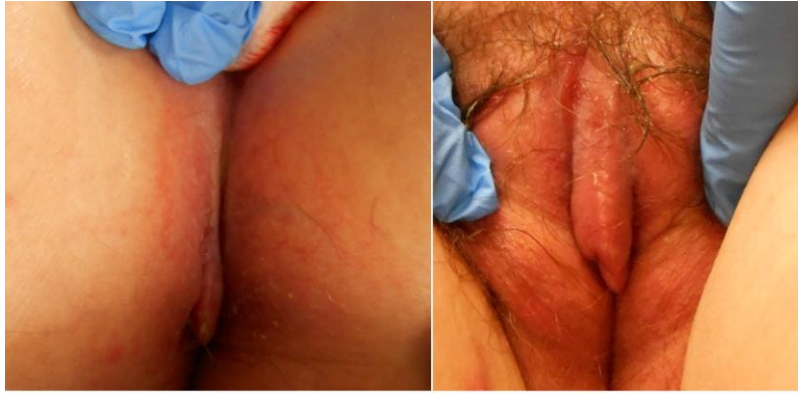Crohn disease (CD) is a chronic, granulomatous disease, typically involving the large and small bowel. Extra-intestinal CD is common, with cutaneous involvement seen in up to 44% [1] of patients. Metastatic CD (MCD) is an unusual manifestation of cutaneous disease, in which there is no contiguity between the skin lesions and the intestinal involvement. Lesions are most frequently located in flexures, genitalia, and extremities [2]. MCD may appear as either solitary or multiple plaques, nodules, or tumors, usually on arms and legs. In addition, knife-like ulcerations in the intertriginous areas may occur [2, 3]. Genital infiltration with CD and resultant clitoromegaly has also been reported [4]. Similar to psoriasis, CD is a Th1 and Th17 mediated disease. Supporting this idea, ustekinumab, a humanized IgG1k monoclonal antibody that binds to the p40 subunit of IL-12 and IL-23 receptors, has been effective for gastrointestinal CD in patients who do not respond to tumor necrosis factor (TNF) antagonists [5].

**Case synopsis**

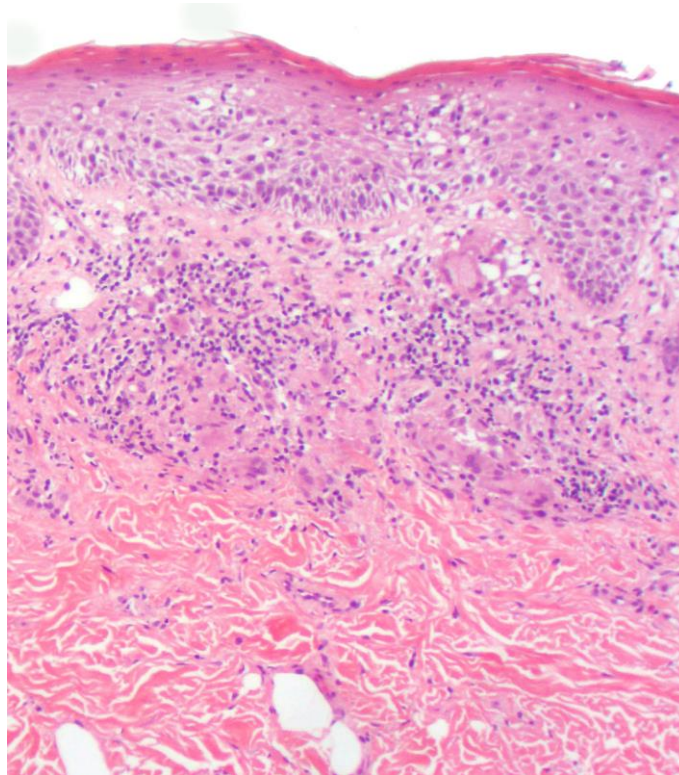
A 62 year old woman, with an 18 year history of intestinal CD, quiescent after a colectomy and administration of TNF blockade, initially presented to dermatology clinic with severe perianal and vulvar engorgement and discomfort, beginning within 6 months of her colectomy.

Over the course of three years, the patient's cutaneous disease did not respond to multiple systemic medications including multiple courses of prednisone, doxycycline for six months, 6 mercaptopurine and infliximab for one year, and two courses of adalimumab, each for six months. The patient's gluteal disease had also not responded to approximately 15 intralesional injections of triamcinolone acetonide at concentrations as high as 40mg/cc. The patient had most recently tried certolizumab pegol for the cutaneous CD for 15 months without improvement. Of note, there was no evidence for recurrent ileal Crohn disease after her proctocolectomy.

Because the patient's cutaneous disease continued to be bothersome, she re-presented to dermatology clinic. Physical examination revealed an indurated, ulcerated, and linear plaque on the perianal skin as well as clitoromegaly (Figure 1). Prior biopsy of the gluteal cleft plaque, taken at the initial presentation for cutaneous disease, showed granulomatous inflammation consistent with cutaneous CD (Figure 2).



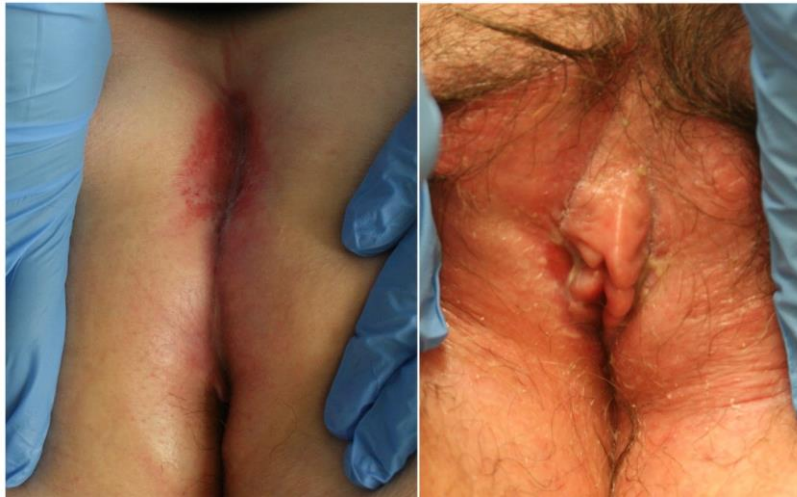**Figure 1.** Anogenital area of the patient before ustekinumab treatment. (Left panel), indurated firm plaque at the midgluteal cleft. (Right panel), Indurated erythematous labia majora with bilateral vulvar ulcers and clitoromegaly.



**Figure 2:** Biopsy showed a granulomatous and psoriasiform neutrophilic spongiotic dermatitis, with a mild superficial perivascular lymphocytic infiltrate with occasional neutrophils, plasma cells, admixed with multinucleate giant cells (focally in clusters). PAS stain was negative for fungi, and immunohistochemistry did not demonstrate *T. pallidum*.

In consultation with the patient's gastroenterologist (FF), the certolizumab pegol was discontinued and ustekinumab was started. The patient weighed 90kg at first dose and received ustekinumab 90 mg at week 0 and week 4, then 90 mg every 8 weeks. This regimen was comparable to doses used in CD clinical trials and higher than for cutaneous psoriasis.

Seven months after starting the treatment, the patient's perianal ulcerated plaques and clitoromegaly had largely resolved, leaving only a few asymptomatic erosions. The patient continues to be free of cutaneous and gastrointestinal symptoms one and a half years after beginning ustekinumab (Figure 3). She has not experienced any adverse events to date.



**Figure 3.** Anogenital area after one and a half year of ustekinumab treatment. (Left panel), Perianal plaque has resolved, leaving an asymptomatic erosion. (Right panel), Improved clitoromegaly and asymptomatic vulvar superficial erosions.

## Discussion

Metastatic CD may be classified into genital (56%) and extra genital (44%). In patients with metastatic CD, nearly two-thirds of children and half of adults exhibit genital involvement [6]. Knife-like flexural ulcerations are the most common subtype of metastatic CD.

Topical, intralesional, and systemic corticosteroids are the mainstay for treating MCD symptoms [7]. Unfortunately, reported rates of meaningful remission range from 13% to 92% [8]. Other systemic medications including metronidazole, azathioprine, mycophenolate mofetil, and cyclosporine have been described with variable efficacy in case reports [7]. With the advent of biologics, active MCD cases that fail these conventional therapies have benefited from TNF inhibitors [9]. The patient's cutaneous disease did not respond to three TNF blocking medications: infliximab, adalimumab, and certolizumab, although her intestinal disease remained in remission.

Whereas there is no clear correlation in disease activity between GI and cutaneous CD, cutaneous disease is more frequent in patients with colon involvement [9]. Ustekinumab is not FDA approved for CD, but there are several reports of using ustekinumab for intestinal CD. In particular, Sandborn *et al.* [10] performed a double blind clinical trial of patients with moderate to severe CD, revealing a positive clinical response; most of the effects arose after 4-6 weeks of treatment, especially in patients formerly treated with infliximab.

Given that ustekinumab is a promising therapy for recalcitrant gastrointestinal CD, we reasoned that the drug may improve cutaneous CD. We present a rare, challenging case of metastatic CD in a patient refractory to multiple anti-TNF medications, who has had ongoing clinical improvement seven months after beginning ustekinumab. Future clinical trials will be necessary to further elucidate the utility of anti-IL-12/23 blockade in the management of cutaneous CD.

## Conclusion

A 62-year-old woman with genital cutaneous CD and quiescent gastrointestinal disease, presented to the dermatology clinic complaining of perianal pain from induration, ulceration, and clitoromegaly. Her cutaneous symptoms had not improved with multiple immunosuppressive medications, including several TNF blocking medications. She was started on high dose ustekinumab, which resulted in significant improvement after seven months of treatment. Ustekinumab is a promising treatment option for cutaneous CD, although dosed more frequently than for psoriasis.

## References

1. Albuquerque A, Magro F, Rodrigues S, Lopes J, Lopes S, Dias JM, et al. Metastatic cutaneous Crohn's disease of the face: a case report and review of the literature. *European journal of gastroenterology & hepatology*. 2011;23(10):954-6. [PMID: 21900789]
2. Emanuel PO, Phelps RG. Metastatic Crohn's disease: a histopathologic study of 12 cases. *Journal of cutaneous pathology*. 2008;35(5):457-61. [PMID: 18261113]
3. Hackzell-Bradley M, Hedblad M-A, Stephansson EA. Metastatic Crohn's disease: report of 3 cases with special reference to histopathologic findings. *Archives of dermatology*. 1996;132(8):928-32. [PMID: 8712843]
4. Corbett SL, Walsh CM, Spitzer RF, Ngan B-Y, Kives S, Zachos M. Vulvar inflammation as the only clinical manifestation of Crohn disease in an 8-year-old girl. *Pediatrics*. 2010;125(6):e1518-e22. [PMID: 20457677]
5. Tuskey A, Behm BW. Profile of ustekinumab and its potential in patients with moderate-to-severe Crohn's disease. *Clinical and experimental gastroenterology*. 2014;7:173. [PMID: 24904220]
6. González-Guerra E, Angulo J, Vargas-Machuca I, del Carmen Fariña M, Martín L, Requena L. Cutaneous Crohn's disease causing deformity of the penis and scrotum. *Acta dermato-venereologica*. 2006;86(2):179-80. [PMID: 16648933]
7. Kurtzman DJ, Jones T, Lian F, Peng LS. Metastatic Crohn's disease: A review and approach to therapy. *Journal of the American Academy of Dermatology*. 2014;71(4):804-13. [PMID: 24888520]
8. Dave M, Loftus Jr EV. Mucosal healing in inflammatory bowel disease-a true paradigm of success. *Gastroenterol Hepatol (NY)*. 2012;8(1):29-38. [PMID: 22347830]
9. Laftah Z, Bailey C, Zaheri S, Setterfield J, Fuller LC, Lewis F. Vulval Crohn's disease: a clinical study of 22 patients. *Journal of Crohn's and Colitis*. 2015;9(4):318-25. [PMID: 25687208]
10. Sandborn WJ, Feagan BG, Fedorak RN, Scherl E, Fleisher MR, Katz S, et al. A randomized trial of Ustekinumab, a human interleukin-12/23 monoclonal antibody, in patients with moderate-to-severe Crohn's disease. *Gastroenterology*. 2008;135(4):1130-41. [PMID: 18706417]