

Photo vignette

Extensive cutaneous sarcoidosis and coexistent Crohn disease with dual response to infliximab: case report and review of the literature.

Jina Chung BS, Misha Rosenbach MD

Dermatology Online Journal 21 (3): 21

Department of Dermatology, University of Pennsylvania, Philadelphia, PA.

Correspondence:

Misha Rosenbach, MD
Department of Dermatology
Hospital of the University of Pennsylvania
3600 Spruce St, 2 Maloney
Philadelphia, PA 19104
Phone: 215-662-2737.
Fax: 215-662-7774.
Email: misha.rosenbach@uphs.upenn.edu.

Abstract

Sarcoidosis and Crohn disease (CD) are granulomatous disorders of unknown etiology that are rarely seen together in one patient. We describe a woman in her 40s with well-established diagnoses of pulmonary and cutaneous sarcoidosis and CD involving the terminal ileum, whose skin and gastrointestinal symptoms improved dramatically with infliximab treatment (5mg/kg on weeks 0, 2, 6, then every 8 weeks). The concurrence of sarcoidosis and CD has only been reported in a handful of cases and a review of the literature reveals that the two diseases share many clinical and immunological features, suggesting the presence of an underlying connection. Further studies of patients with overlap syndromes may provide deeper insight into the clinical spectrum, and possibly the pathogenesis, of idiopathic granulomatous diseases.

Keywords: Sarcoidosis; Crohn disease; Idiopathic granulomatous disorders

Abbreviation / Acronym List:

CD: Crohn disease
HLA: Human leukocyte antigen
IBD: Inflammatory bowel disease
TNF: Tumor necrosis factor

Introduction

Sarcoidosis and CD belong to a group of granulomatous disorders that can affect multiple organ systems and both are characterized by histologic appearances of noncaseating granulomas. One of the differences between sarcoidosis and CD lies in the type of organs that are involved; CD primarily affects the gastrointestinal tract, although it can also affect the skin, eyes, joints, and rarely the lungs. Sarcoidosis primarily affects the lungs, but can affect the skin, eyes, joints, and rarely the gastrointestinal

tract. To date, only a handful of cases of concomitant sarcoidosis and CD have been reported, most of which were treated with oral corticosteroid therapy [1, 2]. We report a patient with sarcoidosis and CD; both conditions resolved simultaneously with infliximab therapy. We review the current literature on the two diseases.

Case synopsis

A woman in her 40s with a history of sarcoidosis and CD presented in May 2010 for cutaneous sarcoidosis management. She was diagnosed with sarcoidosis in 1998 when she presented with a persistent dry cough. A nasal polyp removed in 2000 showed granulomatous inflammation and she subsequently developed cutaneous sarcoidosis on her face. Her CD was diagnosed in 1994; she underwent terminal ileal resection for a fistula in 1995 and the condition was moderately controlled on mesalamine with 2-3 flares a year. The rest of her past medical history was significant for hypertension and hypothyroidism and she had no family history of autoimmune disease.

Physical examination showed numerous hyperpigmented, infiltrated-appearing, dully erythematous papules consistent with sarcoidosis around her eyes, oral commissures, lateral face, cheeks, chin, and left elbow (Figure 1A).

Quantiferon-TB Gold test was negative, and her chest X-ray was remarkable for bilateral hilar and mediastinal adenopathy. Histology of the lesion on her left elbow showed numerous epithelioid granulomas in the dermis, consistent with sarcoidosis (Figure 2). Special stains for microorganisms were negative. The patient underwent trials of chloroquine, pentoxifylline, doxycycline, topical corticosteroids, and topical tacrolimus with little benefit; minocycline provided some relief but was stopped because of side effects. She also began to suffer from significant diarrhea occurring around 5 times a day owing to her CD. She started treatment with infliximab in December 2012 (5mg/kg on weeks 0, 2, 6, then every 8 weeks) for her sarcoidosis, upon which both her skin and gastrointestinal symptoms improved dramatically (Figure 1B).

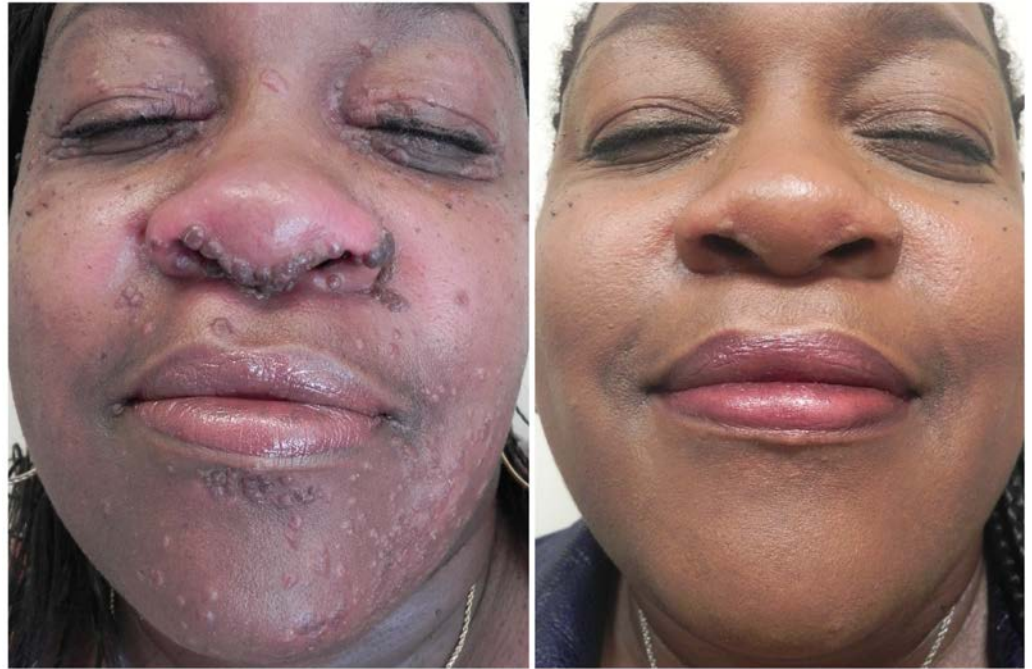

Figure 1. Clinical improvement with infliximab therapy. A, Before treatment, the patient had numerous hyperpigmented, dully erythematous papules on her face and left elbow (not shown). B, 12 months into treatment.

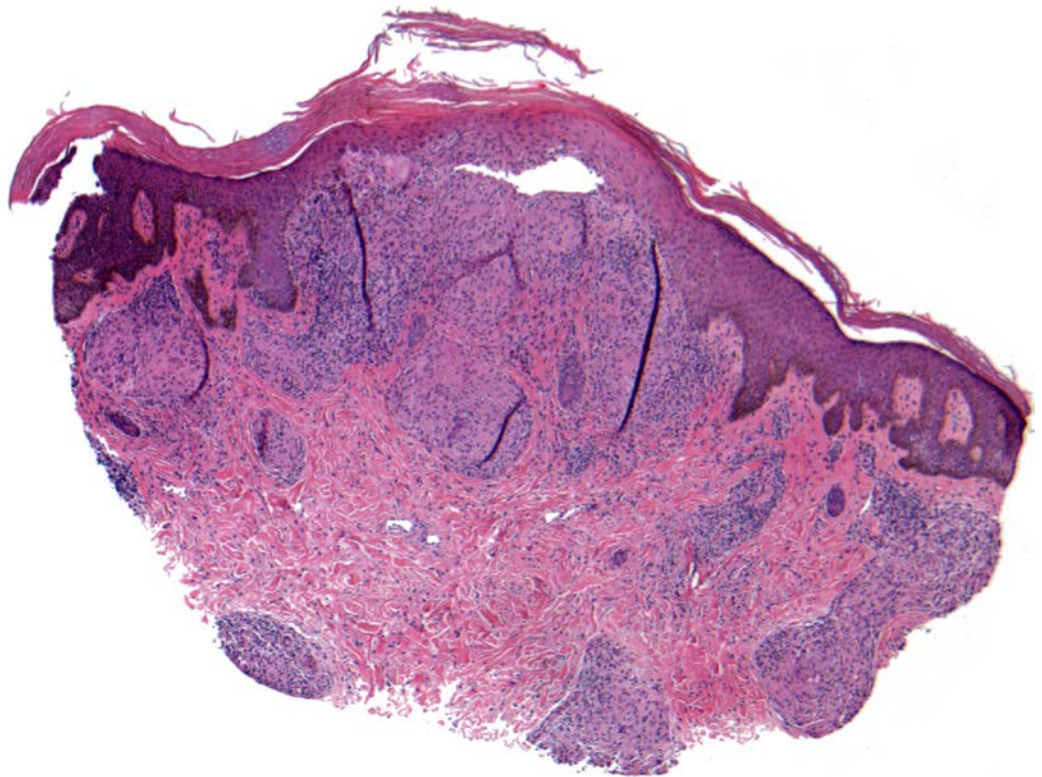


Figure 2. Histopathologic specimen demonstrating non-caseating epithelioid granulomas with minimal lymphocytic inflammation throughout the dermis (Hematoxylin and Eosin, 40x).

Discussion

The concurrence of sarcoidosis and CD has been reported in about 7 cases, with 3 more potential cases in which the details were insufficient to warrant a definitive diagnosis of sarcoidosis or CD [1, 2]. These associations appear to be somewhat rarer than that of sarcoidosis and ulcerative colitis, which has been documented in about 20 cases overall [3]. Although sarcoidosis and CD occurring together is rare enough to be merely coincidental, there are many areas where the two diseases overlap in terms of etiology, pathophysiology, and clinical symptoms.

In both conditions, an altered immune response involving type 1 and type 17 helper T lymphocytes (Th1/Th17) leads to the release of inflammatory cytokines such as interleukin(IL)-2, interferon- γ , tumor necrosis factor (TNF), and IL-17, resulting in granuloma formation [4]. The etiologies of sarcoidosis and CD are largely unknown and are most likely multifactorial, involving a combination of exogenous causes and inherited genetic susceptibility. *Mycobacterium* has been suggested as a potential common infectious trigger, because in both diseases patients were found to have detectable mycobacterial DNA and anti-mycobacterial antibodies in tissue and serum samples, respectively [5, 6]. Observational studies of sarcoidosis and CD occurring within the same family also suggest the presence of a shared genetic susceptibility; in one family, all affected members with sarcoidosis or CD had the HLA haplotype alleles B8 and DR3, which were missing in unaffected members [7]. Additionally, a genome-wide association analysis has identified a potential common susceptibility locus for both diseases at 10p12.2 [8].

Granulomas in sarcoidosis and CD are nonspecific lesions and are not by themselves diagnostic. Therefore, other granulomatous conditions such as mycobacterial and fungal infections must be ruled out before a definitive diagnosis can be reached. A test that was briefly used to aid in the diagnosis of sarcoidosis is known as the Kveim-Siltzbach test, which involves intradermal injections of homogenized sarcoidal tissue to induce cutaneous granulomas in patients with probable sarcoidosis. The test has been shown to produce a positive reaction in about 50% of patients with CD, and animal transmission studies also demonstrated that homogenates from human sarcoidal and CD tissue produce similar granulomas when injected into mice [9]. Notably, mice that were given homogenates originating from sarcoidosis had granulomas that were present in many organs including the lymph nodes, lung, liver, spleen and muscle, whereas mice that were injected with homogenates originating from CD had a pattern of visceral granulomas confined to the bowel or mesenteric lymph nodes [9].

Although sarcoidosis and CD have distinct primary organs of involvement, sarcoidosis can affect the gastrointestinal (GI) tract, and CD can affect the lungs. Sarcoidosis of the GI tract is believed to be quite rare, although about 5.9% of sarcoidosis patients were found to have GI involvement at autopsy [10]. Pulmonary involvement in CD is not uncommon; pulmonary function tests (PFTs) in patients with inflammatory bowel disease (IBD) revealed that 39% and 45% of patients with CD and ulcerative colitis had abnormal (<80% of predicted) PFTs, respectively. Average lung function was significantly decreased in patients with IBD in comparison to the control group [11]. A sarcoid-like lymphocytic alveolitis with increased CD4/CD8 ratios (>6) in bronchoalveolar lavage fluid, which is highly specific for sarcoidosis, has also been reported in patients with CD [12].

In terms of management, patients with CD and sarcoidosis can pose a unique therapeutic challenge. Anti-TNF therapy, such as infliximab, may be a reasonable option in these patients, since efficacy has been documented in both conditions [13]. Interestingly, there are case reports of patients with CD who developed pulmonary and cutaneous sarcoidosis during therapy with infliximab and adalimumab [14, 15]. Whether these cases represent new occurrences of sarcoidosis owing to anti-TNF therapy or acute worsening of occult sarcoidosis is unclear, but clinicians should keep in mind the rare possibility of a paradoxical response to treatment.

In conclusion, sarcoidosis and CD are granulomatous disorders that are relatively poorly understood and they are rarely diagnosed together in the same patient. Review of the literature suggests that they share many common characteristics and it is conceivable that one underlying mechanism may be responsible for both conditions. Further research is warranted to expand our knowledge regarding the relationship between sarcoidosis and CD. A deeper investigation of cases in which the two diseases appear to intersect, using genetic and serum studies if possible, may help improve our current understanding of these idiopathic granulomatous diseases.

References

1. Fries W, Grassi SA, Leone L, Giacomini D, Galeazzi F, Naccarato R, Martin A. Association between inflammatory bowel disease and sarcoidosis. Report of two cases and review of the literature. *Scand J Gastroenterol*. 1995 Dec;30(12):1221-3. [PMID: 9053978]
2. Johard U, Berlin M, Eklund A. Sarcoidosis and regional enteritis in two patients. *Sarcoidosis Vasc Diffuse Lung Dis*. 1996 Mar;13(1):50-3. [PMID: 8865410]
3. Jarrot PA(1), Dury S, Rakotomalala A, Vella-Boucaud J, Patey M, Deslee G, Lebagry F. Association of sarcoidosis and ulcerative colitis: a review of 20 cases. *Sarcoidosis Vasc Diffuse Lung Dis*. 2013 Nov 25;30(3):212-6. [PMID: 24284294]
4. Facco M, Cabrelle A, Teramo A, Olivieri V, Gnoato M, Teolato S, Ave E, Gattazzo C, Fadini GP, Calabrese F, Semenzato G, Agostini C. Sarcoidosis is a Th1/Th17 multisystem disorder. *Thorax*. 2011 Feb;66(2):144-50. [PMID: 21139119]

5. Brownell I, Ramírez-Valle F, Sanchez M, Prystowsky S. Evidence for mycobacteria in sarcoidosis. *Am J Respir Cell Mol Biol.* 2011 Nov;45(5):899-905. [PMID: 21659662]
6. Feller M, Huwiler K, Stephan R, Altpeter E, Shang A, Furrer H, Pfyffer GE, Jemmi T, Baumgartner A, Egger M. *Mycobacterium avium* subspecies paratuberculosis and Crohn's disease: a systematic review and meta-analysis. *Lancet Infect Dis.* 2007 Sep;7(9):607-13. [PMID: 17714674]
7. Grönhagen-Riska C, Fyhrquist F, Hortling L, Koskimies S. Familial occurrence of sarcoidosis and Crohn's disease. *Lancet.* 1983 Jun 4;1(8336):1287-8. [PMID: 6134089]
8. Franke A, Fischer A, Nothnagel M, Becker C, Grabe N, Till A, Lu T, Müller-Quernheim J, Wittig M, Hermann A, Balschun T, Hofmann S, Niemiec R, Schulz S, Hampe J, Nikolaus S, Nürnberg P, Krawczak M, Schürmann M, Rosenstiel P, Nebel A, Schreiber S. Genome-wide association analysis in sarcoidosis and Crohn's disease unravels a common susceptibility locus on 10p12.2. *Gastroenterology.* 2008 Oct;135(4):1207-15. [PMID: 18723019]
9. Mitchell DN, Rees RJ, Goswami KK. Transmissible agents from human sarcoid and Crohn's disease tissues. *Lancet.* 1976 Oct 9;2(7989):761-5. [PMID: 61441]
10. Branson JH, Park JH. Sarcoidosishepatic involvement: presentation of a case with fatal liver involvement; including autopsy findings and review of the evidence for sarcoid involvement of the liver as found in the literature. *Ann Intern Med.* 1954 Jan;40(1):111-45. [PMID: 13114813]
11. Herrlinger KR, Noftz MK, Dalhoff K, Ludwig D, Stange EF, Fellermann K. Alterations in pulmonary function in inflammatory bowel disease are frequent and persist during remission. *Am J Gastroenterol.* 2002 Feb;97(2):377-81. [PMID: 11866276]
12. Bewig B, Manske I, Böttcher H, Bastian A, Nitsche R, Fölsch UR. Crohn's disease mimicking sarcoidosis in bronchoalveolar lavage. *Respiration.* 1999;66(5):467-9. [PMID: 10516546]
13. Tuchinda P, Bremmer M, Gaspari AA. A case series of refractory cutaneous sarcoidosis successfully treated with infliximab. *Dermatol Ther (Heidelb).* 2012 Dec;2(1):11. [PMID: 23205333]
14. Takahashi H, Kaneta K, Honma M, Ishida-Yamamoto A, Ashida T, Kohgo Y, Ohsaki Y, Iizuka H. Sarcoidosis during infliximab therapy for Crohn's disease. *J Dermatol.* 2010 May;37(5):471-4. [PMID: 20536653]
15. Kotze PG, de Barcelos IF, da Silva Kotze LM. Sarcoidosis during therapy with adalimumab in a Crohn's disease patient: a paradoxical effect. *J Crohns Colitis.* 2013 Dec 1;7(11):e599-600. [PMID: 23849401]

