

Case Presentation

Adult onset unilateral systematized porokeratotic eccrine ostial and dermal duct nevus: a case report

Debabrata Bandyopadhyay and Abanti Saha

Dermatology Online Journal 20 (6): 13

Department of Dermatology, Medical College, Kolkata. 88, College Street, Kolkata 700073. West Bengal. India.

Correspondence:

Debabrata Bandyopadhyay
Medical College, Kolkata
88, College Street, Kolkata 700073. West Bengal. India.
Email: dr_dban@yahoo.com

Abstract

Porokeratotic eccrine ostial and dermal duct nevus (PEODDN) is an uncommon, benign dermatosis that is characterized by asymptomatic grouped keratotic papules and plaques with a linear pattern on the extremities with distinct porokeratotic histopathological features. The lesions usually appear at birth or in childhood, although rare cases of late-onset adult PEODDN have been described. Herein we report a case of adult onset PEODDN with unilateral and segmental involvement.

Keywords: unilateral, systematized, porokeratotic nevus.

Introduction

Porokeratotic eccrine ostial and dermal ductal nevus (PEODDN) is a rare, benign dermatosis with porokeratotic histopathologic features [1]. It is characterized by multiple keratotic, filiform or verrucous, brown to flesh-colored papules or plaques and punctate pits with a linear distribution, usually located on the extremities along Blaschko's lines. The lesions are asymptomatic or mildly pruritic and most often located on acral surfaces, with predominance over the flexural aspects of the hands, palms, and soles. It has a tendency to persist and it usually extends as the child ages [1, 2]. The disease is characterized histologically by well-formed cornoid lamellae occurring in association with dilated eccrine ducts and acrosyringia [3]. The lesions are usually present at birth or in childhood, although cases of late-onset adult PEODDN have been described [4, 5].

Case synopsis

A 23-year-old man presented with moderately itchy papules and small plaques over the left side of his body. The lesions started to appear about three years previously over the inner aspect of the left foot. Over the next few months, similar lesions erupted over the abdomen, neck, and upper back. The condition was associated with moderate itching. The patient had applied various topical medications without any appreciable benefit. The condition had, however, remained stable during the last two years. There was no family history of similar disease and the patient's past medical history was unremarkable. Clinical examination revealed skin-colored as well as brownish hyperkeratotic papules localized to the left side of the body involving post auricular region, neck, shoulder, upper back, chest, lumbar region, abdomen, and medial border of left foot, strictly respecting the midline. The lesions were arranged in linear arrays along Blaschko's lines. Some of the lesions had an excoriated surface. Papules over the foot showed central pits.

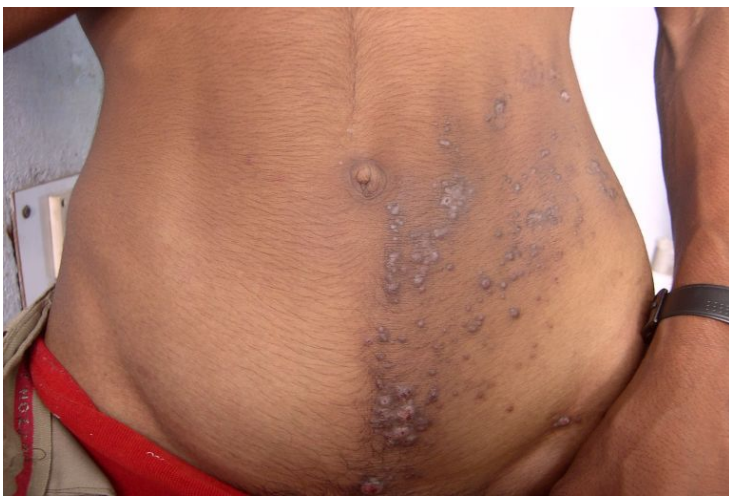

Figure 1. Keratotic papules over abdomen along Blaschko's lines

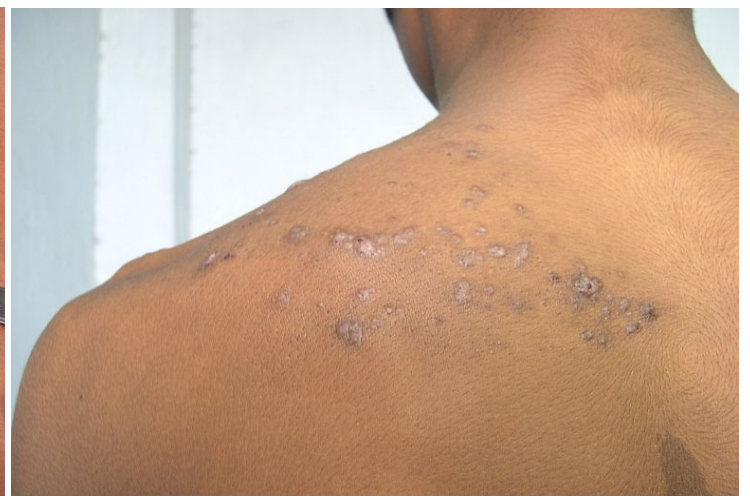

Figure 2. Hyperkeratotic papules over upper back in linear arrangement

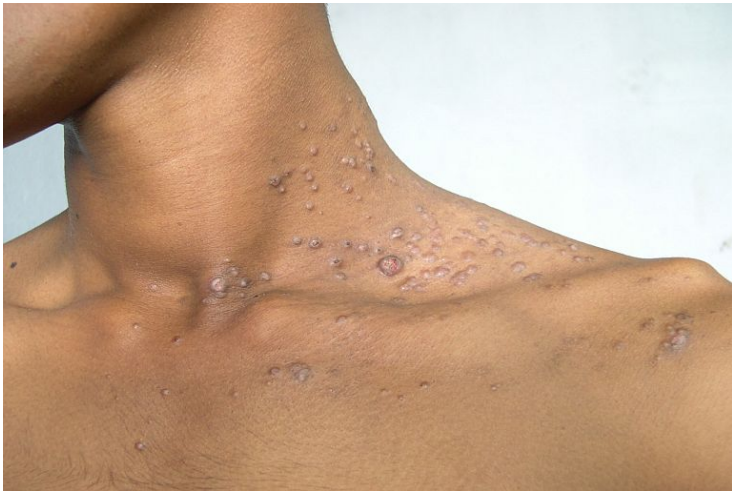

Figure 3. Hyperkeratotic papules with excoriations over left side of the neck, shoulder and upper chest

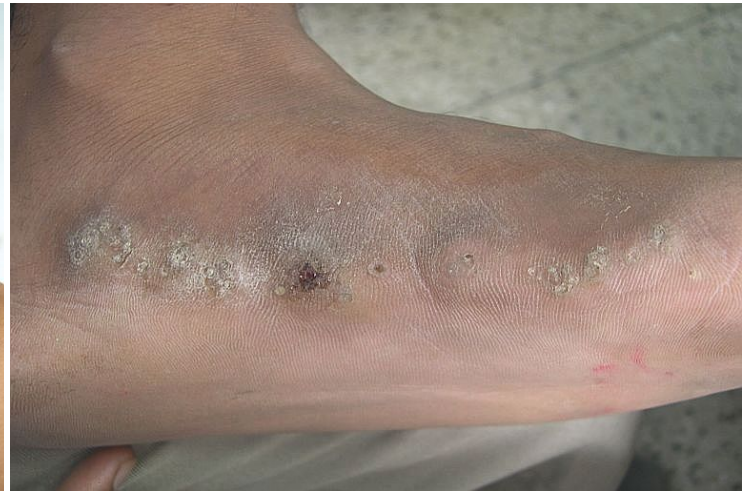

Figure 4. Verrucous papules , some with central pits

The rest of the mucocutaneous and systemic examination showed no gross abnormality. Linear porokeratosis, linear lichen planus, nevus comedonicus, and PEODDN were considered in the differential diagnosis.

Routine hematological and biochemical investigations were within normal limits. Histopathology from a representative skin lesion showed hyperkeratosis, acanthosis, and papillomatosis under low power magnification (100X). Keratotic invaginations with prominent parakeratosis occupying dilated ostia were appreciated. The granular layer was absent below and around the parakeratotic column.

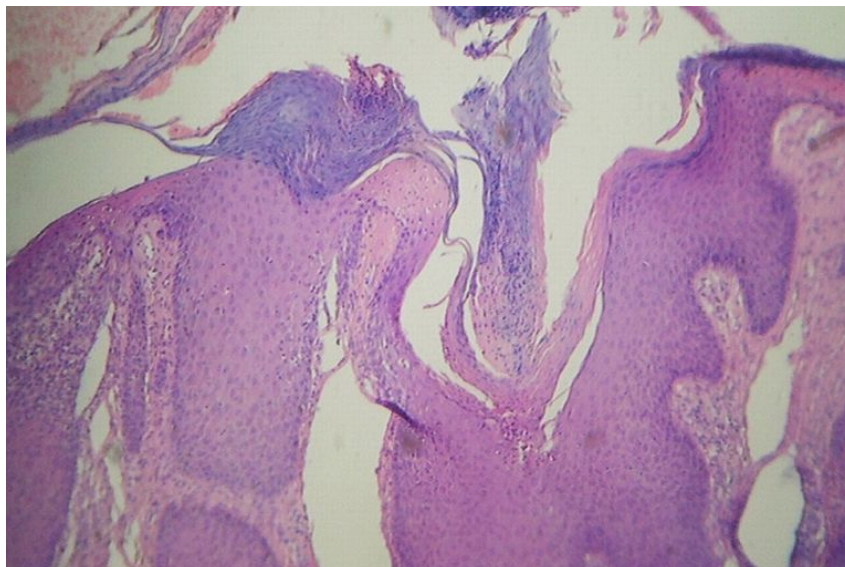


Figure 5. (100X, H&E) Acanthosis, hyperkeratosis and keratotic invagination with a column of parakeratosis below which the granular layer is absent: The adjoining epidermis shows an elevated parakeratotic column.

The absence of a lichenoid infiltrate ruled out lichen planus. Nevus comedonicus was excluded owing to the absence of grouped undeveloped hair follicles with dilated invaginations filled with cornified debris. Based on the clinical and histopathological findings, a final diagnosis of porokeratotic eccrine ostial and dermal duct nevus (PEODDN) was made and the patient was referred for ablative laser therapy. The patient was subsequently lost to follow up; the result of therapy could not be documented.

Discussion

Porokeratotic eccrine ostial and dermal duct nevus (PEODDN) is a condition first reported by Marsden et al in 1979 as “comedo nevus of the palm” [6]. Abell and Reed in 1980 [7] re-defined this rare entity and named it “linear eccrine nevus with comedones.” Other appellations include palmar and plantar pseudocomedo, porokeratotic sweat nevus, and porokeratotic eccrine ostial and hair follicle nevus [3]. Because some patients have involvement of both acrosyringia and acrotrichia, based on the overlapping histologic features, the name “porokeratotic adnexal ostial nevus” was proposed [8].

The pathogenesis of PEODDN is yet to be clarified. It was suggested that PEODDN originates from a circumscribed keratinization abnormality based on carcinoembryonic antigen stain positivity along the ductal lumina through the parakeratotic column of the cornoid lamella [9].

However, the most recent theory is that PEODDN is a mosaic form of keratitis-ichthyosis-deafness (KID) syndrome caused by a mutation in GJB2, encoding a gap junction protein connexin-26 (Cx26) [10]. Connexin proteins are components of gap junctions of aqueous pores, which allow intercellular exchanges of ions and small molecules [11]. Gap junctions mediate intercellular communications in various physiological processes, cellular growth, and differentiation. The mutation in GJB2 causes various disorders, including KID syndrome, Vohwinkel syndrome (VS), Bart-Pumphrey syndrome (BPS), and non-epidermolytic palmoplantar keratoderma (NEPPK) with deafness.

Commonly, PEODDN is found on the palms and soles, clinically manifested as multiple keratotic pits. When other sites are involved, it presents as keratotic papules and plaques resembling linear verrucous epidermal nevus. Our patient had a striking presentation in the form of strictly unilateral systematized linear lesions composed of multiple keratotic papules. Although quite rare, cases of systematized PEODDN have been reported [12, 13, 14].

Cambiaghi et al. proposed that the distribution of PEODDN along Blaschko's lines may be a result of genetic mosaicism [14]. It is usually asymptomatic but occasionally pruritic with or without hyperhidrosis and anhidrosis. Although it is mostly congenital, a review of the literature showed that the frequency of a late-onset variant may be as high as 26% [4, 5].

Histology of PEODDN is characterized by dilated epidermal invaginations filled with parakeratotic plugs. The adjacent epidermis shows parakeratotic columns raised above the rest of stratum corneum. Although intraepidermal eccrine ducts may be visible in the lower portion of the invaginations, many cases show no such connection [14], as in the present case.

There are rare reports of associations with Bowen disease, deafness and development delay, seizure disorder, hemiparesis, scoliosis, hyperthyroidism, sensory polyneuropathy, breast hypoplasia, alopecia, onychodysplasia, and squamous cell carcinoma [15]. Hence, long term follow-up is warranted to diagnose and treat any malignancy.

Treatment options are limited. Some lesions may undergo spontaneous flattening with time [16]. Small and localized lesions may be suitable candidates for surgery. Laser therapy, preferably ultrapulse CO₂ laser, is an acceptable modality because the chances of pigmentary changes and scarring are minimal [17, 18]. Treatments such as topical steroids, retinoids, keratolytics, phototherapy, electrocautery, and cryotherapy have not shown any promising results.

References:

1. Hartman R, Rizzo C, Patel R, Kamino H, Shupack JL. Porokeratosis palmaris et plantaris disseminata or a disseminated late-onset variant of porokeratotic eccrine ostial and dermal ductal nevus (PEODDN) with follicular involvement. *Dermatol Online J.* 2009; 15(8): 8. [PMID: 19891916]
2. Wang NS, Meola T, Orlow SJ. Porokeratotic Eccrine ostial and Dermal Duct Nevus: A report of 2 cases and review of literature. *Am J Dermatopathol* 2009; 31:582-6. [PMID: 19590415]
3. Sassmannshausen J, Bogomilsky J, Chaffins M. Porokeratotic eccrine ostial and dermal duct nevus: A case report and review of literature. *J Am Acad Dermatol* 2000; 43:364-7. [PMID: 10901725]
4. Stoof TJ, Starink TM, Nieboer C. Porokeratotic eccrine ostial and dermal duct nevus. Report of a case of adult onset. *J Am Acad Dermatol.* 1989; 20:924-7. [PMID: 2715447]

5. Valks R, et al. Porokeratotic eccrine ostial and dermal ductal nevus of late onset: more frequent than previously suggested? *Dermatology* 1996; 193: 138. [PMID: 8884152]
6. Marsden R, Fleming K, Dawber R. Comedo naevus of the palm--a sweat duct naevus? *Br J Dermatol* 1979; 101:717-22. [PMID: 93967]
7. Abell E, Read S. Porokeratotic eccrine ostial and dermal duct naevus. *Br J Dermatol* 1980; 103: 435-41. [PMID: 7437310]
8. Goddard DS, Rogers M, Frieden IJ, Krol AL, White CR, Jayaraman AG, Robinson-Bostom L, Bruckner AL, Ruben BS. Widespread porokeratotic adnexal ostial nevus: Clinical features and proposal of a new name unifying porokeratotic eccrine ostial and dermal duct nevus and porokeratotic eccrine and hair follicle nevus. *J Am Acad Dermatol.* 2009; 61: 1060-69.[PMID: 19664847]
9. Masferrer E, Vicente MA, Bassas-Vila J, Rovira C, González-Enseñat MA. Porokeratotic eccrine ostial and dermal duct naevus: report of 10 cases. *J Eur Acad Dermatol Venereol.* 2010; 24(7):847-51. [PMID: 19925595]
10. Easton JA, Donnelly S, Kamps MA, Steijlen PM, Martin PE, Tadini G, et al. Porokeratotic eccrine nevus may be caused by somatic Connexin 26 mutations. *J Invest Dermatol* 2012; 132: 2184–2191. [PMID: 22592158]
11. Scott CA, Kelsell DP. Key functions for gap junctions in skin and hearing. *Biochem J* 2011; 438: 245–254. [PMID: 21834795]
12. Murata Y, Nogita T, Kawashima M, Hidano A. Unilateral systematized porokeratotic eccrine ostial and dermal duct nevi. *J Am Acad Dermatol* 1991; 24: 300-1. [PMID: 2007686]
13. Cobb MW, Vidmar DA, Dilaimy MS. Porokeratotic eccrine ostial and dermal duct nevus: a case of systematized involvement. *Cutis.* 1990; 46(6): 495-7. [PMID: 2269022]
14. Cambiaghi S, Gianotti R, Caputo R. Widespread porokeratotic eccrine ostial and dermal duct nevus along Blaschko lines. *Pediatr Dermatol.* 2007; 24(2): 162-67. [PMID: 17461816]
15. Kumar P, Mondal AK, Ghosh K, Mondal A, Gharami RC, Chowdhury SN. Multiple keratotic papules on palm. *Dermatol Online J.* 2012; 18(1):10. [PMID: 22301047]
16. Mazuecos J, OrtegaM, Rios JJ, Camacho F. Long-term involution of unilateral porokeratotic eccrine ostial and dermal duct naevus. *Acta Derm Venereol* 2003; 83:147-9. [PMID: 12735653]
17. KimWJ, Choi SR, Lee HJ, Kim DH, YoonMS. Porokeratotic Eccrine Ostial and Dermal Duct Nevus Showing Partial Remission by Topical Photodynamic Therapy. *Ann Dermatol* 2011; Vol. 23(. 3): S322-25. [PMID: 22346268]
18. Leung CS, Tang WY, Lam WY, Fung WK, Lo KK. Porokeratotic eccrine ostial and dermal duct naevus with dermatomal trunk involvement: literature review and report on the efficacy of laser treatment. *Br J Dermatol.* 1998; 138(4):684-8. [PMID: 9640380]