

Case presentation

Infantile myofibroma: a firm, round plaque in an infant.

Shinya Amano¹, Mark Halsey MD¹, Mariko Yasuda MD², Patrick O'Donnell DO¹, Courtney Csikesz MD³

Dermatology Online Journal 21 (10): 7

¹**University of Massachusetts Medical School**

²**Massachusetts General Hospital, Department of Dermatology**

³**Roger Williams Medical Center, Department of Dermatology and Dermatology Professionals, Inc**

Correspondence:

Courtney Csikesz, MD
Department of Dermatology
Roger Williams Medical Center
825 Chalkstone Avenue
Providence, RI, 02908
Email: courtneycsikesz@gmail.com

Abstract

Infantile myofibroma is a rare fibromatous tumor that is variable in presentation and is frequently mistaken for hemangioma or rhabdomyosarcoma. We describe a 14-month-old male who presented with multiple, enlarging, firm lesions on the shoulder. Biopsy revealed a proliferation of small spindle cells with myxoid and hyalinized stroma infiltrating into the superficial adipose tissue. We provide a brief review of the clinical presentation, histopathologic features, management and recent advances in our understanding of this rare condition.

Keywords: Infantile Myofibroma, Myofibromatosis, Fibromatous Tumor

Case synopsis

A 14 month old male presented with a 3-month history of a “bump” on the right posterior shoulder. The lesion had not changed in size since it was first noticed, but a new, smaller lesion had appeared next to the first within 3 days of presentation. There was no bleeding, pruritus or pain at the site. Birth history and past medical history were unremarkable except for mild seborrheic dermatitis of the scalp. Physical exam revealed a skin-colored to pink, 11x8 mm, well-demarcated, round, firm nodule with telangiectasia and a central depression with a fine scale in the center. Additionally, a similar 4 mm papule lay superior to the larger lesion (Figure 1, A-C). A punch biopsy was obtained.

Histopathologic analysis of the biopsy specimen revealed a proliferation of small spindle cells with scant eosinophilic cytoplasm and tapering nuclei within myxoid and hyalinized stroma. In some fields, small, whorled nodules of plump eosinophilic spindle cells with chondromyxoid and hyalinized changes were present. The proliferation occupied the entire dermis, was not encapsulated, and infiltrated into the superficial adipose tissue. There were no foci of necrosis or vascular invasion present. Immunohistochemical stains showed that lesional cells were positive for smooth muscle actin (SMA) and vimentin, and negative for S100, Factor XIIIa, epithelial membrane antigen (EMA), and desmin. CD34 highlighted vasculature, but was negative in tumoral cells. These morphologic and immunophenotypic features were consistent with an infantile myofibroma

(myofibromatosis). We discussed the options of surgical excision versus careful monitoring for spontaneous resolution with the patient's parents. They preferred definitive treatment and opted for surgery. The lesions were excised under general anesthesia with a 3mm margin (Figure 2, A and B). After ten months of follow-up, there had been no evidence of recurrence.

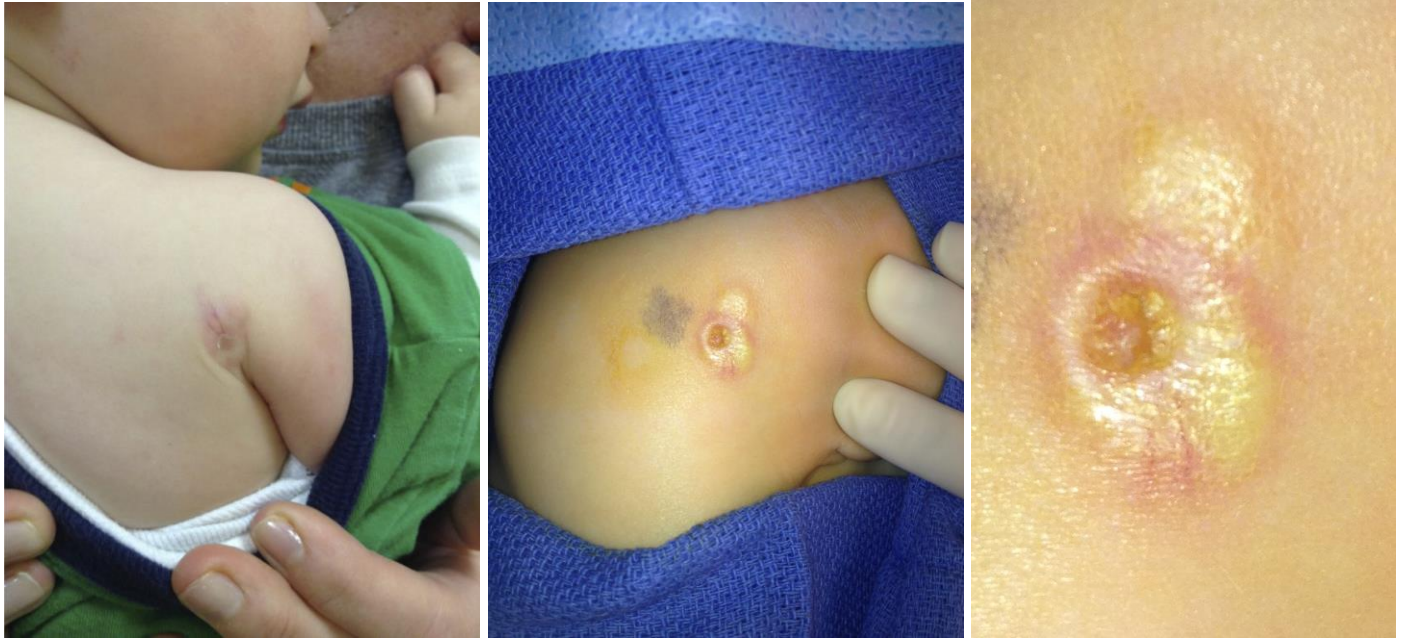

Figure 1A-C. (A) A well-demarcated, round, firm nodule with telangiectasia and a central depression located on the patient's posterior shoulder. (B) The same lesion at the time of excision under general anesthesia. The lesion and surrounding skin had been treated with betadine. Applying tension to the surrounding skin revealed the bulky nature of the lesion. (C) Close-up view of (B).

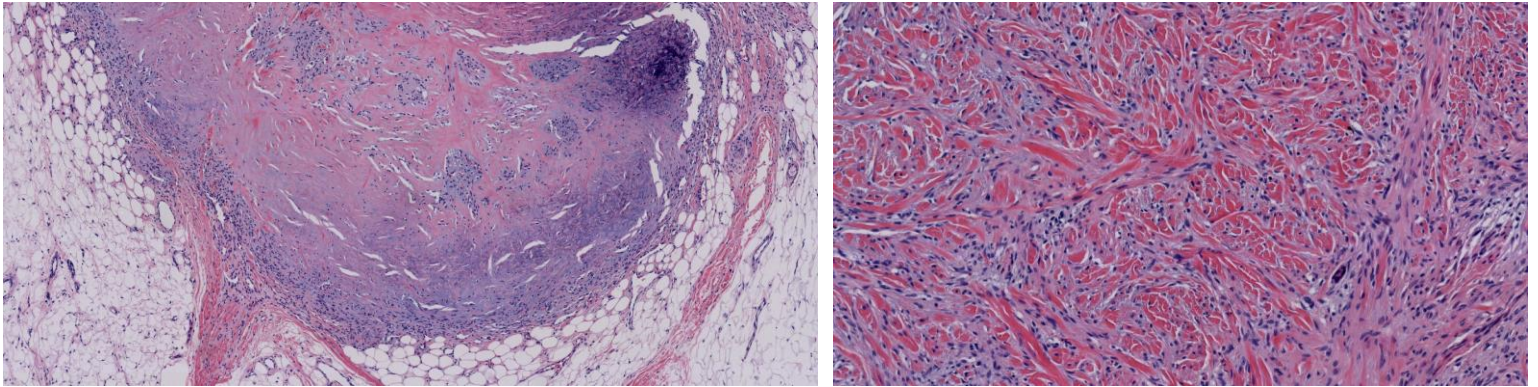


Figure 2A and 2B. Histologic images of the excisional specimen revealed a myofibroblastic nodule pushing into the subcutaneous fat, with central hyalinization and a pseudo-chondroid appearance. On the perimeter of the nodule, there are primitive, small, round and spindle cells. Higher magnification revealed dermal interstitial proliferation of bland spindle cells with tapered nuclei and eosinophilic cytoplasm. Hematoxylin-eosin, original magnification x100 (A) and x200 (B).

Discussion

Infantile myofibroma was initially characterized by Chung and Enzinger in 1981, who recognized the features of the disease as a distinct subset of conditions formerly included under the general term “congenital generalized myofibromatosis” [1]. While rare, infantile myofibroma is the most common fibromatous tumor in children [2]. The condition is approximately twice as common in males as in females [1,3]. Lesions are often solitary, arising in the dermis, subcutaneous or deep soft tissue, and most frequently involve the head, neck and trunk. However, lesions can also occur in a multicentric pattern, in which there are multiple or numerous lesions that, unlike the solitary form of disease, tend to involve viscera or bone [3]. In both forms of the disease, the vast majority of these lesions appear in the first two years of life, with approximately half of cases being present at birth [1].

Myofibromas typically are well-circumscribed, firm, rubbery, smooth nodules 0.5-7.0 cm in diameter [1]. Lesions can be superficial and mobile, or may be deeper and fixed [1]. Lesion color is highly variable, with reports of dusky, brown, beige, red, and bluish, and telangiectasia can be present [3,4]. Most cases are not suspected clinically, being frequently mistaken for hemangioma or rhabdomyosarcoma, and are not diagnosed until after biopsy [4].

Patients with biopsy-proven myofibroma, particularly those with multicentric and generalized variants, should undergo radiologic workup to evaluate for skeletal and visceral involvement. While no definitive guidelines exist, many patients will receive chest and skeletal radiographs, which are frequently diagnostic [3,5]. Chest radiographs in particular are important due to the high mortality in patients with pulmonary involvement [5]. Abdominal, cardiac and transfontanellar ultrasound, as well as electrocardiography, can reveal visceral disease [3]. Because multicentric and generalized myofibromas can progress, periodic evaluation is advisable [3,5].

While most cases appear to be sporadic, there have been several reports of autosomal dominant inheritance pattern in infantile myofibromatosis, and the *PDGFRB* gene was recently identified as the mutation present in a two separate reports describing a total of twelve families with inherited infantile myofibromatosis [6,7]. Platelet-derived growth factor signaling is involved in cellular proliferation, differentiation, and survival of mesenchymal cells such as myofibroblasts [6,7].

Treatment options vary widely for infantile myofibroma. Solitary and even multicentric lesions that are confined to the skin and subcutaneous tissues without visceral involvement frequently regress spontaneously, and may be managed by close clinical observation alone after the diagnosis is made. However, calcification and atrophic scars can remain after lesion regression [3]. When lesions affect function or are cosmetically unacceptable, surgical excision is the treatment of choice. Even with clear margins, however, recurrence after excision is not uncommon, and frequent follow-up evaluations are indicated [3,8]. Conversely, in multicentric infantile myofibroma with extensive visceral involvement, mortality can be as high as 80% [5]. Extensive surgery has been reported to be beneficial for multicentric disease [8], as has chemotherapy [9].

References

1. Chung EM, Enzinger FM. Infantile myofibromatosis. *Cancer*. 1981; 48(8):1807-18. [PMID: 7284977]
2. Wiswell TE, Davis J, Cunningham BE, et al. Infantile myofibromatosis: the most common fibrous tumor of infancy. *J Pediatr Surg*. 1988; 23(4):315-8. [PMID: 3385581]
3. Mashiah J, Hadj-Rabia S, Domp martin A, et al. Infantile myofibromatosis: a series of 28 cases. *J Am Acad Dermatol*. 2014; 71(2):264-70. [PMID: 4894456]
4. Stanford D, and Rogers M. Dermatological presentations of infantile myofibromatosis: a review of 27 cases. *Austral J Dermatol*. 2000; 41(3):156-61. [PMID: 10954986]
5. Brill PW, Yanolow DR, Langer LO, et al. Congenital generalized fibromatosis: case report and literature review. *Pediatr Radiol*. 1982; 12(6):269-78. [PMID: 7162878]
6. Cheung YH, Gayden T, Campeau PM, et al. A recurrent *PDGFRB* mutation causes familial infantile myofibromatosis. *Am J Human Genet*. 2013; 92(6):996-1000. [PMID: 23731537]
7. Martignetti JA, Tian L, Li D, et al. Mutations in *PDGFRB* cause autosomal-dominant infantile myofibromatosis. *Am J Human Genet*. 2013; 92(6):1001-7. [PMID: 23731542]
8. Cofer BR, Vescio PJ, Weiner, ES. Infantile fibrosarcoma: complete excision is the appropriate treatment. *Ann Surg Oncol*. 1996; 3(2):159-61. [PMID: 8646516]
9. Gandhi MM, Nathan PC, Weitzman S, Levitt GA. Successful treatment of life-threatening generalized infantile myofibromatosis using low-dose chemotherapy. *J Ped Heme/Onc*. 2003; 25(9):750-4. [PMID: 12972815]