

## **Case Presentation**

### **Eccrine poromatosis in a patient with acute myeloid leukemia following chemotherapy**

**Marisa Garshick, Ersilia M. DeFilippis, Joanna Harp, Jalong Gaan**

**Dermatology Online Journal 20 (11): 11**

**New York Presbyterian/Weill Cornell Medical College**

#### **Correspondence:**

Marisa Garshick, MD  
Department of Dermatology  
New York Presbyterian/Weill Cornell Medical College  
marisa.garshick@gmail.com

## **Abstract**

Eccrine poromas are rare, benign adnexal tumors that often occur as solitary papules. Rarely, eccrine poromas can present as multiple lesions, which is referred to as eccrine poromatosis. We report a case of eccrine poromatosis occurring on the palms and soles occurring after chemotherapy in a patient with a history of acute myeloid leukemia.

**Keywords: eccrine poroma, eruptive poromatosis, chemotherapy**

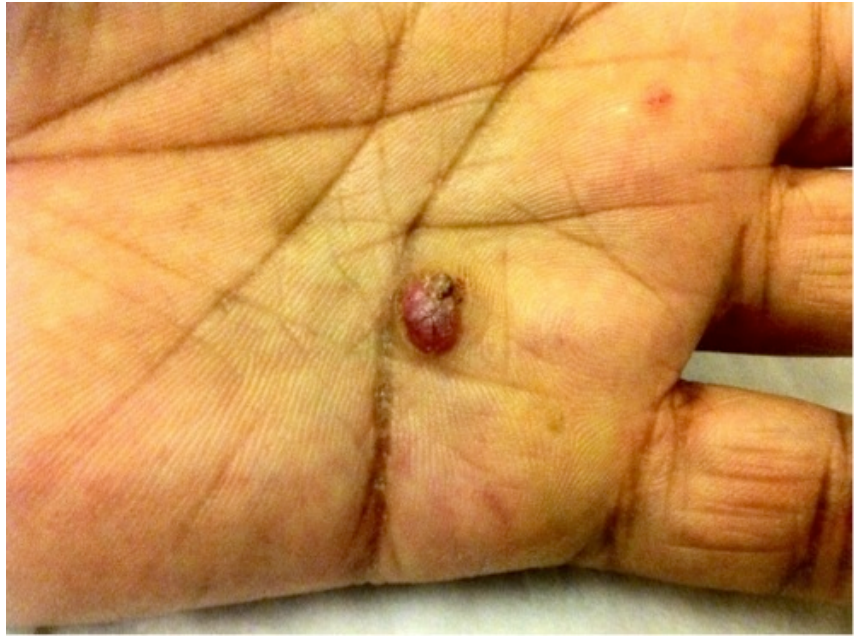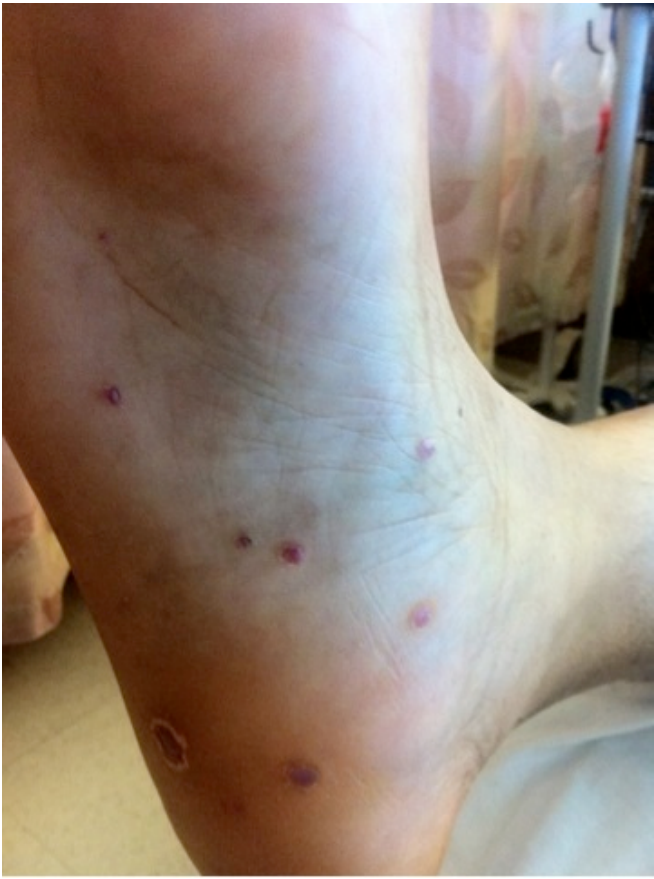## **Introduction**

Eccrine poromas, derived from the intraepidermal portion of the eccrine sweat duct, are rare, benign adnexal tumors. Traditionally, poromas were thought to derive solely from eccrine origin, however, it was later found that poromas can be a proliferation of either apocrine or eccrine glands[1]. They often occur as a solitary, slow-growing papule in areas with a high concentration of eccrine sweat glands, such as acral surfaces [2], although they can also occur in other areas including the neck, chest, nose and eyelids [3]. It is especially rare for an eccrine poroma to occur as multiple lesions, either in clusters or widely disseminated, referred to as poromatosis [4]. Here we report a case of eccrine poromatosis in a patient with a history of acute myeloid leukemia.

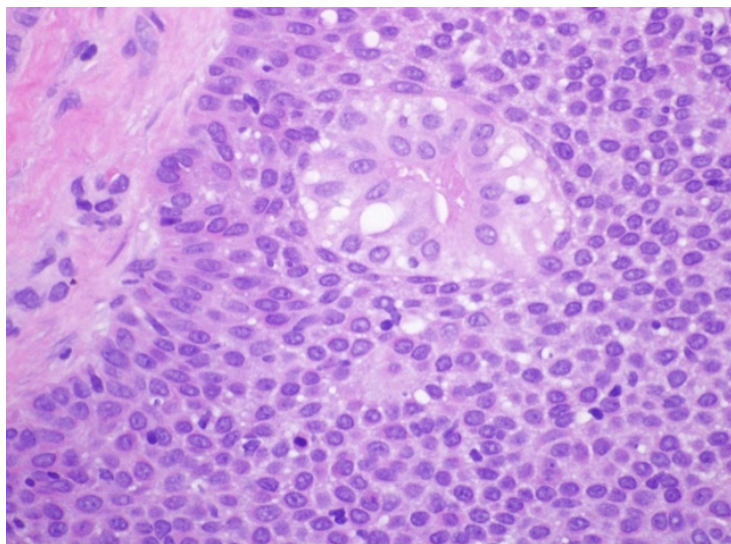
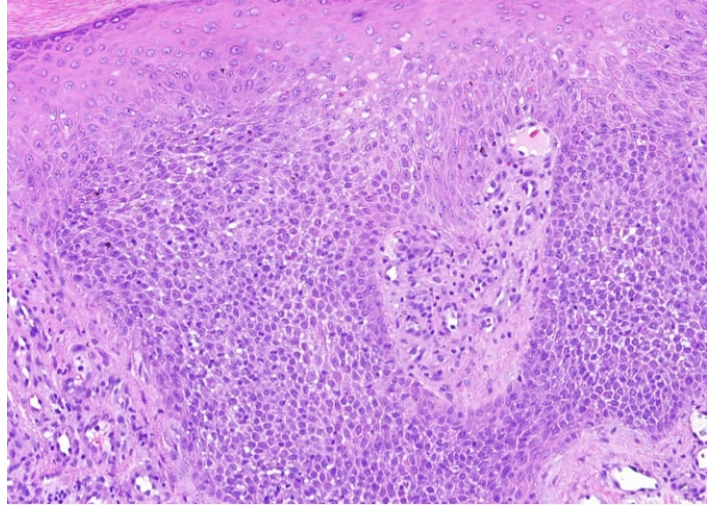
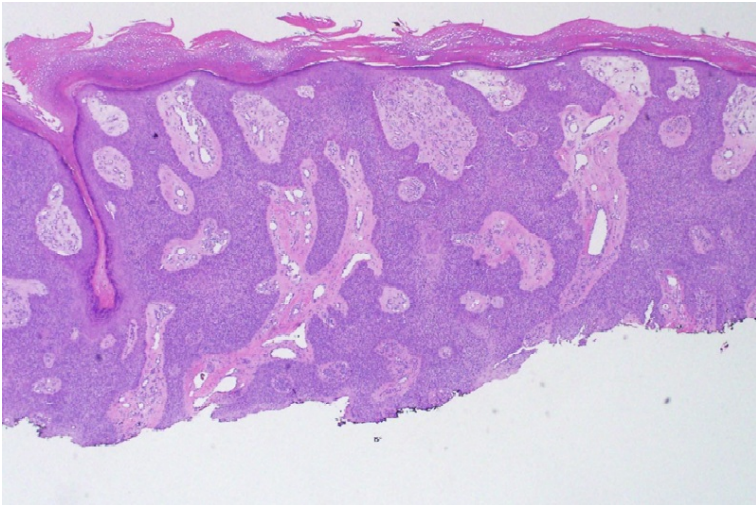
## **Case synopsis**

The patient is a 46 year-old man with a history of acute myeloid leukemia (AML) diagnosed in 2004 who achieved complete remission following induction chemotherapy with cytarabine, daunorubicin, and etoposide and autologous stem cell transplant. He was admitted to the hospital with signs and symptoms suggestive of bacterial meningitis. Dermatology was consulted to evaluate multiple skin-growths on his palms and soles. The first lesion appeared several months after his transplant in 2004, but new lesions continued to appear over the last 10 years. He denied pruritus or pain, but reported occasional bleeding.

On examination, there were numerous 2-5 mm red and violaceous, dome-shaped papules on his palms and soles. Some were slightly pedunculated or exophytic with an associated collarette of scale while others were more sessile. He had a total of 22 lesions. Dermoscopy revealed glomerular and irregular branching vessels. A shave excision of a lesion on his left palm showed an intraepidermal clonal proliferation of small monomorphic-appearing cuboidal epithelial cells of acrosyringal eccrine ductal derivation with a few scattered mitotic figures and focal inflammation along with vascular ectasia and hyperkeratosis. A second papule was biopsied which demonstrated similar features and a diagnosis of eccrine poromatosis was established.



**Figure 1.** Multiple red, dome-shaped papules on soles. **Figure 2.** Red, hyperkeratotic papule



## Discussion

In 1970, the first case of eccrine poromatosis was reported in a 65-year old woman with multiple soft angiomatous, sessile papules on the palms and soles. The patient had no history of systemic disease or treatment with radiation or chemotherapy [4]. Since that time, there have been a few reports of eccrine poromatosis associated with radiation [5,6,7,8], pregnancy [9,10], and trauma [11]. Thirteen of eighteen reported cases to date had been associated with chemotherapy, radiation or bone marrow transplantation [12]. While there are cases of eccrine poromatosis in patients treated with chemotherapy with or without radiation for Non-Hodgkin's lymphoma, malignant fibrous histiocytoma [13] and testicular lymphoma [14], to our knowledge, this is the first association of AML and eccrine poromatosis following chemotherapy.

The pathophysiology of eccrine poromatosis is unclear. Genes such as cyclin D1, Retinoblastoma (Rb), p53 and others may play a role in the tumorigenesis of eccrine poromatosis and eccrine porocarcinomas [15,16]. This report and others in the literature suggest that chemotherapy may play a role in the pathogenesis of eccrine poromatosis. Though our patient first developed lesions soon after his induction chemotherapy and stem-cell transplant, he continued to develop lesions 10 years later, suggesting a delayed effect.

It is well known that various chemotherapies, including the regimen given to our patient, can cause pathologic change of the eccrine glands including neutrophilic eccrine hidradenitis (NEH) and eccrine squamous syringometaplasia [17]. Eccrine squamous syringometaplasia results from cutaneous extravasation of chemotherapy agents and has been reported in a patient treated with doxorubicin, which is in the same class as daunorubicin [18]. These findings suggest that eccrine poromatosis may be related to the accumulation of the medication in the sweat glands and ducts, with subsequent changes in the eccrine unit. However, individual variation including genetic predisposition, trauma and hyperhidrosis likely also plays a role, as development of these lesions after chemotherapy is rare. Further research should consider investigating the role of hyperhidrosis, genetic factors, and trauma in this condition.

## References

1. Harvell JD, Kerschmann RL, LeBoit PE. Eccrine or apocrine poroma? Six poromas with divergent adnexal differentiation. *Am J Dermatopathol.* 1996;18(1):1-9. [PMID:8721584]
2. Hashimoto K, Lever W. Tumors of skin appendages. In: *Dermatology in general medicine.* 4th ed. New York: McGraw-Hill; 1993:873-98.
3. Navi D, Fung M, Lynch PJ. Poromatosis: the occurrence of multiple eccrine poromas. *Dermatol Online J.* 2008;14(1):3. [PMID:18319020]
4. Goldner R. Eccrine poromatosis. *Arch Dermatol.* 1970;101(5):606-8. [PMID: 5444082]
5. Kurokawa M, Amano M, Miyaguni H, Tateyama S, Ogata K, Idemori M, Setoyama M. Eccrine poromas in a patient with mycosis fungoides treated with electron beam therapy. *Br J Dermatol.* 2001;145(5):830-3. [PMID:11736912]
6. Ullah K, Pichler E, Fritsch P. Multiple eccrine poromas arising in chronic radiation dermatitis. *Acta Derm Venereol.* 1989;69(1):70-3. [PMID:2563613]
7. Mahlberg MJ, McGinnis KS, Draft KS, Fakharzadeh SS. Multiple eccrine poromas in the setting of total body irradiation and immunosuppression. *J Am Acad Dermatol.* 2006;55(2 Suppl):S46-9. [PMID:16843124]
8. Miura T, Yamamoto T. Eruptive poromatosis following radiotherapy. *Am J Dermatopathol.* 2013;35(5):615-7. [PMID:23676317]
9. Ban M, Kitajima Y. A case of rapidly-growing eccrine poroma during pregnancy. *J Dermatol.* 1997;24(8):554-5. [PMID:9301154]
10. North JP, Lo J, Landers M. Poromatosis in pregnancy: a case of 8 eruptive poromas in the third trimester. *Cutis.* 2012;89(2):81-3. [PMID:22474731]
11. Hyman AB, Brownstein MH. Eccrine poroma. An analysis of forty-five new cases. *Dermatologica.* 1969;138(1):29-38. [PMID:5764298]
12. Hashizume S, Ansai S-I, Matsuoka Y, Omi T, Kawana S. Case of multiple apocrine poroma in a patient without receiving radiation or chemotherapy. *J Dermatol.* 2014;41(2):174-5. [PMID:24433245]
13. Fujii K, Aochi S, Takeshima C, Ohtsuka M, Hamada T, Asagoe K, Aoyama Y, Morizane S, Itawtsuki K. Eccrine poromatosis associated with polychemotherapy. *Acta Derm Venereol.* 2012;92(6):687-90. [PMID:22294042]
14. Deckelbaum S, Toulouei K, Shitabata PK, Sire DJ, Horowitz D. Eccrine poromatosis: case report and review of the literature. *Int J Dermatol.* 2014;53(5):543-8. [PMID:23968240]
15. Al-Qattan MM, Al-Turaiqi TM, Al-Oudah N, Arab K. Benign eccrine poroma of the dorsum of the hand: predilection for the nail fold and P53 positivity. *J Hand Surg Eur Vol.* 2009;34(3):402-3. [PMID:19457912]

16. Chen S-Y, Takeuchi S, Moroi Y, Kido M, Hayashida S, Qian Y, Tomoeda H, Uenotsuchi T, Urabe K, Furue M, Tu YT. Significance of cyclin D1-, product of retinoblastoma (pRb), p53, p63 and p73 expression in eccrine poroma and eccrine porocarcinoma. *J Dermatol Sci.* 2009;56(1):69-72. [PMID:19643581]
17. Nikkels AF, Hansen I, Collignon J, Fassotte MF, Fillet G, Piérard GE. Neutrophilic eccrine hidradenitis. A case report. *Acta Clin Belg.* 1993;48(6):397-400. [PMID: 8128819]
18. Gallo E, Llamas-Velasco M, Navarro R, Fraga J, García-Diez A. Eccrine squamous syringometaplasia secondary to cutaneous extravasation of docetaxel: report of three cases. *J Cutan Pathol.* 2013;40(3):326-9. [PMID:23170995]