

Photo Vignette

Self regressing skin-colored papules with acneiform scarring over the face

Rajesh Kumar Mandal¹, Arup De Sarkar¹, Sudip Kumar Ghosh²

Dermatology Online Journal 20 (8): 15

¹Department of Dermatology, North Bengal Medical College, Darjeeling, India

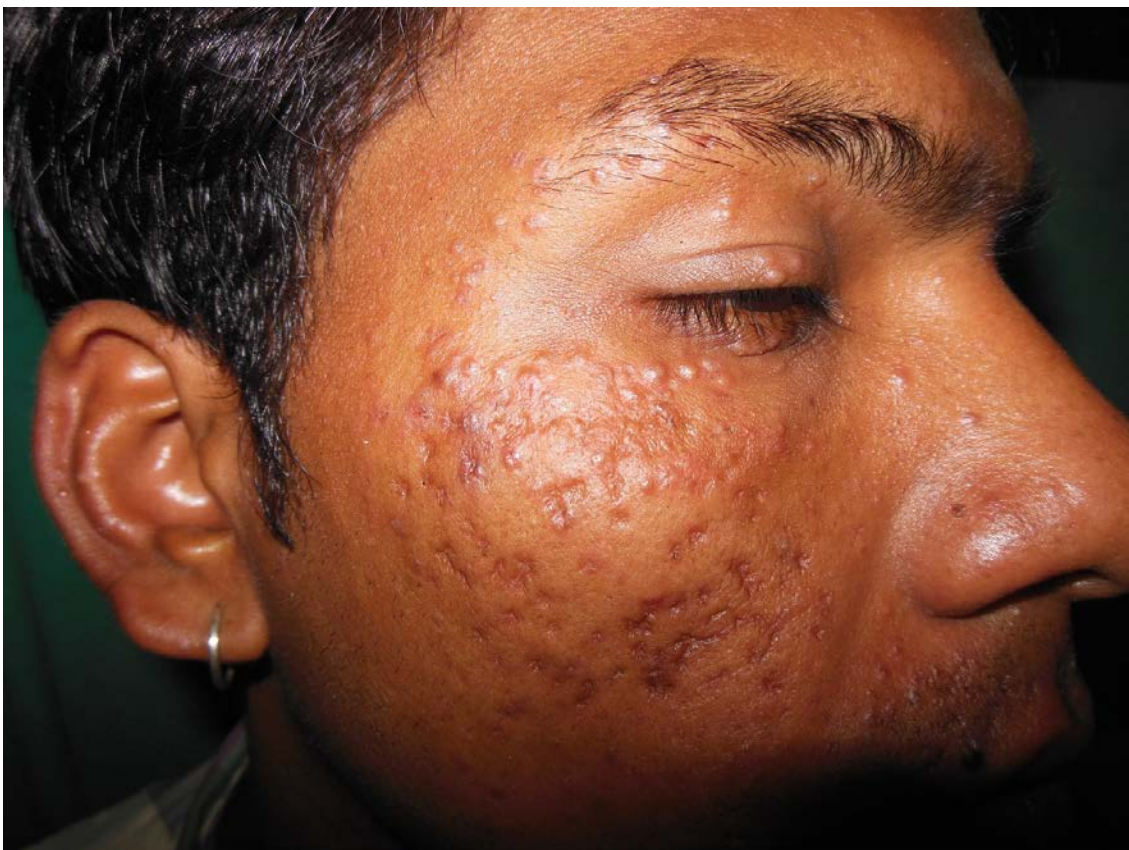²Department of Dermatology, Venereology, and Leprosy, RG Kar Medical College, Kolkata, India

Correspondence:

Rajesh Kumar Mandal
Assistant Professor
Department of Dermatology
North Bengal Medical College
Darjeeling, India
drrajeshkumar.mandal07@gmail.com

Abstract

Lupus miliaris disseminata faciei is a chronic inflammatory dermatosis of unknown etiology, which mostly involves the face in young adults. Earlier attempts had been made to relate it to tuberculosis, rosacea, and sarcoidosis without any strong evidence. For the past few years it has been considered as a distinct entity by various authors and was given a new nomenclature, “facial idiopathic granulomas with regressive evolution” (FIGURE). We also support this new nomenclature and present a young man with facial idiopathic granulomas and scarring consistent with this diagnosis.



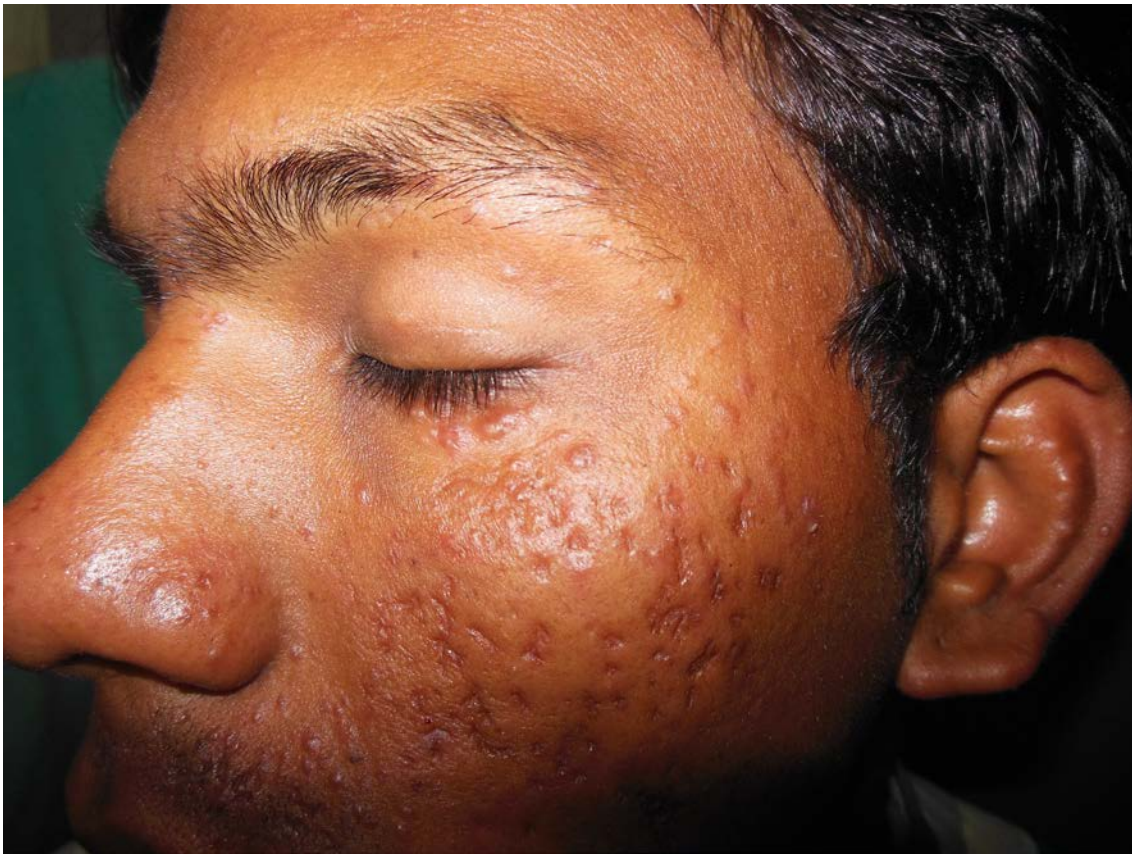

Figure1 & 2. Multiple skin colored papules involving eyelids, cheek, nose and forehead with acneform scarring

Case synopsis

A 21-year-old man presented with multiple asymptomatic skin-colored, smooth, monomorphic papules along with multiple scars over his face (Figure1). The lesions were present for 1 year and first appeared over the cheeks and spreaded to involve the eyelids and ears. A few lesions healed with scarring while new lesions continued to appear. There was no history of any systemic disease or topical drug administration. There was no seasonal variation and family history was unremarkable. Cutaneous examination showed multiple skin-colored to yellowish, smooth-surfaced, monomorphic papules with some acneiform scars distributed over cheeks, nose, forehead, eyelids, and ears (Figure2). A punch biopsy was taken from a representative papule.

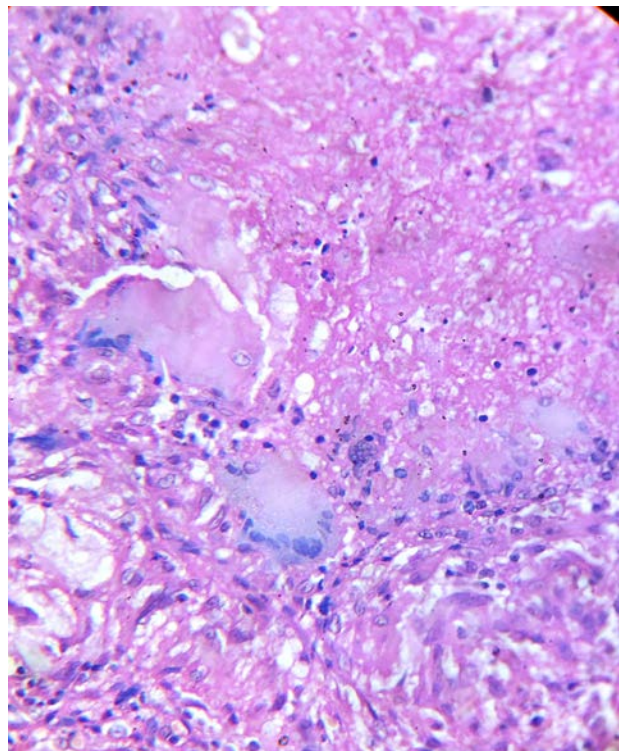
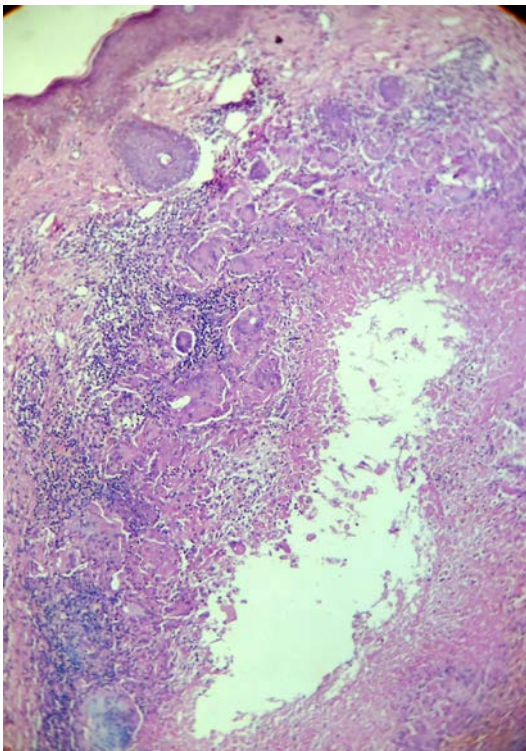


Figure3. Epithelioid cell granuloma with central caseation (H&E X100). **Figure 4.** Epithelioid cell, Langerhans' giant cell, and lymphocytic infiltration with central caseation necrosis (H&E X400)

Histopathological examination of the skin biopsy specimen showed epithelioid cell granulomas with epithelioid cell, Langhans' giant cell, and lymphocytic infiltration (Figure 3). There was central caseation (Figure 4). Complete blood count, serum angiotensin converting enzyme inhibitor level, serum calcium level, Mantoux test, and chest radiography were within normal limits. Culture for mycobacterium tuberculosis was negative.

Discussion

Lupus miliaris disseminata faciei (LMDF) is an uncommon inflammatory dermatosis of unknown etiology characterized by skin-colored, smooth-surfaced, monomorphic papules distributed symmetrically over the central part of the face involving cheeks, chin, nose, and eyelids, although there are some reports of extrafacial involvement [1]. Diascopy often shows an apple-jelly appearance of the papules. The most common age of presentation is the early 20s, although it has been reported in a 71-year-old individual [2]. The lesions are self-limiting and completely resolve within 2 years with or without scarring. The histology shows typical epithelioid cell granulomas with central caseation.

The exact etiology of LMDF is not known. Various terms have been used to describe this clinicopathologic entity. In 1978, the term *disseminated follicular lupus* was used by Fox to describe the condition [3]; Radcliffe-Crocker named it *acne agminata* in 1903 [4]. Earlier, it was thought to be a tuberculid, but studies have failed to demonstrate *Mycobacterium tuberculosis* or other mycobacterial diseases by means of culture or polymerase chain reaction [5]. *Demodex folliculorum* was thought to be the causative organism by some authors but again this claim lacks definite evidence [6]. Association with the hair follicle is not present in all cases [7].

Some authors consider LMDF as a variant of rosacea and consider it as a self-limiting granulomatous form of rosacea. Clinically, both can be similar, but there are many points that differentiate the two. The natural history with spontaneous resolution, equal gender distribution, lack of ocular involvement [8], and caseation necrosis on histology [9] strongly differentiates LMDF from rosacea.

Skowron et al proposed a name change from LMDF to facial idiopathic granulomas with regressive evolution (FIGURE) [2]. Although this nomenclature does not appear to have been widely accepted we think the name 'FIGURE' is more appropriate because it avoids linking the condition to acne, rosacea, or tuberculosis.

Various drugs have been reported to be used in treatment of LMDF with low dose prednisolone [10] and dapsone [11] being most effective. Isotretinoin and tetracycline showed variable response. Clofazimine was found effective in one study [12].

References

1. Bedlow AJ, Otter M, Marsden RA. Axillary acne agminata (lupus miliaris disseminatus faciei). Clin Exp Dermatol 1998;23:125-8. [PMID:9861743]
2. Dekio S, Jidoi J, Imaoka C. Lupus miliaris disseminatus faciei-report of a case in an elderly woman. Clin Exp Dermatol 1991;16:295-6. [PMID:1794175]
3. Fox T. Clinical lecture on disseminated follicular lupus (simulating acne). Lancet. 1878;13:35-36.
4. Radcliffe-Crocker H. Diseases of the Skin. 3rd ed. London, England: Lewis; 1903.
5. Hoddak E, Trattner A, Feuerman H, Feinmesser M, Tsvieli R, Mitrani-Rosenbaum S et al. Lupus miliaris disseminatus faciei- the DNA of mycobacterium tuberculosis is not detectable in active lesions by polymerase chain reaction. British J Dermatol 1997;137:614-9. [PMID:9390342]
6. Ruffi T, Buchner SA. T cell subsets in acne rosacea lesions and possible role of Demodex Folliculorum. Dermatologica 1984;169:1-5. [PMID:6236113]
7. Shitara A. Clinicopathological and immunological studies of lupus miliaris disseminatus faciei. J dermatol 1982;9:383-95. [PMID:6761380]
8. Alpek EK, Merchant A, Pinar V, Foster CS. Ocular rosacea. Patient characteristics and follow up. Ophthalmology 1997;104:1863-7. [PMID:9373118]
9. Helm KF, Menz J, Gibson LE, Dicken CH. A clinical and histopathologic study of granulomatous rosacea. J Am Acad Dermatol. 1991;25(6, pt 1):1038-1043. [PMID:1839796]
10. Uesugi Y, Aiba S, Usuba M, et al. Oral prednisone in the treatment of acne agminata. Br J Dermatol. 1996;134:1098-1100. [PMID:8763432]
11. Kumano K, Tani M, Murata Y. Dapsone in the treatment of miliaris lupus of the face. Br J Dermatol. 1983;109:57-62. [PMID:6860572]
12. Seukeran DC, Stables GI, Cunliffe WJ, et al. The treatment of acne agminata with clofazimine. Br J Dermatol. 1999;141:596597. [PMID:10583095]