

Case presentation

Generalized granuloma annulare in a folliculocentric distribution

Lisa R Rothman MD, Adnan Mir MD, and Shane A Meehan MD

Dermatology Online Journal 21 (12): 9

New York University School of Medicine

Special Guest Editor: Nicholas A Soter MD

Abstract

We present a 69-year-old man with type 2 diabetes mellitus and a five-year history of an eruption of follicular pustules, papules, and nodules, which was identified histopathologically as folliculocentric granuloma annulare (GA). Folliculocentric generalized GA is a rarely reported variant of GA, in which the palisading histiocytes form focal granulomas in a follicular pattern. In this case, the GA may represent an isotopic phenomenon, with lesions developing in hair follicles that were previously affected by a suppurative folliculitis.

Case synopsis

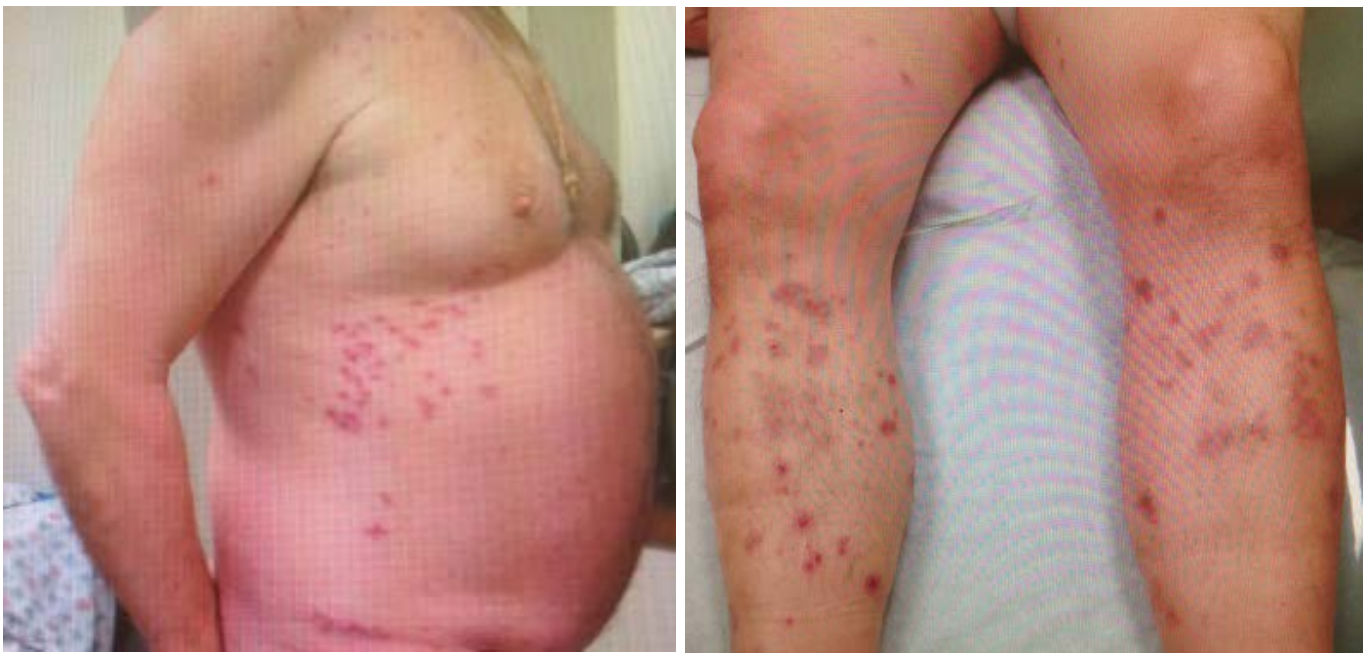History: A 69-year-old man presented to the Skin and Cancer Unit for evaluation of a generalized eruption of red-to-purple, mildly pruritic, non-tender papules and nodules, which spared his face, palms, and soles. The eruption had been ongoing for five years at the time of his presentation. The lesions were sometimes vesicular or pustular, and exuded a yellow discharge. He denied any systemic symptoms. Other medical problems include asbestosis (without mesothelioma), type II diabetes mellitus, and hypertension. No medications were started or changed before the eruption developed.

Prior to his presentation at the Skin and Cancer Unit, a dermatologist treated the condition with doxycycline, which was used at the onset of the eruption and which helped modestly. He was later treated by other dermatologists with valacyclovir, topical glucocorticoids, and ketoconazole, none of which helped.

Physical examination: In a widespread distribution on the trunk and extremities with sparing of the head, neck, palms, soles, and genitals, crops of erythematous-to-violaceous papules, pustules, and nodules were present. Scattered excoriations were noted. A few crusted lesions were present on the trunk, with occasional vesicles on erythematous bases.

Laboratory data: A complete blood count and comprehensive metabolic panel were normal. Hepatitis B virus surface antigen, surface antibody, and core antibody; hepatitis C virus antibody; human immunodeficiency virus; and QuantiFERON-TB Gold were negative.

Histopathology: There is a perifollicular, nodular and interstitial, mixed-cell infiltrate of histiocytes with scattered eosinophils and neutrophils. There are foci of histiocytic aggregates surrounding areas of mucin.



Figures 1,2. Erythematous, violaceous papules and nodules

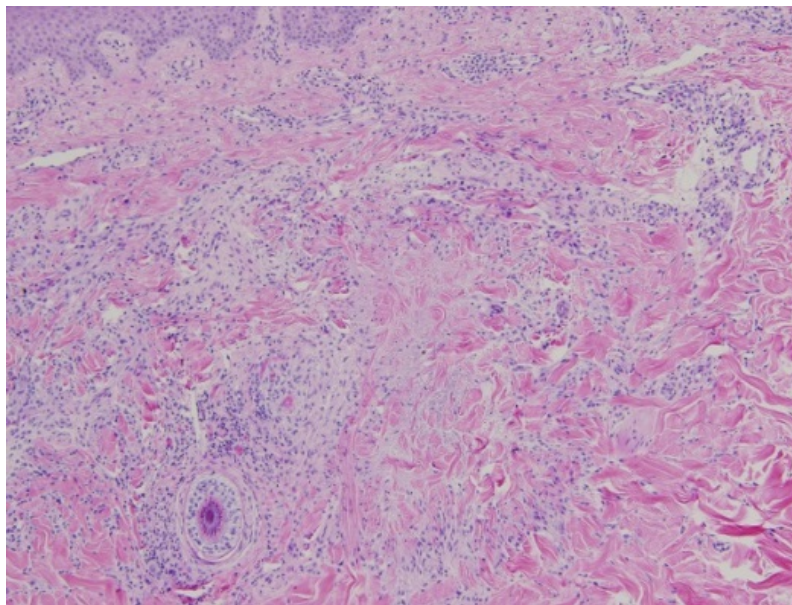


Figure 3. Perifollicular and interstitial mixed infiltrate with histiocytic foci around mucin

Discussion

Diagnosis: Generalized granuloma annulare in a folliculocentric distribution

Comment: Granuloma annulare (GA) is a benign disorder that typically is characterized by small, pink, violaceous, or flesh-colored papules, which frequently coalesce into annular or arcuate plaques. The lesions are sometimes pruritic but frequently are asymptomatic. GA most commonly occurs locally on the extremities of young people and is usually self-limited. However, multiple, less common variants exist, which include generalized, perforating, and subcutaneous GA [1]. No clear etiology of GA has been identified although associations frequently are drawn between GA and diabetes mellitus, trauma, underlying malignant conditions, and hyperlipidemia; none of these associations has been proved definitively. A review of systems, physical examination, and laboratory evaluation are essential, particularly in generalized or recalcitrant GA [2].

Herein we identify a patient with generalized GA, which can occur in up to 15% of patients, with an unusual, folliculocentric distribution. Granuloma annulare presenting as a widespread follicular eruption was first mentioned in the literature in 1915 [3]. However, this report was not substantiated with histopathologic findings. Since 1915, only four subsequent cases of granuloma annulare that occurred in a perifollicular pattern have been reported; three of these cases were rare perforating forms of GA that were characterized by transepidermal elimination of necrobiotic material through the hair follicle unit [4-7].

In our case, the histopathologic features show perifollicular, palisading, granulomatous dermatitis with a predominantly histiocytic infiltrate and scattered neutrophils and eosinophils that surround focal areas of increased mucin deposition. These features are diagnostic of granuloma annulare. Although some lesions clinically appear as follicular pustules, there is no histopathologic evidence of a suppurative folliculitis that might be contributing to the perifollicular inflammation. More likely, the clinical pustules are filled with necrobiotic material that is eliminated via the hair follicle [6].

An interesting concept in generalized GA is the development of lesions as an isotopic response to a previous infection. Thirty-two cases of isotopic GA have been reported; the vast majority of these cases were localized eruptions that developed in healed lesions of zoster [8]. However, cases of generalized isotopic GA also have been reported, both in association with varicella and erythema multiforme [9, 10]. In both cases, the granuloma annulare developed four to six weeks after the inciting infection. The particular T-cell subpopulations that have been identified in GA suggest that a delayed-type hypersensitivity reaction to an unknown antigen is the inciting trigger in the disease [11]. In our case, the patient reported treatment for folliculitis with doxycycline at the beginning of his clinical course. Owing to the follicular distribution of his eruption, it is possible that the generalized GA developed after antigenic changes as a result of a diffuse suppurative folliculitis.

Localized GA typically is treated with high-potency topical glucocorticoids or intralesional glucocorticoids, if at all, because the lesions usually regress and often are asymptomatic. Generalized GA poses a treatment conundrum and requires systemic therapies. The most commonly reported treatments for generalized GA include fumaric acid esters, isotretinoin, biologics, immunosuppressants, narrow-band ultraviolet B phototherapy, and PUVA photochemotherapy. Multiple case reports, small case series, and retrospective analyses exist in the literature, but there are no placebo-controlled studies. For this patient, we recently initiated methotrexate and he plans to start phototherapy at Johns Hopkins, near where he lives [12].

Our patient adds to the small literature bases of cases that describe folliculocentric, generalized granuloma annulare, which perhaps represents a new or under-recognized subset of granuloma annulare.

References

1. Muhlbauer JE. Granuloma annulare. *J Am Acad Dermatol* 1980;3:217
2. Thornsberry LA, English JC 3rd. Etiology, diagnosis, and therapeutic management of granuloma annulare: an update. *Am J Clin Dermatol* 2013;14:279
3. Graham Little EG. Granuloma annulare with a widespread follicular eruption. *Proc R Soc Med* 1916; 9:35
4. Bardach HG. Granuloma annulare with follicular perforation. *Dermatologica* 1982;165:47
5. Dimitrowa J, et al. Follicular lichenoid generalized granuloma annulare. *Z Hautkr* 1984;59:421
6. Vargas-Díez E, et al. Follicular pustulous granuloma annulare. *Br J Dermatol* 1998;138:1075
7. Gamo Villegas R, et al. Pustular generalized perforating granuloma annulare. *Br J Dermatol* 2003;149:866
8. Levy J, et al. Granuloma annulare as an isotopic response to herpes zoster. *J Cutan Med Surg* 2014;18:1
9. Abbas O, Kurban M. Generalized granuloma annulare after varicella infection: Wolf isotopic response? *J Am Acad Dermatol* 2014;71:e80
10. Abraham Z, et al. Disseminated granuloma annulare following erythema multiforme minor. *Australas J Dermatol* 2000;41:238
11. Buechner SA, et al. Identification of T-cell subpopulations in granuloma annulare. *Arch Dermatol* 1983;119:125
12. Thornsberry LA, English JC 3rd. Etiology, diagnosis, and therapeutic management of granuloma annulare: an update. *Am J Clin Dermatol*;14:279