

# Symmetric facial macules in an Asian woman

Meredith Gaufin MD, Ashley DiLorenzo MD, Min Deng MD, Christine DeWitt MD, Michael Cardis MD

Affiliations: Department of Dermatology, Medstar Georgetown, District of Columbia, USA

Corresponding Author: Michael Cardis MD, 5530 Wisconsin Avenue, Suite 730, Chevy Chase, MD 20815, Tel: 301-951-2400, Email: [Michael.a.cardis@medstar.net](mailto:Michael.a.cardis@medstar.net)

## Abstract

Hori nevus, also known as acquired bilateral nevus of Ota-like macules, is a form of dermal melanocytosis found most commonly in women of East Asian heritage. It presents as discrete brown macules on the bilateral cheeks which later coalesce into confluent grey-brown macules and small patches. Herein, we report a classic case of Hori nevus and discuss the histologic findings and differential diagnosis. We also review the proposed pathophysiology, genetic considerations, and treatment options.

*Keywords: dermatopathology, dyspigmentation, genetic disease, mechanisms, nevi, melanocytic, pigmentary disorders*

## Introduction

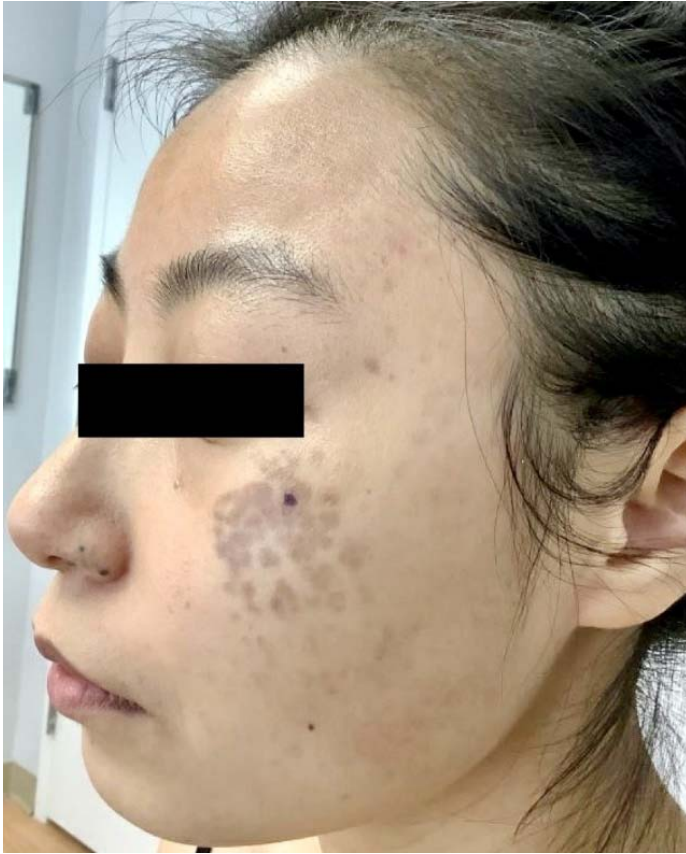Hori nevus (acquired bilateral nevus of Ota-like macules) was first described in 1984 as a new entity distinct from Nevus of Ota [1]. However, some consider Hori nevus to be a "symmetrical type of bilateral nevus of Ota" [2]. It is most common in women with dark skin tones, especially those of East Asian heritage. In 549 published Hori nevus cases, 94.5% of were females [3]. It initially presents as discrete brown macules which later coalesce into confluent grey-brown macules and small patches [4]. Hori nevus is most commonly distributed on the bilateral malar region. Other areas of involvement may include forehead, temple, eyelids, nasal ala, and nasal root [4]. Although it had previously been reported that Hori nevus was not associated with conjunctival involvement, a recent 2017 study

showed that 52% of the 102 cases had scleral pigmentation [3]. Unlike nevus of Ota in which there have been rare reports of glaucoma, concurrent ocular morbidity has not been reported with Hori nevus.

## Case Synopsis

A 34-year-old woman with no past medical history presented to clinic for progressive discoloration of the bilateral cheeks. It was first noticed when she was 15-years-old, shortly after menarche. She denied a family history of similar skin lesions. There were no associated symptoms and no textural cutaneous alterations. Physical examination revealed clusters of monomorphous and fairly well-demarcated brown-blue macules coalescing into small patches symmetrically distributed on the bilateral cheeks (**Figure 1**). The bilateral nasal alae were studded with 2-3mm blue-black round macules and thin dome-shaped papules. She was also noted to have a 2mm dark blue macule on the inferior sclera of the right eye. Upon further questioning she denied any ocular symptoms.

A 2mm punch biopsy was performed on the left medial zygomatic cheek and submitted for histologic review. Representative low and high power images of hematoxylin-eosin stained sections are shown (**Figure 2**). Histology revealed slender, dendritic cells with elongated and pigmented cytoplasm scattered throughout the superficial and mid dermis accompanied by occasional melanophages. The lesional cells were confirmed to be melanocytic in origin as highlighted by a SOX10 immunostain (**Figure 2C**). These findings are that of



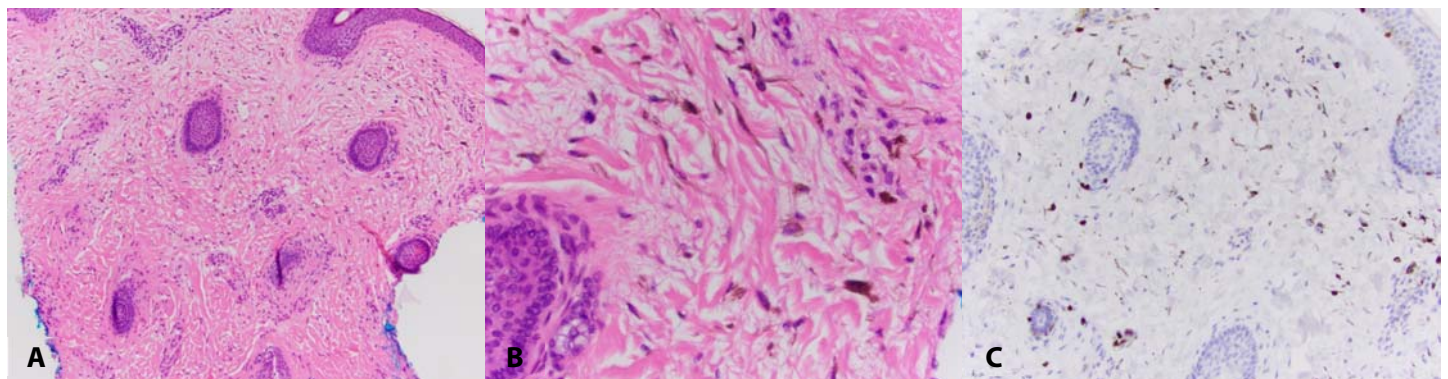
**Figure 1.** Clinical image showing clusters of monomorphous and fairly well-demarcated brown-blue macules coalescing into small patches on the bilateral cheeks.

dermal melanocytosis and given the clinical context are consistent with Hori nevus. The histologic differential diagnosis also includes blue nevus, nevus of Ota/Ito and congenital dermal melanocytosis. Reassurance was provided to the patient and she was referred for laser therapy.

## Case Discussion

The pathogenesis of Hori nevus remains unknown, but proposed mechanisms include: the drop-off of epidermal melanocytes, the migration of hair bulb melanocytes, the reactivation of pre-existing dermal melanocytes, or the manifestation of latent dermal melanocytes in some areas of the face, which may be triggered by dermal inflammation, atrophy, or age-related degeneration of epidermis and dermis [1]. A positive family history has been noted in multiple series [3]. Aggravating or triggering factors include sun exposure, hormonal medications and changes, stress, and trauma [4]. The age of onset varies widely, but it commonly develops after the age of 15, with a reported mean age of 30 [5]. Patients may also display other concurrent pigmentary dyschromias including melasma, lentigines, and/or nevus of Ota [1,3]. Hori nevus can be distinguished from melasma by its well-circumscribed borders and clustered, bilateral distribution on the zygomatic eminence, eyelids, and temples. The brown-blue and/or grey color is also a differentiating feature.

Hori nevus belongs to a spectrum of benign melanocytic proliferations termed dermal melanocytosis which includes congenital dermal melanocytosis of infants, nevus of Ota, and nevus of Ito. Melanoma arising within nevus of Ota and nevus of Ito is very rare (less than 15 reported cases). Although nevus of Ota most commonly occurs in those of Asian and African descent, most cases of primary cutaneous melanoma arising in nevus of Ota



**Figure 2.** Representative low and high-power images of H&E stained sections. There is an infiltrate of slender, dendritic cells with elongated and pigmented cytoplasm scattered throughout the superficial and mid dermis accompanied by melanophages. **A)** 40 $\times$ ; **B)** 400 $\times$ . **C)** SOX10 immunostain, 40 $\times$ .

have occurred in Caucasian individuals [6]. To our knowledge, there are no reports of Hori nevus with malignant transformation. Given the small cohort of primary cutaneous melanoma arising in dermal melanocytosis, molecular studies are very limited. *GNA11* or *GNAQ* mutations have been detected in up to 15% of cases of nevus of Ota and 80-85% of primary uveal melanomas [7]. It is unclear if Hori nevus harbors similar mutations. However, given that it too is a form of dermal melanocytosis, it may share some genetic overlap. Candid conversations should be had with patients regarding the uncertainty of any associated melanoma risk. Clinical changes in dermal melanocytosis, such as development of a papule or nodule involving a previous macule, may be a harbinger of malignant transformation [6].

## References

1. Hori Y, Kawashima M, Oohara K, Kukita A. Acquired, bilateral nevus of Ota-like macules. *J Am Acad Dermatol*. 1984;10:961-964. [PMID: 6736340].
2. Hidano A. Acquired, bilateral naevus of Ota-like macules. *J Am Acad Dermatol* 1985;12:368-9. [PMID: 3973130].
3. Zhang Q, Jiang P, Tan C, Yang G. Clinical profile and triggering factors for acquired, bilateral nevus of Ota-like macules. *Cutaneous and Ocular Toxicology*. 2017;36, 327-330. [PMID: 28122465].
4. Ee HL, Wong HC, Goh CL, Ang P. Characteristics of Hori naevus: a prospective analysis. *Br J Dermatol*. 2006;154:50-53. [PMID: 16403093].
5. Kaur H, Sarma P, Kaur S, et al. Therapeutic options for management of Hori's nevus: A systematic review. *Dermatol Ther*. 2020;33:e13167. [PMID: 31714651].
6. Tse JY, Walls BE, Pomerantz H, Yoon CH, Buchbinder EI, Werchniak AE, Dong F, Lian CG and Granter SR. Melanoma arising in a nevus of Ito: novel genetic mutations and a review of the literature on cutaneous malignant transformation of dermal melanocytosis. *J Cutan Pathol*, 2016;43: 57-63. [PMID: 26260725].
7. Van Raamsdonk CD, Griewank KG, Crosby MB, et al. Mutations in *GNA11* in uveal melanoma. *N Engl J Med*. 2010;363:2191-2199. [PMID: 21083380].

## Conclusion

Hori nevus is a form of dermal melanocytosis which primarily affects the cheeks of young women. As such it can cause significant psychosocial distress, thus treatment should be offered. Pigment-specific lasers, including Q-switched ruby, alexandrite, ER:YAG and Nd:YAG lasers offer the most promising results. The selective photothermolysis caused by the laser may be the reason for its beneficial effect [5]. Cost may be a limitation and patients should be counseled on the possibility of transient post-inflammatory hyperpigmentation with laser therapy [5].

## Potential conflicts of interest

The authors declare no conflicts of interest.