

Case Presentation

Soft-tissue chondroma of the index finger: Clinical, histological and radiological findings in a unique case

Sule Gungor MD, Gulcin Kamali MD, Dilek Canat MD, Gonca Gokdemir MD

Dermatology Online Journal 19 (5): 7

Okmeydani Training and Research Hospital, Istanbul, Turkey

Abstract

A chondroma is a benign, slow-growing cartilaginous tumor. When arising in the medullary cavity of a bone it is referred to as an enchondroma—a very common bone tumor. When occurring in soft tissue without any connection to bone, which is extremely rare, it is known as a soft-tissue chondroma (STC). A 38-year-old female presented with a 2-year history of right index finger pulp swelling in the absence of trauma. On physical examination a firm, immobile nodule, approximately 1 cm in diameter, was observed on the palmar side of the right index finger. The overlying skin was normal. Plain X-ray showed a dense, soft tissue shadow without calcification in the right index finger pulp, but the adjacent bones were intact. MRI showed a 1-cm diameter, well-demarcated lesion with intermediate signal intensity on T1-weighted images and high signal intensity on T2-weighted images. MRI also showed that the tumor had no bony involvement and that the adjacent bones were normal. Histopathological examination of the biopsy specimen showed lobules of mature hyaline cartilage with chondrocytes in the lacunae in the dermal and subdermal layers. Mitotic figures and an increase in cellular atypism were not observed. Based on the histopathological and radiological findings, the mass was thought to be an STC and total excision was performed. Examination of the excised mass confirmed the diagnosis of STC. STC should be considered in patients with a slowly growing, mildly painful cutaneous mass.

Key words: Chondroma, soft-tissue, MRI, chondrocytes, finger, digital mass

Introduction

A chondroma is a benign, slow-growing cartilaginous tumor. When arising in the medullary cavity of a bone it is referred to as an enchondroma—a very common bone tumor. When occurring in soft tissue without any connection to bone, which is extremely rare, it is known as a soft-tissue chondroma (STC) [1,2]. Although patients with an enchondroma usually present to orthopedic clinics, patients with an STC may initially present to a dermatologist with the complaint of a nodule growing below the skin. As such, dermatologists should consider STC in the differential diagnosis of any slowly growing mass.

Case Synopsis

A 38-year-old woman presented with a 2-year history of right index finger pulp swelling in the absence of trauma. The pain became quite severe, especially when applying pressure and cold water, 2 months earlier. She did not report any other systemic disease. On physical examination a firm, immobile nodule, approximately 1 cm in diameter, was observed on the palmar side of the right index finger (Figure 1). The overlying skin was normal. Distal interphalangeal joint motion was not restricted. Plain X-ray showed a dense, soft tissue shadow without calcification in the right index finger pulp; the adjacent bones were intact. MRI showed a 1-cm diameter, well-demarcated lesion with intermediate signal intensity on T1-weighted images and high signal intensity on T2-weighted image. MRI also showed that the tumor had no bony involvement and that the adjacent bones were normal.

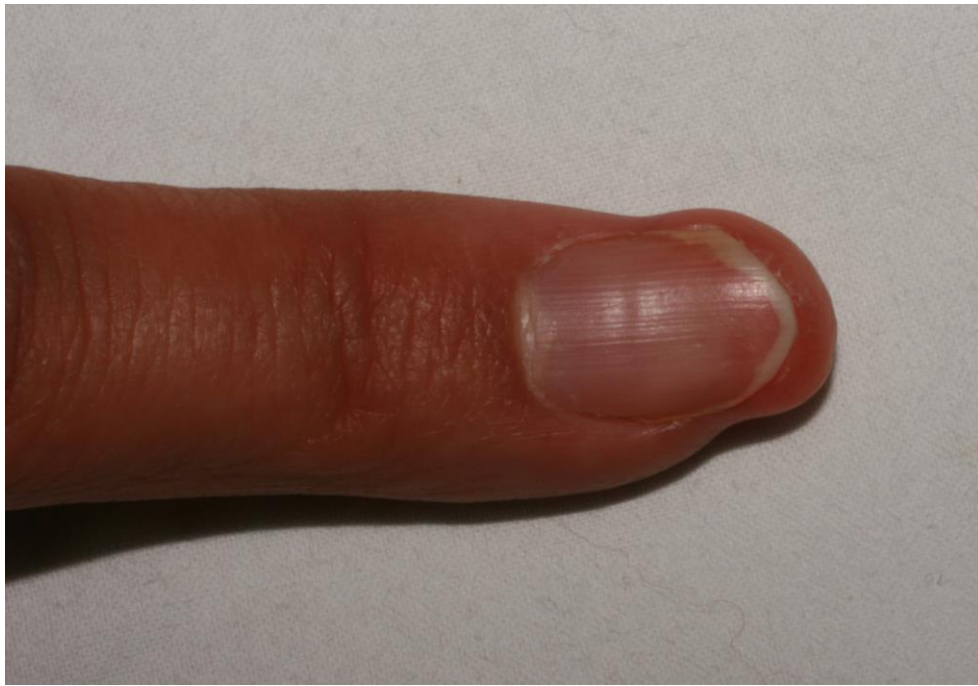

Figure 1. Nodule of right index finger pad

Based on these findings, the mass was considered to be a glomus tumor, neurogenic tumor, or digital aponeurotic fibroma; punch biopsy was performed. Histopathological examination of the biopsy specimen showed lobules of mature hyaline cartilage with chondrocytes in the lacunae in the dermal and subdermal layers. Mitotic figures and an increase in cellular atypism were not observed (Figure 2).

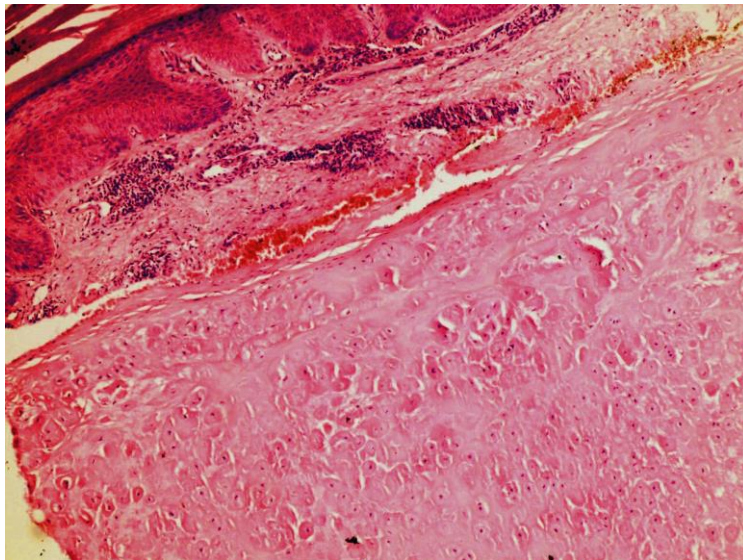


Figure 2. Lobules of mature hyaline cartilage with chondrocytes in the lacunae

Based on the histopathological and radiological findings, the mass was thought to be an STC and total excision was performed. Examination of the excised mass confirmed the diagnosis of STC (Figure 3). As of 20 months post excision, the patient has not had recurrence.

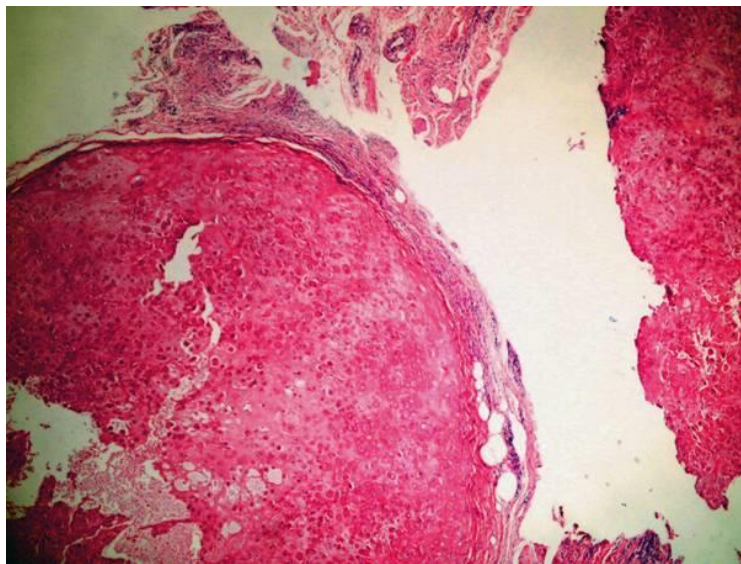


Figure 3. Re-excision histopathology.

Discussion

A Soft tissue chondroma (STC or extra skeletal chondroma) is a rare, soft-tissue tumor [1-4]. It was first reported by Baumüller in 1883 and since then approximately 200 cases have been reported [3]. These tumors occur at almost any age, but most commonly in patients aged 30-60 years [1,-3]. The most common sites of occurrence are the hands and feet [3]. Clinically, the tumor presents as a solitary, slowly growing firm or rubbery well-defined mass [4]. It grows slowly in soft-tissue without any bone involvement and is usually asymptomatic and undetected unless a mass appears. The nodule can be painful or cause nail deformity, depending upon localization [3]. The clinical differential diagnosis of should include glomus tumor, eccrine poroma, epidermal cyst, osteoma cutis, and calcinosis cutis. However, radiological and histological findings are necessary.

Radiographic findings show a well-demarcated, extraosseous soft tissue mass [4]. On plain X-ray calcifications are often seen. However, on rare occasions calcification may not be observed, which can result in missing chondroma as a diagnosis, as in the present case [4]. Owing to their rarity, the literature contains few MRI-based descriptions of soft tissue chondromas. However, most such reports describe intermediate signal intensity on T1-weighted images and high signal intensity on T2-weighted images, as in the presented case [1,5].

On histopathological examination, lobules of mature (chondrocytes) or immature (chondroblasts) hyaline cartilage with varying degrees of cellularity are seen [4,6]. The matrix can be hyaline, fibrous, or fibrohyaline [4]. Histopathologically, the differential diagnosis of STC includes other cartilaginous lesions such as true cutaneous chondromas, some hamartomas (Meckel's cartilage, accessory tragus, bronchogenic cyst, dermoid cyst), calcifying aponeurotic fibroma, skeletal tumors with cartilaginous differentiation (osteochondroma, subungual exostosis, synovial chondromatosis), chondroid syringomas, and cutaneous metastases of chondrosarcoma or chondroblastic osteosarcoma [7-9]. Firstly a cutaneous metastases of a malignant chondroblastic tumor was excluded by the absence of cellular atypism and mitotic figures microscopically, and the absence of rapid growth clinically. Because the lesion was located in both dermal and subdermal layers, the diagnosis of true cutaneous chondroma was excluded. Rarely cartilaginous components can be seen microscopically in hamartomas, but they are often located in the head and neck regions and appear after birth or in childhood. Osteochondroma and subungual exostosis can protrude into the skin and soft tissue causing a palpable mass or nodule; such lesions demonstrate progression to bone, whereas bone structures are intact in STC. In synovial chondromatosis microscopically numerous cartilaginous masses are revealed just beneath the thin lining of the synovial membrane. Chondroid syringoma is composed of small glands and myxoid stroma with variable cartilaginous differentiation, thus the presence of glands are helpful in differential diagnosis [7]. It is difficult to distinguish calcifying aponeurotic fibroma and STC because they both present as slowly growing, painless, soft tissue masses within the hands and feet. Although the majority of the aponeurotic fibroma cases are seen in childhood, they can be seen at any age. The presence of infiltrating fascicles of fibromatosis-like, epithelioid fibroblasts at the periphery of the chondroid metaplasia in aponeurotic fibroma lesions, is a helpful feature to distinguish these from STC [10].

Besides histopathologic examination, immunohistochemistry is useful in the diagnosis of STC, because the tumor cells are positive for S-100 protein and vimentin and negative for epithelial and myoepithelial cell markers [11,12].

Malignant transformation has not been reported in the English-language literature [1-4]. Although a benign tumor, total excision should be performed if there is nail deformation or pain [3]. To prevent local recurrence it is advisable to remove the tumor completely, including the capsular structure and adhesion sites [3]. In conclusion, STC should be considered in patients with a slowly growing, mildly painful cutaneous nodules.

References

1. Wu HH, Chen W, Lee O, Chang CY. Imaging and pathological correlation of soft-tissue chondroma. A serial five-case study and literature review. *J Clin Imaging* 2006; 30: 32. [PMID: 16377482]
2. Suganuma S, Tada K, Tsuchiya H. Giant extraskeletal chondroma of the index finger: A case report. *J Plast Recons Aest Surg* 2011; 64: 1377. [PMID: 21440522]
3. Ishii T, Ikeda M, Oka Y. Subungal extraskeletal chondroma with finger nail deformity: Case report. *J Hand Surg* 2010; 35A:296. [PMID: 20060235]
4. Zlatkin MB, Lander PH, Begin LR, Hadjipavlou A. Soft-tissue chondromas. *AJR* 1985; 144: 1263. [PMID: 3873809]
5. Chandramohan M, Thomas NB, Funk L, Muir LT. MR appearance of mineralized extraskeletal chondroma: a case report and review of literature. *Clin Radiol* 2002; 57:421. [PMID: 12014943]
6. Stockley I, Norris SH. Trigger finger secondary to soft tissue chondroma. *J Hand Surg Br* 1990; 15:468. [PMID: 2269840]
7. Hsueh S, Cruz S. Cartilaginous lesions of the skin and superficial soft tissue. *J Cutan Pathol* 1982; 9: 405. [PMID: 7161422]
8. Salamanca J, Phimes P, Pinedo F, Fuente EG, Espejo GP, Tello FJ. Extraskeletal cutaneous chondroblastic osteosarcoma: a case report. *J Cutan Pathol* 2008; 35: 231. [PMID: 18190451]
9. Özcanlı H, Oruç F, Aydın AT. Bilateral multiple cutaneous hand metastases of chondrosarcoma. *J Eur Acad Dermatol Venereol* 2006; 20: 893. [PMID: 16898930]
10. Murphy BA, Kilpatrick SE, Panella MS, White WL. Extra-acral calcifying aponeurotic fibroma: a distinctive case with 23 year follow-up. *J Cutan Pathol* 1996; 23: 369. [PMID: 8864926]
11. Aslam MB, Haqqani MT. Extraskeletal chondroma of parotid gland. *Histopathology* 2006; 48:465. [PMID: 16487372]
12. Kostpoloulos IS, Daniilidis I, Velegrakis G, Papadimitriou CS. Chondroma of parotid gland. Clinical, histological and immunohistochemical findings in a unique case. *Laryngorhinootologie* 1993;72:261. [PMID: 7686759]