

# Two new cases of aquagenic wrinkling of the palms and literature review on drug interactions

K Bouwman<sup>1</sup>, S Menichino<sup>1</sup>, I Kruithof<sup>2</sup>, AS Aalfs<sup>1</sup>

Affiliations: <sup>1</sup>Department of Dermatology, Martini Hospital, Groningen, The Netherlands, <sup>2</sup> Department of Pathology, Martini Hospital, Groningen, The Netherlands

Corresponding Author: Klasiena Bouwman MD, Department of Dermatology, Martini Hospital, Van Swietenplein 1, PO Box 30033, 9728 NT Groningen, The Netherlands, Email: [bouwman.silke.klasiena@gmail.com](mailto:bouwman.silke.klasiena@gmail.com)

## Abstract

Aquagenic wrinkling of the palms (AWP) is a rare, acquired condition of the skin, defined by transient rapidly developing white to translucent papules on palms and/or soles after brief exposure to water. Aquagenic wrinkling of the palms is associated with cystic fibrosis (CF). Therefore, the diagnosis of AWP can be important. Etiopathogenesis of AWP is still unclear. Treatment is often unsatisfactory and can be very challenging. This article contributes to the knowledge of AWP as we describe two new cases of aquagenic wrinkling of the palms: one patient with familial history of CF and one patient with AWP that was presumed to be induced by use of non-steroidal anti-inflammatory drugs. In addition, we present a review of the literature on drug-induced AWP.

*Keywords: aquagenic wrinkling of the palms, aquagenic keratoderma, aquagenic syringeal acrokeratoderma, transient reactive papulotranslucent acrokeratoderma, acquired aquagenic palmoplantar keratoderma, non-steroidal anti-inflammatory drug, cystic fibrosis*

## Introduction

Aquagenic wrinkling of the palms (AWP) is a rare, acquired condition of the skin, first described in 1996 by English and McCollough and associated with cystic fibrosis (CF), [1,2]. Aquagenic wrinkling of the palms is also referred to as aquagenic syringeal acrokeratoderma, transient reactive papulotranslucent acrokeratoderma, or acquired aquagenic palmoplantar keratoderma [3]. The

condition is defined by transient rapidly developing white-to-translucent papules after brief exposure to water affecting palms and/or soles [4]. Generally, the condition is believed to be aquagenic wrinkling and not true keratoderma, as thickness resolves over a short period of time.

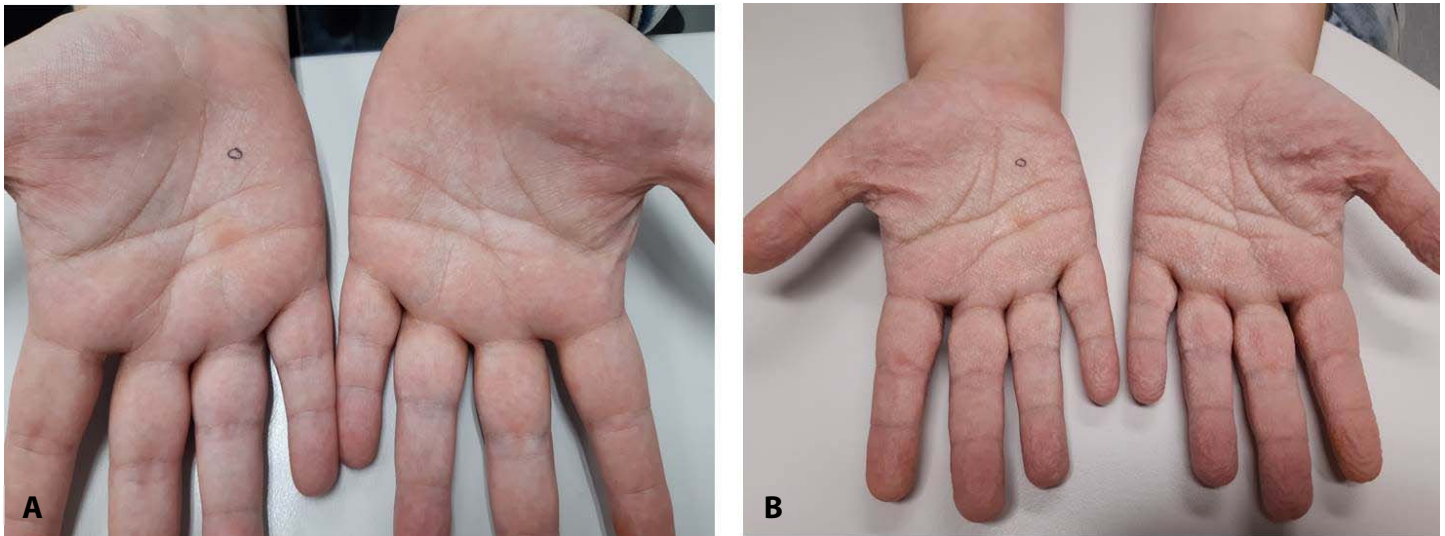
In this article we present two new cases of AWP: one patient with familial history of CF and one patient with AWP which was likely caused by the use of non-steroidal anti-inflammatory drugs. Moreover, cases were collated to give an overview of the current literature on drug-induced AWP.

## Case Synopsis

### Case 1

A 41-year-old woman was referred to our dermatology clinic because of painful swelling of the palms after short contact to water. Her symptoms have only been present for three months and occurred after exposure to water within a few minutes. The symptoms spontaneously faded away within an hour. Our patient was also suffering from palmar hyperhidrosis. She had no other symptoms and used omeprazole for over 5 years, which she started taking after bariatric surgery. No similar complaints were present in her family. However, three maternal nieces and her maternal grandfather were suffering from CF. Nevertheless, both parents of the patient tested negative for being carriers of CF.

Physical examination showed whitish and hyperkeratotic 1-2mm papules of the palms (**Figure**



**Figure 1.** **A)** Before, and **B)** after soaking hands in water for 5 minutes. Note the purple circles indicating the future biopsy site.

**1A).** Following immersion of hands in water for five minutes the papules became macerated and also wrinkling; edema and some small blisters appeared (**Figure 1B**) consistent with a positive “hand-in-the-bucket sign” [5]. Histopathological examination after exposure to water disclosed slight hyperkeratosis of the stratum corneum and minimally dilated sweat gland ostia (**Figure 2**).

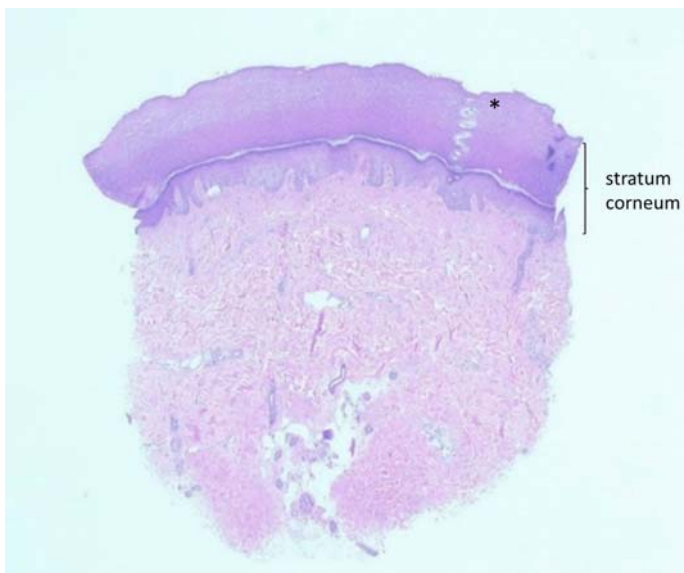
Therapy was initiated with topical lotion containing 18% urea twice a day and salicylic-acid 5% ointment once a day, but did not result in any clinical improvement. Treatment with 20% alcohol solution

of aluminum chloride hexahydrate once daily at night did not provide relief of the symptoms either. Currently, our patient is in consideration undergoing the procedure of endoscopic thoracic sympathectomy (ETS), since this treatment appears to be effective for palmar hyperhidrosis and ETS may be considered to be a permanent treatment option in AWP [6].

### Case 2

A 23-year-old otherwise healthy women was referred with simultaneous symptoms of temporary palmar hyper-wrinkling and edema after water exposure (**Figure 3**). She used ibuprofen regularly for the treatment of headaches, which she started taking concomitant with the appearance of the condition.

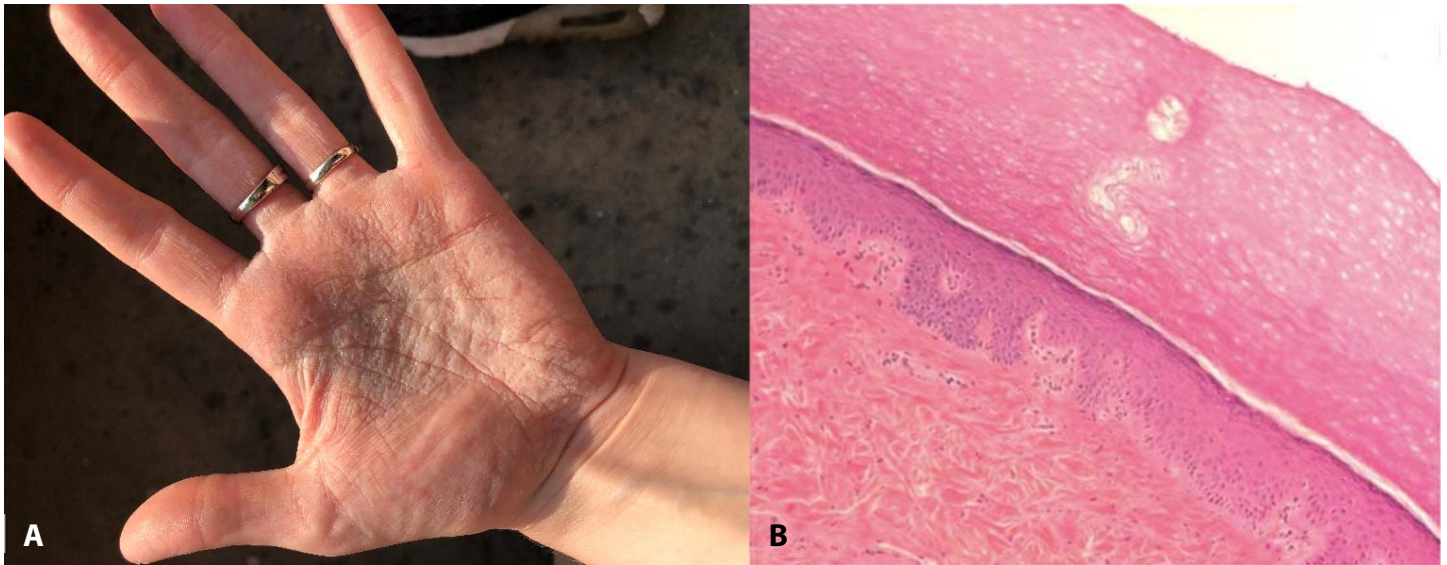
Our patient was advised to stop taking ibuprofen, based on the correlation between the appearance of her symptoms and the initiation of the anti-inflammatory treatment. After one month, palmar symptoms were clinically improved, suggesting that the AWP in this case was secondary to the use of non-steroidal anti-inflammatory drugs.



**Figure 2.** Histopathological examination after soaking hands in water shows dilatation of eccrine acrosyringium (\*) and pale staining of the upper part of the orthohyperkeratotic stratum corneum. Otherwise there are no histological changes. H&E, 25x.

### Case Discussion

Only a limited number of reports have appeared in the literature following the first description of this condition by English and Mc Cullough in 1966 [1]. Aquagenic wrinkling of the palms is clinically characterized by reactive wrinkling and swelling of



**Figure 3. A)** Palmar lesions of patient's hand after water immersion. **B)** Histopathological examination before exposure to water displays a slightly dilated ostium. Once more, pale staining of the stratum corneum can be noted. There are no further histopathological changes. H&E, 100x.

the palms after short contact to water, regardless of water temperature. It is most common in adolescents and young adult women. In some patients, before water immersion whitish and hyperkeratotic papules are already present. Moreover, accentuation of the symptoms after exposure to water is called the "hand-in-the-bucket" sign [5]. In addition, acquired AWP as seen in our cases, must be differentiated from the hereditary form, which is an autosomal dominant-inherited dermatosis associated with fine-textured scalp hair and an atopic constitution [7]. Histopathological examination of acquired AWP may reveal dilated eccrine ostia and hyperkeratosis, congruent to the histological outcomes in our patients [1,8].

There are various hypotheses about the etiopathogenesis of AWP, but the exact cause remains unclear. Since there is a strong association with cystic fibrosis, it has been hypothesized that AWP is related to an increased salt content in the epidermis as seen in CF patients [9]. One hypothesis stated that water-binding capacity of keratins may interfere with the elevated salt content [9]. Others have proposed that abnormal regulation of cell-membrane water channels such as aquaporin 3 may be the cause of AWP [10]. Other pathogenic suggestions proposed a structurally or functionally defective stratum corneum, which may lead to an

increased water absorption that can induce AWP [5,11].

Currently, more than 2000 mutations and polymorphisms of the *cystic fibrosis transmembrane conductance regulator* (CFTR) gene have been demonstrated [12]. Mutations in the CFTR gene are responsible for CF. It is estimated that the risk of being a carrier of the CFTR gene in Europe is 1 in 25 [12]. Given that the carrier status of a mutated CFTR is asymptomatic and that the prevalence of the mutation is high, the diagnosis of AWP may be important. In our first patient, whose parents tested negative for being carriers of the CFTR gene, no further carrier testing was performed. However, presumably not all the genetic mutations that cause CF have been discovered. Thus, our patient could be a carrier of an as yet unidentified CFTR gene mutation.

In the current literature, there are a few cases describing patients with AWP related to non-inflammatory drugs, as presumed in our second patient (**Table 1**). It is implicated that these cyclooxygenase-2 (COX2) inhibitors like ibuprofen change the concentration of electrolytes in sweat. COX2 inhibition in epidermal cells seems to cause increased sodium retention, similar to the mechanism of COX2 inhibition in kidney cells [14,17]. Several other drugs can induce AWP, as has been

**Table 1.** Overview of reported cases of AWP associated with nonsteroidal anti-inflammatory drugs (COX inhibitors).

Case report (year, country)	Age at onset	Sex	Family history of CF (+/-)	Presumed causative drug(s)	Discontinuation of causative drug(s)	Additional therapy	Response to treatment
Bouwman et al. (2020, The Netherlands)	23	F	-	Ibuprofen	Yes	Urea-containing cream	Almost complete
Gualdi et al. [13], (2016, Italy)	32	F	unknown	Combination of indomethacin with caffeine and prochlorperazine dimaleate	Yes	None	Complete
Belli AA et al. [14]. (2016, Turkey)	21	M	unknown	Ibuprofen	Yes	10% salicylic acid and 10% urea cream	Complete
Orzan et al. [15]. (2014, Romania)	28	F	-	Ketorolac	Yes	9% aluminum chloride cream; hand barrier cream	Complete
Gündüz et al. [16], (2013, Turkey)	19	M	unknown	Salazopyrin and indomethacin	Yes	aluminum hydroxychloride 19% cream; topical mometasone furoate ointment 0.1%	Complete
Khuu et al. [17] (2006, USA)	16	F	-	Aspirin	No	None	Complete
Vildósola et al. [18], (2005, Spain)	31	F	unknown	Celecoxib	No	Erythromycin solution; zinc sulfate baths	Almost complete
Carder et al. [19]. (2002, USA)	18	F	unknown	Rofecoxib	Yes	None	Almost complete

Abbreviations: F= female; M= male.

mentioned before in single cases reports. So far, the use of aminoglycoside antibiotics, gabapentin, spironolactone, and a combination of ascorbic acid with clarithromycin and paracetamol have been associated with AWP [20-23]. To our knowledge, as of today the number of reports of drug-induced AWP linked to COX2 inhibitors is larger than any other form of medication related to AWP. This suggests COX inhibition may have an important role in triggering AWP.

Treatment of AWP is often unsatisfactory and is aimed at reducing the hyperkeratosis and the hyperhidrosis, as most patients also report suffering with hyperhidrosis. Topical treatments such as salicylic-acid based products, urea-containing creams, and aluminum chloride hexahydrate are often used to treat AWP with contrasting results [12]. Other therapy options include oral antihistamines

and intracutaneous injections of *Botulinum* toxin A [12,24,25]. In cases of medication-induced AWP, discontinuation of the drug should be considered. Lastly, in severe cases endoscopic thoracic sympathectomy can be considered as a long-term treatment for AWP.

## Conclusion

This report shows two new cases with aquagenic wrinkling of the palms, which is a rare condition characterized by reactive wrinkling and swelling of the palms after short contact to water. Several medications such as non-steroidal anti-inflammatory drugs may induce AWP. Also, AWP is associated with cystic fibrosis. The pathogenesis is not fully understood but is assumed to be related to an increased salt content in the epidermis. Several treatments for AWP have been suggested such as

topical therapies, although results are often suboptimal.

## References

- English JC, McCollough JL. Transient reactive papulotranslucent acrokeratoderma. *J Am Acad Dermatol*. 1996; 34: 686. [PMID: 8601664].
- Megna M, Cantelli M, Martellotta D, Calabrò G, Balato A, Ayala F. Aquagenic wrinkling of the palms: a case report and literature review. *Dermatol Online J*. 2016;22:(9). [PMID: 28329612].
- Syed Z, Wanner M, Ibrahimi OA. Aquagenic wrinkling of the palms: A case report and literature review. *Dermatol Online J*. 2010;16:(7). [PMID: 20673535].
- Schmults C, Sidhu G, Urbanek RW. Aquagenic syringal acrokeratoderma. *Dermatol Online J*. 2003;9:(4). [PMID: 14594600].
- Yan AC, Aasi SZ, Alms WJ, James WD, Heymann WR et al. Aquagenic palmoplantar keratoderma. *J Am Acad Dermatol*. 2001;44:696–9. [PMID: 11260552].
- Wang F, Zhao YK, Luo ZY, Gao Q, Wu W, et al. Aquagenic cutaneous disorders. *J Dtsch Dermatol Ges* 2017;15:602-8. [PMID: 28513988].
- Onwukwe MF, Mihm MC Jr, Toda K. Hereditary papulotranslucent acrokeratoderma: A new variant of familial punctate keratoderma. *Arch Dermatol*. 1973;108:108–10. [PMID: 4716729].
- Ghosh SK, Agarwal M, Ghosh S, Dey AK. Aquagenic Palmar Wrinkling in Two Indian Patients With Special Reference to Its Dermoscopic Pattern. *Dermatol Online J*. 2015;21(6). [PMID: 26158367].
- Elliot RB. Letter: skin wrinkling in cystic fibrosis. *Lancet*. 1974;2:108. [PMID: 4143337].
- Katz KA, Yan AC. Aquagenic wrinkling of the palms in patients with cystic fibrosis homozygous for the delta F508 CFTR mutation. *Arch Dermatol*. 2005;141:621–624. [PMID: 15897385].
- Thomas JM, Durack A, Sterling A, Todd PM, Tomson N. Aquagenic wrinkling of the palms: a diagnostic clue to cystic fibrosis carrier status and non-classic disease. *Lancet*. 2017;389:846. [PMID: 27665964].
- Vankwikelberge E, DeCoster E, Coussens E, Vossart K, Lanssens S. Handlezen voor dermies. *Nederlands tijdschrift voor Dermatologie & Venerologie* 2019;09:49-51.
- Gualdi G, Pavoni L, Monari P, Calzavara-Pinton PG, Manganoni MA. Dermatoscopy of drug-induced aquagenic wrinkling phenomenon. *J Eur Acad Dermatol Venereol*. 2016;30:1211-2. [PMID: 25827615].
- Belli AA, Dogan G. Role of Cyclooxygenase Inhibitors in Aquagenic Syringal Acrokeratoderma. *J Eur Acad Dermatol Venereol*. 2016;30:e220-e221. [PMID: 26833962].
- Orzan OA, Popa LG, Voiculescu V, Manta R, Giurcăneanu C. Non-steroidal anti-inflammatory drug – induced transient reactive papulotranslucent acrokeratoderma. *J Med Life*. 2014;7:75–77. [PMID: 24653762].
- Gündüz O, Ozsaraç KÇ, Ercin, ME. Aquagenic Palmar Wrinkling Induced by Combined Use of Salazopyrin and Indomethacin. *Case Rep Dermatol*. 2013;5:21-6. [PMID: 23466824].
- Khoo PT, Duncan KO, Kwan A, Hoyme HE, Bruckner AL. Unilateral Aquagenic Wrinkling of the Palms Associated With Aspirin Intake. *Arch Dermatol*. 2006;142:1661-2. [PMID: 17179009].
- Vildósola S, Ugalde A. Celecoxib-induced Aquagenic Keratoderma. *Actas Dermosifiliogr*. 2005;96:537-9. [PMID: 16476292].
- Carder KR, Wetson WL. Rofecoxib-induced Instant Aquagenic Wrinkling of the Palms. *Pediatr Dermatol*. 2002;19:353-5. [PMID: 12220285].
- Emiroglu N, Cengiz FP, Su O, Onsun N. Gabapentin-induced Aquagenic Wrinkling of the Palms. *Dermatol Online J*. 2017;23(1). [PMID: 28329484].
- Glatz M, Muellegger RR. Drug-associated aquagenic wrinkling of the palms in an atopic male patient. *BMJ Case Rep*. 2014; bcr2014203929. [PMID: 24903725].
- Uyar B. Aquagenic Syringal Acrokeratoderma. *Indian J Dermatol*. 2014;59:632. [PMID: 25484422].
- Ludgate MW, Patel D, Lamb S. Tobramycin-induced Aquagenic Wrinkling of the Palms in a Patient With Cystic Fibrosis. *Clin Exp Dermatol*. 2009;34:e75-7. [PMID: 19438544].
- Poletti ED, Munoz-Sandoval R. Aquagenic Keratoderma. *N Engl J Med*. 2014; 371:952. [PMID: 25184867].
- Yagerman SE, Leger M, Soter MA. Acquired aquagenic papulotranslucent acrokeratoderma. *Dermatol Online J*. 2016;22:4. [PMID: 28329534].

## Potential conflicts of interest

The authors declare no conflicts of interests