

The use of a sunscreen containing DNA-photolyase in the treatment of patients with field cancerization and multiple actinic keratoses: a case-series

C Navarrete-Dechent MD, M Molgó MD

Affiliations: Melanoma and Skin Cancer Unit, Department of Dermatology, Facultad de Medicina, Pontificia Universidad Católica de Chile, Santiago, Chile.

Corresponding Author: Montserrat Molgó MD, Department of Dermatology, Facultad de Medicina, Pontificia Universidad Católica de Chile, Santiago, Chile, Av. Vicuña Mackenna 4686, Macul, Santiago, Chile. Tel. (56 2) 354 8659. Fax. (56 2) 552 9974, E-mail: montsemolgo@gmail.com

Abstract

Cutaneous field cancerization (CFC) is associated with a high-risk of developing cutaneous squamous cell carcinoma (cSCC). It manifests as actinic keratoses (AK) as one of the few macroscopic alterations in CFC patients. A prospective, single-arm, case-series was performed to evaluate the utility of a novel sunscreen containing DNA-photolyase for treatment of CFC in nine subjects (mean age 70.6 years, male: female ratio 5:4). The cream was applied topically twice daily on CFC/AK areas and patients were followed up for three months, with no other treatments. The primary outcome was the overall response rate (ORR), categorized as complete response (CR, complete resolution of AKs), partial response (PR, reduction in the number of AKs), and no-response (NR, similar/increase in number of AKs). A 100% PR was observed. All subjects displayed at minimum, a 50% reduction in their lesion number and most patients experienced almost CR. Evaluation of AK numbers revealed an absolute count reduction of 76.6% in the number of lesions, with the mean number of lesions reduced from 13.4 to 3.1 ($p < 0.0001$). No adverse events were reported. Patients with CFC may benefit from novel topical applications containing DNA-photolyase, at minimum, as complementary therapy for the management of CFC disease. We propose a new concept called "active photoprotection" because of its dual mechanism involving therapy and protection.

Keywords: actinic keratosis; field cancerization; skin cancer; DNA photolyase; sunscreen; squamous cell carcinoma; ultraviolet radiation

Cutaneous field cancerization (CFC) is associated with high-risk of developing cutaneous squamous cell carcinoma (cSCC) [1]. Actinic keratoses (AK) are one of the few macroscopic alterations in CFC patients [1, 2].

We performed a prospective, single-arm, case-series to evaluate the usefulness of a new topical sunscreen containing DNA-photolyase for the treatment of CFC.

We recruited 9 patients with CFC/multiple AK that were referred to our clinic and were untreated for at least 3 months. Patients were included after signing written informed consent. Exclusion criteria included a current untreated or suspected cSCC or known allergy to any of the components of the cream. All patients were recruited and treated during May-September (mid-autumn/winter in southern hemisphere). This protocol was approved by our Internal Review Board.

The cream (Eryfotona AK-NMSC®, Isdin SA, Barcelona, Spain) was applied twice daily (8:00 AM and 12:00 PM) on CFC/AK areas and patients were followed-up monthly for three months. No other treatments were allowed. Baseline and follow-up pictures were taken.

Our primary outcome was the overall response rate (ORR) and was categorized as follows [3]: complete response (CR, complete resolution of AKs); partial response (PR, reduction in the number of AKs); and no-response (NR, similar/increase in number of AKs). Lesions could be located on face, scalp, hands, and/or forearms. ORR was evaluated by the 2 authors and the images were discussed until consensus was

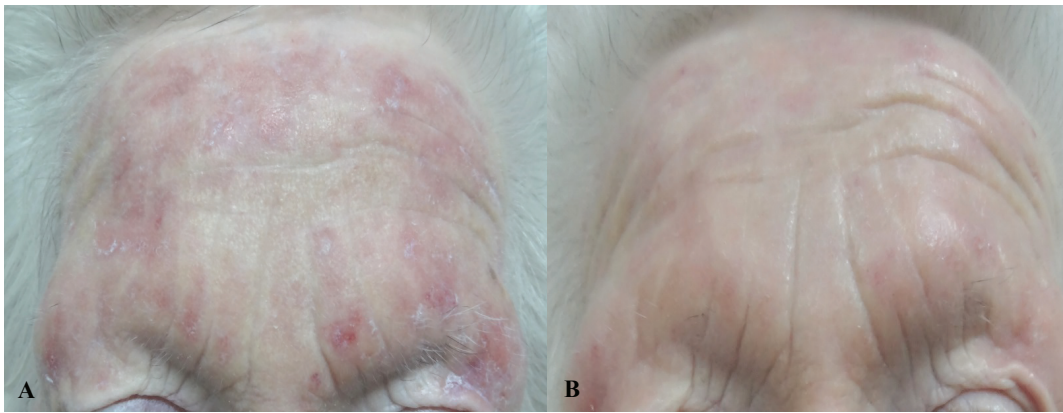


Figure 1. An 82 year-old female. A) Actinic keratosis and cancerization field. Baseline pictures before the onset of treatment. B) Three-month follow-up.

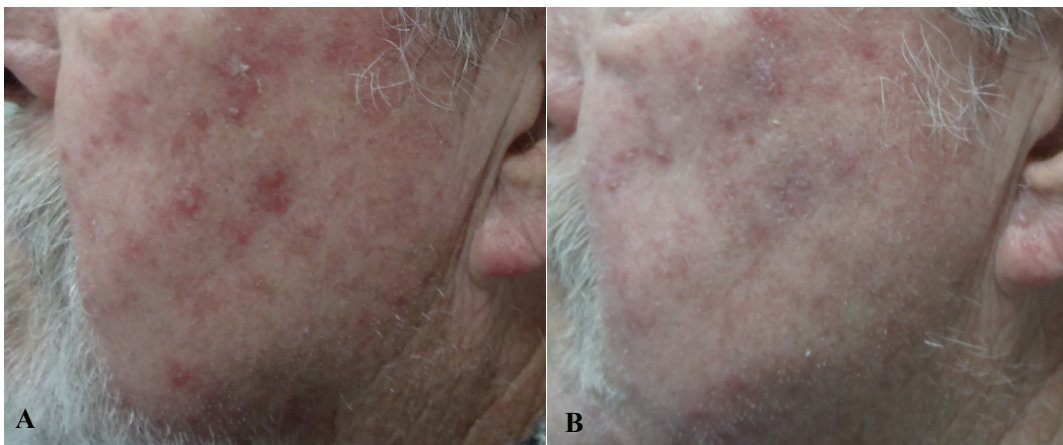


Figure 2. A 67 year-old renal transplant male. A) Actinic keratosis and cancerization field. Baseline. B) Three-month follow-up.

achieved.

Our secondary outcome was the reduction of AKs evaluated as absolute count (reduction in the number of AKs) and as a percentage. Lesions were counted independently by the 2 authors and if there were discordances, we used the mean value between both counts.

Patients' self-reported compliance with treatment was measured as a simple question "Did you use your treatment every day?"

For statistical analyses we used the t-student for paired samples test. Data were analyzed using STATA 10.0 (StataCorp 2007, Stata Statistical Software, College Station, TX). A p-value of < 0.05 was considered statistically significant.

The mean age was 70.6 years old, the male:female ratio was 5:4. Two patients were organ transplant recipients. One patient was lost post follow-up after

his second visit. All other patients completed the 3 months follow-up as per protocol.

There was a 100% PR for all patients. However, all had at least a 50% reduction in their lesion number and most patients had almost CR (Figures 1, 2) with scarce AKs present at the three month follow-up. When evaluating the AK absolute count reduction of lesions we found an overall reduction of 76.6% (range 66.6% to 86.6%) in the number of lesions. The mean number of lesions was reduced from 13.4 (standard deviation 7.9) to 3.1 (standard deviation 2.08); the p-value was <0.0001. No adverse events were reported.

All patients reported daily use of the cream, with excellent adherence.

Chronic exposure to ultraviolet radiation (UVR) is the most relevant factor for the development of AK and subsequent cSCC. UVR causes mutations in nuclear and mitochondrial DNA mainly in the tumor suppressor gene p53. The most common UVR induced DNA damage are the cyclobutane pyrimidine dimers (CPD) and secondarily 6–4 photoproducts [4]. The flavoenzyme DNA photolyase is present in algae and some non-placental mammals, but it is not present in humans [5]. It repairs DNA alterations in the presence of light (300 – 500 nm) by a mechanism called photo-reactivation [4, 6]. Photolyase binds to CPD and repairs them in a reaction triggered by electron transfer from the photo-excited flavin co-factor to the dimer, returning it to its monomeric form [6]. It also restores skin homeostasis by increasing CPI-17 regulating MYTP1 activity [7].

The cream tested herein contains liposomal DNA

photolyase and high UVA and UVB protection filters. Theoretically, photolyase should be used to prevent the formation of new actinic lesions. However, there is some initial data to support the use of this enzyme as a treatment of pre-existing lesions. A recent study used the photolyase in 6 patients with CFC and AK and all showed improvement after at least 6 weeks of treatment [8]. Another study showed reduced number of new lesions (AK, cSCC and basal cell carcinoma) in patients with xeroderma pigmentosum treated for at least one year with this product [4]. Puig et al. showed that using the photolyase twice daily for 4 weeks improved CFC and AK [9], supporting a role for photolyase as a treatment. Moreover, after 30 minutes 40 - 45% of CPDs were removed from treated skin [10].

Herein we showed PR in 9 patients with CFC/AK and an absolute reduction of 76.6% and from 13.4 to 3.1 in the number of lesions; these differences were statistically significant.

In complement with the study by Puig et al. [9], our article adds new insights into the treatment of CFC/AK with DNA-photolyase in a South American cohort population with excellent results. The authors performed a "dissection" of the clinical response, dermoscopic, reflectance confocal microscopy and histopathological characterization of each AK in the former study. However, they did not analyze an overall clinical improvement as their main outcome, which is now reported herein. We believe our study closely resembles daily clinical practice outcomes.

Our main drawback is that we did not include a placebo arm; greatly limiting our conclusions. Interestingly, in the Puig et al. [9] study, they found no improvement in AKs in the 3 patients included in the sunscreen-control group. Although we are aware that sunscreen by itself could promote clinical regression of some AKs, the notable clinical improvement of lesions in our patients could not be explained by sunscreen alone.

Despite these limitations, patients with CFC need field-directed therapies and it seems that sunscreens containing DNA-photolyase may emerge, at least as complementary therapies, in the management of CFC patients. This new concept may be called "active

photoprotection" because of its dual mechanism.

Acknowledgments: To Arturo Borzutzky, MD; for his invaluable help with the statistical analysis in this manuscript.

References

1. Torezan LA, Festa-Neto C. Cutaneous field cancerization: clinical, histopathological and therapeutic aspects. *An Bras Dermatol*. 2013; 88: 775-86. [24173184]
2. Salasche SJ. Epidemiology of actinic keratoses and squamous cell carcinoma. *J Am Acad Dermatol*. 2000; 42: 4-7. [10607349]
3. Lebwohl M, Swanson N, Anderson LL, Melgaard A, Xu Z, Berman B. Ingenol mebutate gel for actinic keratosis. *N Engl J Med*. 2012; 366: 1010-9. [22417254]
4. Giustini S, Miraglia E, Berardesca E, Milani M, Calvieri S. Preventive Long-Term Effects of a Topical Film-Forming Medical Device with Ultra-High UV Protection Filters and DNA Repair Enzyme in Xeroderma Pigmentosum: A Retrospective Study of Eight Cases. *Case Rep Dermatol*. 2014; 6: 222-6. [25408650]
5. Rastogi RP, Richa, Kumar A, Tyagi MB, Sinha RP. Molecular mechanisms of ultraviolet radiation-induced DNA damage and repair. *J Nucleic Acids*. 2010; 2010: 592980. [21209706]
6. Sinha RP, Häder DP. UV-induced DNA damage and repair: a review. *Photochem Photobiol Sci*. 2002; 1: 225-36. [12661961]
7. Puig-Butillé JA, Malvehy J, Potrony M, Trullas C, Garcia-García F, Dopazo J, Puig S. Role of CPI-17 in restoring skin homeostasis in cutaneous field of cancerization: effects of topical application of a film-forming medical device containing photolyase and UV filters. *Exp Dermatol*. 2013; 22: 494-6. [23800065]
8. Puviani M, Barcella A, Milani M. Efficacy of a photolyase-based device in the treatment of cancerization field in patients with actinic keratosis and non-melanoma skin cancer. *G Ital Dermatol Venereol*. 2013; 148: 693-8. [24442053]
9. Puig S, Puig-Butille J, Diaz M, Trullas C, Malvehy J. Field Cancerization Improvement with Topical Application of a Film-Forming Medical Device Containing Photolyase and UV Filters in Patients with Actinic Keratosis, a Pilot Study. *J Clin Exp Dermatol Res*. 2014; 5: 220. [23800065]
10. Yarosh DB. DNA repair, immunosuppression, and skin cancer. *Cutis*. 2004; 74: 10-3. [15603216]