

UC Davis

Dermatology Online Journal

Title

Nivolumab-induced hidradenitis suppurativa: a case report

Permalink

<https://escholarship.org/uc/item/5zb6w7b5>

Journal

Dermatology Online Journal, 30(4)

Authors

Lamberg, Olivia

Pandher, Karan

Matthews, Natalie H

Publication Date

2024

DOI

10.5070/D330464106

Copyright Information

Copyright 2024 by the author(s). This work is made available under the terms of a Creative Commons Attribution-NonCommercial-NoDerivatives License, available at

<https://creativecommons.org/licenses/by-nc-nd/4.0/>

Peer reviewed

Nivolumab-induced hidradenitis suppurativa: a case report

Olivia Lamberg¹ MD, Karan Pandher² MD, Natalie H Matthews^{2,3} MD MPhil

Affiliations: ¹University of Michigan Medical School, Ann Arbor, Michigan, USA, ²Department of Dermatology, Henry Ford Hospital, Detroit, Michigan, USA, ³Department of Medicine, College of Human Medicine, Michigan State University, East Lansing, Michigan, USA

Corresponding Authors: Olivia Lamberg BS, University of Michigan Medical School, 1301 Catherine Street, Ann Arbor, MI 48109, Tel: 269-908-1920, Email: lamberol@med.umich.edu; Natalie H Matthews MD MPhil, Department of Dermatology, Henry Ford Hospital, 3031 West Grand Boulevard, Suite 800, Detroit, MI 48202, Email: nmatthe2@hfhs.org

Abstract

We present a 44-year-old man with metastatic clear cell renal cell cancer undergoing treatment with nivolumab immunotherapy. Three months post-initiation, he developed symmetric recurrent nodules and boils in intertriginous areas, diagnosed as stage II hidradenitis suppurativa of the groin and gluteal cleft. The progressive course, lesion symmetry and location, worsening with nivolumab infusions, and biopsy findings supported the diagnosis. Hidradenitis suppurativa pathogenesis involves immune dysregulation marked by elevated IL17 and neutrophil-dominated inflammation [1]. Immune checkpoint inhibitors, including anti-PD1 agents like nivolumab, are linked to immune-related adverse events related to widespread T cell activation, potentially increasing IL17 signaling associated with HS [2,3]. Clinicians should be aware of, and observant for anti-PD1-induced HS, a rare immune-related adverse event, in patients undergoing immune checkpoint inhibitor therapy.

Keywords: adverse event, antibody, hidradenitis suppurativa, immune dysregulation, immunotherapy, nivolumab, PD1

Introduction

Hidradenitis suppurativa (HS) is a chronic, inflammatory skin disorder characterized by recurrent painful nodules, abscesses, and sinus tunnel formation. Immune dysregulation involving elevated IL17 and neutrophil-dominated

inflammation contribute to HS pathogenesis [1]. Although immune checkpoint inhibitors (ICIs) are a dominant therapy for advanced malignancies, they can cause immune-related adverse events (irAEs). Notably, anti-programmed cell death protein-1 (anti-PD1) therapy has been associated with T cell-mediated adverse events, which may involve IL17 signaling [2,3]. We present a rare case of anti-PD1-induced HS. Clinicians should be aware of this important adverse event when treating patients with anti-PD1 immunotherapy.

Case Synopsis

A 44-year-old, man with metastatic clear cell renal cell cancer was initiated on nivolumab (anti-PD1) immunotherapy. Three months after treatment initiation, he developed recurrent nodules and boils on his gluteal cleft and bilateral inguinal folds (**Figure 1A**). Examination revealed numerous discrete, follicularly-based hypertrophic papulonodules with erythema and drainage in the bilateral inguinal folds and numerous thinner hypertrophic follicularly based papulonodules perianally. A preliminary diagnosis of HS, stage II of groin and gluteal cleft, was made.

He was treated with a combination of topical and oral medications while continuing nivolumab infusions. His treatment plan included topical medications, such as benzoyl peroxide wash, clindamycin solution, and triamcinolone 0.025% ointment to address pruritus, as well as oral doxycycline 100mg twice daily. However, he

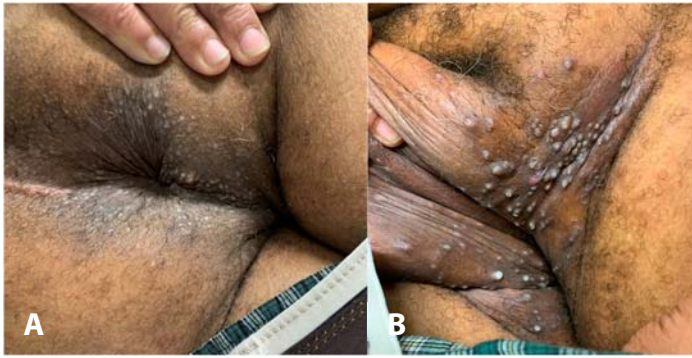

Figure 1. A) Well-healed linear incision and drainage scar on the gluteal cleft, with tender subcutaneous nodules and scattered erythematous follicularly based papules inferior to the scar. **B)** Worsening of indurated plaques and folliculocentric papulonodules in the bilateral inguinal folds during continued anti-PD1 therapy.

exhibited a progressive worsening course with HS flares following each nivolumab infusion. This treatment regimen was continued for five months until the patient worsened and presented with hyperpigmented indurated plaques and folliculocentric papulonodules symmetrically in the inguinal folds (**Figure 1B**). Two 4mm punch biopsies were performed, which demonstrated follicular-cystic dilatation with pseudoepitheliomatous hyperplasia (**Figure 2**). These biopsy findings are consistent with HS and support the diagnosis given the clinical context characterized by a progressive course, symmetric lesions in the intertriginous areas, and worsening with nivolumab infusions. Humira was not initiated owing to concerns about immunosuppression in the context of the patient's

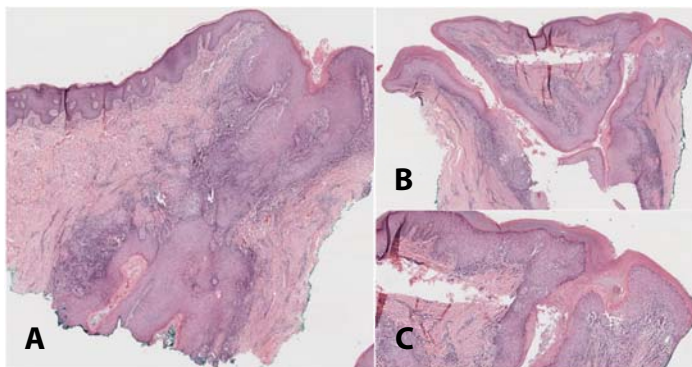


Figure 2. Two biopsy specimens from A) the left suprapubic area, and **B, C)** the left inguinal fold demonstrating follicular-cystic dilatation with marked pseudoepitheliomatous hyperplasia and brisk inflammation with lymphocytes and eosinophils. H&E, **A)** 10x; **B)** 5x; **C)** 20x.

oncological treatment. Instead, the patient was started on clindamycin 300mg twice daily and rifampin 300mg twice daily. At this time, because of stabilization of his malignancy and worsening severity of his HS, nivolumab was discontinued after 11 cycles.

Despite one month of clindamycin and rifampin as above, his HS continued to worsen. He was then started on a 6-week course of intravenous ertapenem and a one-week course of low dose prednisone for his worsening flare. The patient showed clinical improvement with intravenous ertapenem, but his symptoms returned to his previous severity after completing the course.

His antibiotic regimen was then switched to triple therapy of levofloxacin 500mg once daily, rifampin 300mg twice daily, and metronidazole 500mg three times daily. Around this time, his hematology-oncology team also prescribed an increased and extended high dose prednisone course. His triple antibiotic regimen, in combination with topical therapies, was continued for four months with complete resolution. In summary, the patient completed all HS medications approximately 5-6 months after discontinuation of nivolumab, with complete resolution of all HS symptoms 9 months after discontinuation of nivolumab.

Case Discussion

Hidradenitis suppurativa is a chronic inflammatory disease primarily affecting follicles, often in the apocrine gland-bearing areas. Although HS is typically a clinical diagnosis, histopathological findings have been well characterized. These findings include follicular occlusion followed by hyperkeratosis, hyperplasia of the follicular epithelium, perifolliculitis, and ruptured follicles [4]. In cases of unclear clinical presentations, such as our patient, a biopsy may be performed to confirm the diagnosis of HS. The pathogenesis of HS remains incompletely understood, but immune system dysregulation, particularly involving elevated IL17 and neutrophil-dominated inflammation, is believed to play a major role [1,4].

Immune checkpoint inhibitors (ICIs), such as anti-PD1 agents, can lead to irAEs owing to their mechanism causing widespread T cell activation. Cutaneous irAEs are among the most common adverse events associated with ICIs. These most common manifestations of cutaneous irAEs in patients treated with ICIs include maculopapular eruptions (10%-50%), eczematous dermatitis (10-20%), pruritus (10%-30%), lichenoid dermatitis (0.5%-6%), and vitiligo (2%-9%), [1,5,6]. In our patient, the observed latency period of three months between nivolumab initiation and the onset of HS symptoms, along with subsequent improvement after discontinuation, supports the diagnosis of anti-PD1-induced HS. The widespread T cell activation of ICIs is thought to increase activity of the IL17 pathway, thus contributing to HS pathogenesis [1,4].

Our case is the third reported incident, to the best of our knowledge, supporting the possibility of anti-PD1-induced HS. The key features of our case, along with those of the two previously reported instances, are summarized in [Table 1](#) [3,7]. All three patients exhibited no prior history of HS before developing symmetric, recurrent nodules in apocrine gland-bearing areas within 1-3 months of initiating anti-PD1 therapy. Notably, in two of these cases, HS lesions persisted for 9-18 months post anti-PD1 cessation. This prolonged persistence prompts consideration that anti-PD1 therapy might not directly induce hidradenitis suppurativa, but

potentially unmask an underlying predisposition to develop HS.

Although anti-PD1-induced HS is exceedingly rare, it is an important irAE that should be considered in patients receiving ICI therapy [3,7]. This is important to consider in patients, both with and without an existing HS diagnosis as ICIs can exacerbate pre-existing cutaneous autoimmune diseases [5]. The management of ICI-induced irAEs often involves systemic corticosteroids or temporary interruption of ICI therapy, which may reduce efficacy. Thus, early recognition and management of cutaneous irAEs is beneficial to preventing worsening severity that may require systemic corticosteroids or discontinuation of ICIs [2,5].

Conclusion

Clinicians should be aware of the potential for HS as a rare irAE associated with anti-PD1 immunotherapy. Timely recognition and diagnosis of anti-PD1-induced HS are crucial to ensure appropriate management, prevent worsening severity, and minimize disruption to cancer therapy associated with this potential irAE. Collaborative care between oncologists and dermatologists is vital to optimizing treatment strategies [2,5].

Potential conflicts of interest

The authors declare no conflicts of interest.

References

1. Goldberg SR, Strober BE, Payette MJ. Hidradenitis suppurativa: epidemiology, clinical presentation, and pathogenesis. *J Am Acad Dermatol*. 2020;82:1045-1058. [PMID: 31604104].
2. Geisler AN, Phillips GS, Barrios DM, et al. Immune checkpoint inhibitor-related dermatologic adverse events. *J Am Acad Dermatol*. 2020;83:1255-1268. [PMID: 32454097].
3. Maillard A, Pastor D, Merat R. Anti-PD1-induced hidradenitis suppurativa. *Dermatopathology (Basel)*. 2021;8:37-39. [PMID: 33668724].
4. Prens E, Deckers I. Pathophysiology of hidradenitis suppurativa: an update. *J Am Acad Dermatol*. 2015;73:S8-11. [PMID: 26470623].
5. Pach J, Leventhal JS. Cutaneous immune-related adverse events secondary to immune checkpoint inhibitors and their management. *Crit Rev Immunol*. 2022;42:1-20. [PMID: 37022356].
6. Quach HT, Johnson DB, LeBoeuf NR, Zwerner JP, Dewan AK. Cutaneous adverse events caused by immune checkpoint inhibitors. *J Am Acad Dermatol*. 2021;85:956-966. [PMID: 34332798].
7. Ayoubi N, Gerhardt CA, Hennessy K, et al. 33911 hidradenitis suppurativa secondary to nivolumab. *J Am Acad Dermatol*. 2022;87:Supplement. [DOI: 10.1016/j.jaad.2022.06.716].

Table 1. Overview of anti-PD1-associated hidradenitis suppurativa cases.

Case	Key features	Onset during anti-PD-1 treatment	Persistence post-discontinuation	Predisposing factors
Our patient; Lamberg O, Pandher K, Matthews NM	Symmetric recurrent nodules and boils in intertriginous areas	Yes; lesions onset three months after treatment initiation	Yes; lesions completely cleared 9 months after nivolumab cessation	Former smoker (17-pack years) History of hypertension No history of obesity or diabetes No personal/family history of hidradenitis suppurativa
Maillard A, Pastor D, Merat R [3]	Palpable nodules and aseptic abscess in the bilateral axillary folds and groin Spontaneous clearance or drainage of the majority of lesions; however, new flares occurred on a weekly basis	Yes; lesions onset three months after treatment initiation	Yes; lesions completely cleared 18 months after nivolumab cessation	Obese (BMI of 31.9kg/m ²) No smoking history No personal/family history of hidradenitis suppurativa No other medical conditions associated with metabolic syndrome
Ayoubi N, Gerhardt CA, Hennessy K et al. [7]	Erythematous plaques, inflamed nodules and draining sinus tracts in the bilateral inguinal folds	Yes; lesions onset one month after treatment initiation	Undetermined; the patient remained on anti-PD1 therapy with ongoing lesion flaring at the time of case publication	Not specified in the case publication