

**Letter**

**Bilateral suborbital rash: A dermatologic manifestation of neuropsychiatric disease in a pediatric patient**

**Lana X. Tong BA, Yen Tun Wang MD MBA, David Beynet MD**

**Dermatology Online Journal 20 (5): 18**

**Division of Dermatology, Department of Medicine, David Geffen School of Medicine at the University of California, Los Angeles.**

**Correspondence:**

Lana Tong  
170 Brookline Ave. #1012  
Boston, MA 02215  
(646) 926-7598  
lanatong@mednet.ucla.edu

**Abstract**

A 10-year-old girl presented with a new onset bilateral suborbital rash. Dermatologic examination revealed violaceous, non-tender, well-demarcated patches with an atypical distribution and pigmentation. After further investigation, a diagnosis of Munchausen syndrome was made and the patient was referred to her primary care provider for further management.

**Keywords: Munchausen syndrome, pediatric dermatology, psychiatric, factitious disorders**

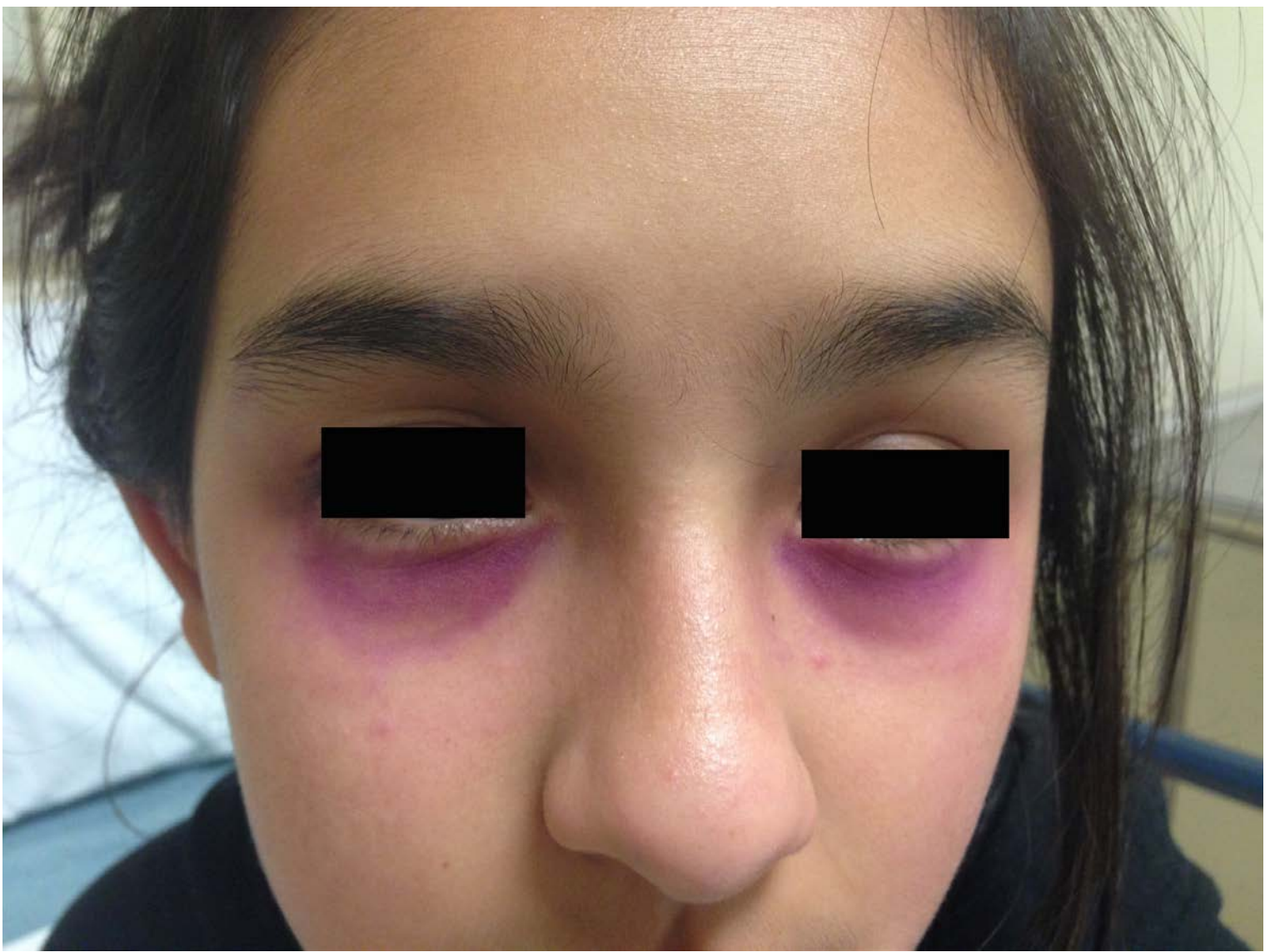
**Introduction**

Munchausen syndrome (MS) is a psychiatric condition characterized by a history of numerous hospital visits or admissions (possibly in different cities), pathological lying, and feigned symptoms of illness, which may be combined with extensive medical knowledge [1]. Diagnosis in pediatric patients can be especially challenging because of fear of overlooking an organic disease and difficulty in determining patient motives or intent.

**Clinical Synopsis**

A 10-year-old girl presented to the emergency department with a 12-hour history of a bilateral suborbital rash. The patient stated that she noticed the rash as soon as she awakened that morning and had not tried any methods to relieve the rash. The eruption had not changed since onset and was not associated with pruritis, fever, recent illness, blisters, or any other systemic symptoms. Her past medical history and family history were unremarkable, although she had frequently visited the emergency room in the past for headaches. She denied any usage of medications or illicit drugs.

Physical exam revealed violaceous, nontender, well-demarcated patches localized to the inferior periorbital skin bilaterally (Figure 1). Her eyelid margin and conjunctiva were unaffected. Extraocular movements were normal and no discharge was observed. Her pupils were equal, round, and reactive to light. Her vital signs were normal. A dermatology consult was requested at this time. The differential diagnoses included ecchymoses, connective tissue disease, and amyloidosis. After further discussion, given the unusual distribution and color of the rash, alcohol wipes were applied to the area of violaceous color, which were easily removed. The patient subsequently admitted to coloring the lesions herself with a purple marker. She had no prior psychiatric history and it is unknown if the patient's relatives were aware of her behavior or had assisted the patient. The patient was referred for follow up with her primary care provider.



**Figure 1.** Violaceous, nontender, well-demarcated patches localized to the inferior periorbital skin bilaterally

## Discussion

This is an interesting case of Munchausen syndrome, which was first described by Asher et al. in 1951[2] and is one of the most extreme forms of factitious disorders (FD). These are a group of psychiatric illnesses defined by the intentional production of illnesses secondary to a desire to assume the patient role [3]. Motives for this behavior may be unclear. Malingering is differentiated from Munchausen by the difference in the patient's ultimate goal, which in malingering is to obtain an external reward rather than medical attention.

Pediatric literature has often focused on Munchausen syndrome by proxy, in which a caretaker induces symptoms in a child in order to fulfill the caretaker's psychological needs; it is considered a form of child abuse. The diagnoses of MS and other factitious disorders are often neglected in children, as providers are more reluctant to suspect children of fabricating their symptoms, especially owing to the difficulty of determining motivation and intent [4]. There is little data on factitious disorder in children, although a retrospective survey conducted by Ehrlich et al. found that the incidence of factitious disorder in children (0.7%) was similar to that in adults (1.3%) [5]. It is thought that factitious disorder first presents at an early age, yet only a few cases of MS in children have been reported in the literature [6, 7]. Diagnosis can often be difficult, but should be suspected when a patient presents with an inconsistent history or symptoms. Social stressors and psychiatric history, both personal and familial, should be investigated. It is important to consider factitious disorders in the differential diagnosis, particularly because early detection is crucial in order to avoid subjecting patients to the burden of unnecessary tests and to reduce the health care costs incurred by unneeded treatment. The secondary goal is to institute a therapeutic approach, which should involve the patient's primary care provider as well as a psychiatrist.

Dermatologists should be prepared to be at the forefront of detecting Munchausen syndrome and other factitious disorders because many of the manifestations of these conditions are on the skin. The specialized training received allows the dermatologist to look

for clues that might reveal the origin of cutaneous findings, including angulated erosions, draining dermal nodules, and atypically-located eruptions.

## References

1. Turner J, Reid S. Munchausen's syndrome. *Lancet*. 2002;359(9303):346-9. [PMID:11830219]
2. Asher R. Munchausen's syndrome. *Lancet*. 1951;1(6650):339-41. [PMID:14805062]
3. Feldman MD, Hamilton JC, Deemer H. Factitious disorder; in somatoform and factitious disorders. In: Philipps KA, ed. *Review of Psychiatry*. Washington, DC: American Psychiatric Press; 2001: 129-159.
4. Ferrara P, Vitelli O, Bottaro G, Gatto A, Liberatore P, Binetti P, Stabile A. Factitious disorders and Munchausen syndrome: the tip of the iceberg. *J Child Health Care*. 2013;17(4):366-74. [PMID:23411659]
5. Ehrlich S, Pfeiffer E, Salbach H, Lenz K, Lehmkuhl U. Factitious disorder in children and adolescents: a retrospective study. *Psychosomatics*. 2008;49(5):392-8. [PMID:18794507]
6. Ozmen S, Ozmen OA, Yilmaz T. Clear otorrhea: a case of Munchausen syndrome in a pediatric patient. *Eur Arch Otorhinolaryngol*. 2008;265(7):837-8. [PMID:18030485]
7. Jaghab K, Skodnek KB, Padder TA. Munchausen's Syndrome and Other Factitious Disorders in Children: Case Series and Literature Review. *Psychiatry (Edgmont)*. 2006;3(3):46-55. [PMID:21103164]