

## Case Report

### Multimodal therapy of idiopathic pyoderma gangrenosum

Victoria Sharon<sup>1</sup>, Barbara Burrall<sup>1</sup>, Forum Patel<sup>1</sup>, Yong He<sup>1</sup>, Thomas Konia<sup>1</sup>, Itzel Bustos Villalobos<sup>1</sup>, Emanuel Maverakis<sup>1,2</sup>

Dermatology Online Journal 20 (6): 6

<sup>1</sup>University of California, Davis, Department of Dermatology

<sup>2</sup>Department of Veteran Affairs Northern California Health Care System

### Correspondence:

Emanuel Maverakis, MD  
Department of Dermatology  
University of California, Davis School of Medicine  
3301 C Street, Suite 1400  
Sacramento, CA 95816  
Telephone (916) 843-7336  
emaverakis@ucdavis.edu

## Abstract

A 13-year old girl was admitted to the University of California Davis Medical Center for evaluation and treatment of cutaneous bullae and ulcerations over her lower extremities that were refractory to antibiotic therapy and incision and drainage. Her disease continued to worsen with the appearance of multiple new bullae and the progression of old ones into deep ulcers with undermined borders. Biopsy revealed a neutrophilic dermatosis and diagnostic work-up was negative for infectious or autoimmune etiologies. Given her clinical presentation, biopsy results, and negative work-up, a diagnosis of pyoderma gangrenosum (PG) was made and she was started on immunosuppressive medications. The patient was started on a multidrug regimen of prednisone and cyclosporine but remission was not achieved until the addition of adalimumab. After the inflammatory component of her disease was under control, wound care measures were maximized to promote ulcer healing. Wound care measures included compression and debridement. Upon complete closure of all wounds she was successfully transitioned to mycophenolate mofetil monotherapy for maintenance therapy. This case emphasizes the need for combinational therapy to successfully treat severe cases of PG, which are often refractory to monotherapy with prednisone or cyclosporine. It also highlights the importance of appropriate wound care to achieve complete ulcer healing.

**Keywords:** Pyoderma gangrenosum, neutrophilic dermatosis, treatment, adalimumab

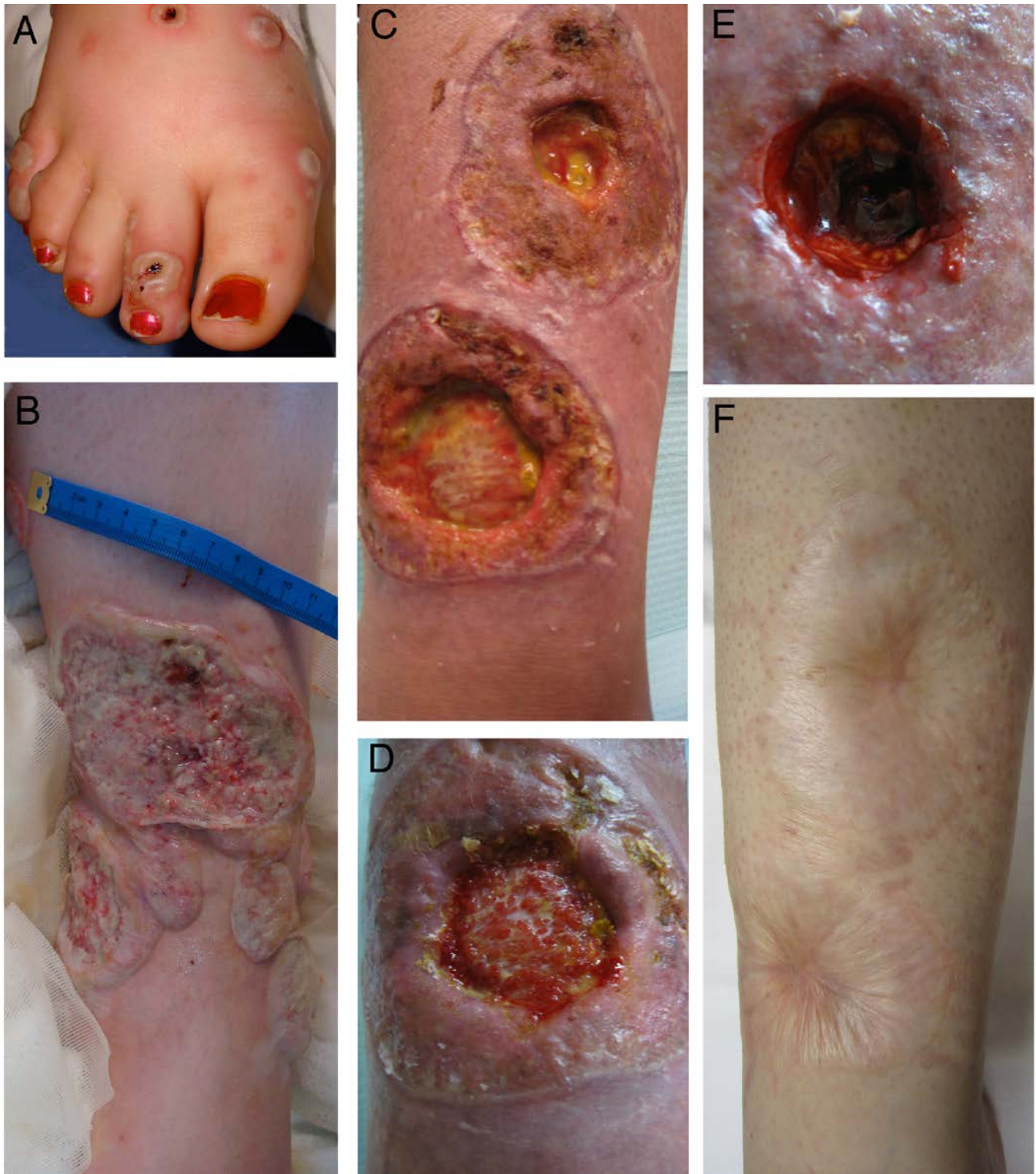## Case synopsis

### Presentation

A previously healthy, 13-year old girl presented to the University of California, Davis Emergency Room with a history of lower extremity cutaneous bullae. Her first bulla was noted five days prior on her right lower extremity. She was initially treated by an outside emergency room for a presumptive abscess with incision and drainage followed by oral amoxicillin/clavulanate and trimethoprim/sulfamethoxazole. Over the next few days, she developed a fever (maximum temperature of 101.4 degrees Fahrenheit), tachycardia (120 beats per minute), arthralgia, and multiple new bullae over her upper and lower extremities. She was subsequently admitted to the UC Davis Medical Center for I.V. antibiotic therapy (clindamycin and vancomycin) and surgical debridement. During the following 48 hours, several of the debrided nodules enlarged in width and depth, forming large putrid ulcerations (Figure 1A and 1B). The patient denied any constitutional symptoms of fatigue, abdominal pain, constipation, emesis, oral ulcers, loose stool, melena, or hematochezia.

## Physical Examination

On physical examination, numerous deeply ulcerated plaques with violaceous undermined borders were observed over the lower extremities bilaterally (Figure 1A and 1B). Beefy red granulation tissue with purulent exudate was visible at the wound beds. There were also multiple purpuric vesicles, bullae, and nodules scattered diffusely over the lower extremities with fewer lesions on her upper extremities. Lymphadenopathy and hepatosplenomegaly were not appreciated.



**Figure 1.** Clinical course of a PG patient treated with multimodal therapy.

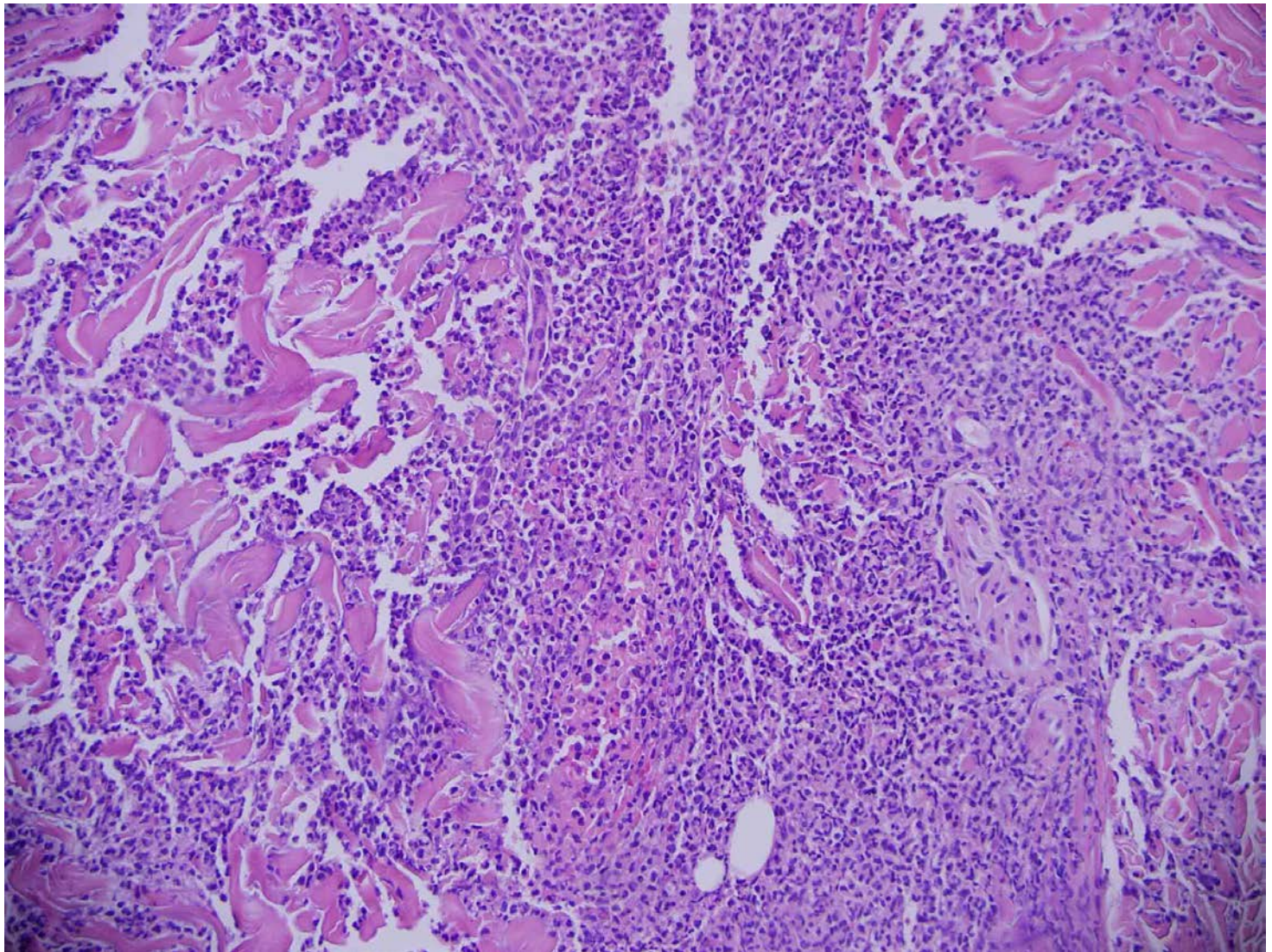
- A.** Approximately one day after presentation - numerous bullae and ulcerations with surrounding erythema on the right foot: Also present are small annular foci of erythema.
- B.** Approximately seven days after admission - numerous coalescing large ulcerations on the distal left lower extremities: These have large undermining borders and presence of excessive inflammatory granulation tissue in the center of the ulcers. At this time point, the patient had bilateral ulcers involving her upper and lower extremities with involvement of her feet.



- C. Approximately 2 months after discharge - right distal lower extremity with chronic ulcerations: At this time point, the patient was on triple therapy with prednisone 80 mg daily, cyclosporine 150 mg twice daily, and adalimumab 40 mg subcutaneously every other week. Note the edema secondary to prednisone, and peri-ulcer scarring. Undermined borders and perilesional erythema are no longer present. Fat and fascia are visible at the base of the ulcers. Some fat has liquefied.
- D. Approximately 2 months after discharge - close-up view of a persistent ulcer: Note the perilesional scarring and rolled border of the ulcer edge. Undermined border and perilesional erythema are not present. Inflammation is no longer present at the ulcer base.
- E. Status-post surgical debridement of ulcers.
- F. Approximately one year after presentation - atrophic cigarette paper-like scars, a characteristic finding in PG: Patient is on maintenance therapy with mycophenolate mofetil 500 mg twice daily.

## Histopathology

Punch biopsies revealed an ulcerating dermatitis with a diffuse dermal neutrophilic infiltrate in the absence of vasculitis (Figure 2A). Fungal, mycobacterial, and bacterial tissue cultures and acid-fast stains were unrevealing for microorganisms. A direct immunofluorescence study was negative.



**Figure 2.** Microscopic examination reveals prominent neutrophils.

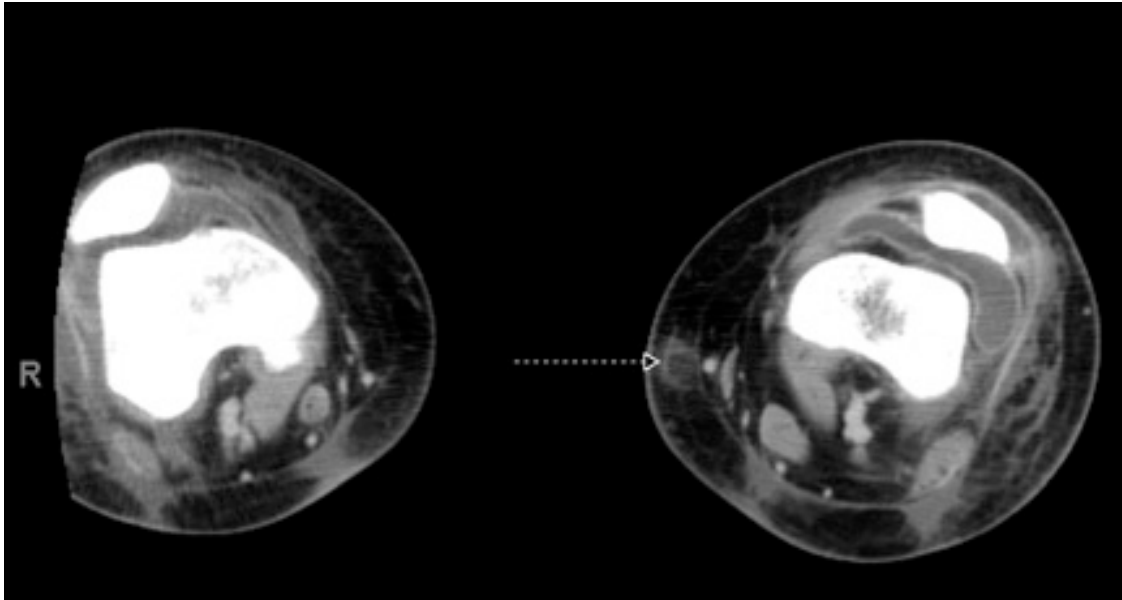
- A. Hematoxylin and eosin staining of a punch biopsy taken from the right forearm, low power at initial presentation
- B. Visible predominance of an ulcerating dermatitis with a diffuse neutrophilic infiltrate dissecting between collagen bundles within the dermis and leukocytoclasia, consistent with a diffuse neutrophilic dermatitis is exhibited. No epidermal alterations or evidence of vasculitis are evident and edema of the papillary dermis is not prominent.

## Laboratory Data

Laboratory studies revealed leukocytosis with a neutrophilic predominance. Hematocrit was initially low at 32% (nl 40-44%). Connective tissue panel revealed normal levels of serum complement C3 and C4, c-ANCA, p-ANCA, and rheumatoid factor. Anti-nuclear, anti-cardiolipin, anti-DNA, anti-phospholipid, anti-Smith/RNP, and anti-SSA/SSB antibodies were also negative. C-reactive protein and erythrocyte sedimentation rate were elevated at 5.5 (nl 0-0.8 mg/dL) and 36 (nl 0-20 mm/hr), respectively. Endoscopy and colonoscopy were unrevealing for signs of inflammatory bowel disease. Tissue biopsies from the esophagus, stomach, and intestine were negative for Crohn disease and ulcerative colitis. Capsule endoscopy was also negative for signs of inflammatory bowel disease.

## Imaging

Helical computed tomography scan of the lower extremities demonstrated low-density nodularities in the subcutaneous tissue in affected areas of cutaneous involvement (Figure 3).



**Figure 3.** Imaging reveals lack of involvement of underlying structures.

Helical computed tomography with contrast of the lower extremities shows several low-density nodularities within the subcutaneous tissue bilaterally, superficial pockets of low-density air bubbles, consistent with soft tissue abscesses, and obvious subcutaneous edema.

## Diagnosis and Management

In the context of a diffuse neutrophilic dermatosis without evidence of infection, autoimmunity, or systemic disease, the patient was started on treatment for idiopathic pyoderma gangrenosum (PG). She was given a combination of prednisone 80 mg (1 mg/kg) daily and cyclosporine 150 mg (2 mg/kg) twice daily. In addition to systemic therapy, the patient was also started on topical steroid therapy with clobetasol 0.05% ointment twice daily, to be applied around the wound edges. Trimethoprim/sulfamethoxazole double strength (160 mg/ 800 mg) three times weekly and alendronate 5 mg daily were started for prophylaxis against *Pneumocystis jiroveci* pneumonia (PCP) and osteoporosis, respectively. On this regimen, the peri-ulcer erythema and undermined borders resolved. The patient was then discharged home with the plan to gradually taper her immunosuppressive regimen of prednisone and cyclosporine as an outpatient. Prednisone was decreased by 10% every 2 weeks and at 40mg per day, the undermining borders surrounding her ulcers reemerged. Adalimumab was subsequently added (80 mg subcutaneous loading dose followed by 40 mg every other week) to her treatment regimen. Following the addition of adalimumab the inflammatory component of her PG appeared to resolve and prednisone and cyclosporine were then slowly tapered off. Although the ulcers' undermined borders and surrounding erythema had resolved on this new regimen, the ulcers failed to heal completely (Figure 1C and 1D).

Initially, non-adherent Vaseline gauze dressings were used to prevent trauma with dressing changes. However, after the inflammation subsided, wet-to-dry dressing changes were initiated for gentle debridement and compression stockings were utilized to reduce the prednisone-induced edema, which was likely impeding wound healing. Unfortunately, even after the patient was successfully titrated off of prednisone and cyclosporine, the ulcers failed to heal. On exam the ulcers lacked undermined borders and peri-ulcer erythema, indicating absence of active disease, but there was significant peri-ulcer scarring. The wound



edges were rolled without sign of re-epithelialization. Because the patient was clinically in remission but wound healing had arrested, ulcers were sharply debrided with a No. 3 curette followed by compression in an attempt to promote re-epithelialization and wound closure, (Figure 1E). Wounds were completely healed approximately 6 months after initiation of therapy (Figure 1F). It is important to note that debridement of active ulcers can actually exacerbate PG and cause worsening of the lesion through pathergy, the development of large ulcerations from mild disturbances or trauma. As a result, PG must be in remission, i.e. resolution of the undermined border, before debridement can be attempted.

After the patient was in remission for several months, she was started on mycophenolate mofetil 500 mg twice daily and adalimumab was tapered off. After over one year without recurrence, all medications were discontinued. Consequently, the patient flared and developed small inflammatory dermal nodules within four months. She was thus restarted on prednisone 40 mg daily and adalimumab 40 mg SQ every other week, which re-induced remission. Following remission, she was transitioned again to mycophenolate mofetil 500 mg twice daily and has since remained disease free on this regimen. Residual hypertrophic scars on the lower extremities were treated with 0.5 cc of intralesional triamcinolone at 40 mg/cc monthly for 4 months.

## Discussion

Pyoderma gangrenosum is a rare neutrophilic dermatosis that presents as painful ulcerations with raised violaceous undermined borders. It is often associated with systemic diseases, most notably inflammatory bowel disease (IBD) and in the setting of malignancy [1]. The etiology of PG is unknown but TNF is believed to play a major role, possibly through its stimulatory action on the neutrophil chemoattractant, IL-8 [2, 3]. Likewise, biologics that inhibit TNF have been shown to be efficacious in the treatment of PG [4].

PG is notoriously difficult to treat, often requiring aggressive immunosuppression to achieve disease remission. Owing to the rarity of the disease, there have been only two randomized controlled trials, prednisone against cyclosporine (currently on-going) and infliximab against placebo [4, 5]. Cyclosporine is a calcineurin inhibitor, which prevents transcription of interleukin-2 (IL-2) and thus reduces effector T-cell function. Infliximab blocks TNF, which in turn may inhibit the production of neutrophil chemotactic factors [6]. A number of other agents, although not formally tested in clinical trials, have been reported to be effective in case series including corticosteroids, tacrolimus, mycophenolate mofetil, methotrexate, thalidomide, and other biologics [7-12]. Oral corticosteroids and cyclosporine have been the most extensively characterized in the literature and are often used as first line therapy for PG. However, some patients with PG do not respond or only partially respond to monotherapy. Combination therapy has emerged as a plausible strategy to manage patients with refractory and/or rapidly progressive PG ulcers. For example, one group reported complete resolution of PG ulcers with a regimen of intravenous cylophosphamide pulse therapy (1000 mg/month), cyclosporine (100 mg/day), and prednisone (30 mg daily tapered to 20 mg daily after 2 months) [13]. Another group reported complete response with a combination of cyclosporine (10 mg/kg), mycophenolate mofetil (2 g daily), and negative pressure dressings [9]. Yet another group successfully treated infliximab and azathioprine-resistant PG with a combination of adalimumab (80 mg SQ weekly), cyclosporine (3 mg/kg), prednisone (20 mg daily), and sulfasalazine (2 g daily) [14].

Our patient developed extensive ulcerations of her bilateral lower extremities after initially receiving incision and drainage for a presumed abscess. In hindsight, the worsening of her condition from a solitary nodule to an eruption of multiple wounds is expected and is typical of the disease course of PG. PG is known to occur at sites of trauma or cutaneous disruption, a process known as pathergy.

In this case report, the presented patient had severe PG and thus we favored a multidrug regimen (prednisone and cyclosporine with the later addition of adalimumab) over monotherapy. She responded well to this regimen and was able to be tapered off all three of the systemic medications. She is currently doing well on mycophenolate mofetil 500 mg twice daily as maintenance therapy. The lowest maintenance dose of mycophenolate mofetil needed to maintain remission varies from patient to patient.

In conclusion, although the literature on combination therapy is scarce, several case reports have supported the use of multimodal therapy in refractory PG ulcers, a finding that has been validated by our experience [15]. Herein, we have presented a patient with rapidly progressive idiopathic PG that responded well to a combination of prednisone, cyclosporine, and adalimumab, without significant toxicity development. Thus, we advocate a multidrug approach in PG patients who develop rapidly progressive disease or have disease that is refractory to monotherapy.

## References

1. Maverakis, E., et al., The etiology of paraneoplastic autoimmunity. *Clin Rev Allergy Immunol*, 2012. 42(2): p. 135-44.
2. Palombella, V., et al., The ubiquitin-proteasome pathway is required for processing the NF-kappa-B1 precursor protein and the activation of NF-kappa-B. *Cell*, 1994. 78: p. 773-785.

3. Siebenlist, U., G. Franzoso, and K. Brown, Structure, regulation, and function of NF-kB. *Annu. Rev. Cell Biol.*, 1995. 10: p. 405-455.
4. Brooklyn, T., et al., Infliximab for the treatment of pyoderma gangrenosum: a randomised, double blind, placebo controlled trial. *Gut* 2006. 55(505-509).
5. Craig, F.F., et al., UK Dermatology Clinical Trials Network's STOP GAP trial (a multicentre trial of prednisolone versus ciclosporin for pyoderma gangrenosum): protocol for a randomised controlled trial. *Trials*, 2012. 13: p. 51.
6. Sivamani, R.K., et al., Biologic therapies in the treatment of psoriasis: a comprehensive evidence-based basic science and clinical review and a practical guide to tuberculosis monitoring. *Clin Rev Allergy Immunol*, 2013. 44(2): p. 121-40.
7. Medeiros, C.C., et al., [Pyoderma gangrenosum in an infant: Case report]. *Dermatol Online J*, 2012. 18(7): p. 6.
8. Baumgart, D.C., B. Wiedenmann, and A.U. Dignass, Successful therapy of refractory pyoderma gangrenosum and periorbital phlegmona with tacrolimus (FK506) in ulcerative colitis. *Inflamm Bowel Dis*, 2004. 10(4): p. 421-4.
9. Gilmour, E. and D. Stewart, Severe recalcitrant pyoderma gangrenosum responding to a combination of mycophenolate mofetil with ciclosporin and complicated by a mononeuritis. *Br J Dermatol*, 2001. 144: p. 397-400.
10. Nousari, H.C., et al., The effectiveness of mycophenolate mofetil in refractory pyoderma gangrenosum. *Arch Dermatol*, 1998. 134(12): p. 1509-11.
11. Teitel, A.D., Treatment of pyoderma gangrenosum with methotrexate. *Cutis*, 1996. 57(5): p. 326-8.
12. Venencie, P.Y. and J.H. Saurat, [Pyoderma gangrenosum in a child. Treatment with thalidomide (author's transl)]. *Ann Pediatr (Paris)*, 1982. 29(1): p. 67-9.
13. Rozin, A., et al., Combined therapy for pyoderma gangrenosum. *Ann Rheum Dis*, 2004. 63: p. 888-889.
14. Fonder, M.A., et al., Adalimumab therapy for recalcitrant pyoderma gangrenosum. *J Burns Wounds*, 2006. 5: p. e8.
15. Goodarzi, H., et al., Effective Strategies for the Management of Pyoderma Gangrenosum. *Adv Wound Care (New Rochelle)*, 2012. 1(5): p. 194-199.