

Hypertrichosis lanuginosa acquisita preceding the diagnosis of breast cancer

A Jibbe¹ MD, N Hoang² BS, N Jibbe³ HSD, T Wang¹ MD

Affiliations: ¹Division of Dermatology, University of Kansas Medical Center, Kansas City, Kansas, USA, ²University of Kansas School of Medicine, Kansas City, Kansas, USA, ³Wichita State University, Wichita, Kansas, USA

Corresponding Author: Ting Wang-Weinman MD, 3901 Rainbow Boulevard, Mail Stop #2025, Kansas City, KS 66160, Tel: 913-588-3840, Email: twang@kumc.edu

Keywords: hypertrichosis, cutaneous paraneoplastic syndrome, malignant down, breast cancer

To the Editor:

Hypertrichosis lanuginosa acquisita (HLA) is a cutaneous paraneoplastic syndrome characterized by a growth of long, thin, and nonpigmented hair covering the face and extending into the trunk and extremities. Malignancies of the lung, colon, and breast are most common with HLA, though other malignancies have been described [1,2]. Because of HLA's insidious and asymptomatic course, diagnosis can take up to two years [1].

Paraneoplastic conditions involving the skin are readily accessible and identifiable. With approximately 70 cases in the literature, clinicians may be unfamiliar with HLA. Nonetheless, recognition and early diagnosis of cancer are crucial in improving overall outcomes. We report a case of HLA to emphasize the importance of screening for HLA to shorten the delay in diagnosis.

Case Synopsis

A 38-year-old woman presented with a 2-year history of facial hair growth. Other than occasionally shaving, the hair was asymptomatic and did not cause much distress. The patient had been diagnosed with stage IA ductal carcinoma of the breast three months prior to presentation. Otherwise, medical history and medication list were unremarkable. She reported a prominent family

history of malignancy, notably breast cancer diagnosed in her great-grandmother, grandmother, great-aunt, and two of her cousins. Physical examination revealed an abundance of thin, soft, nonpigmented hair covering the face (**Figure 1**). Cancer immunohistochemistry revealed 95%

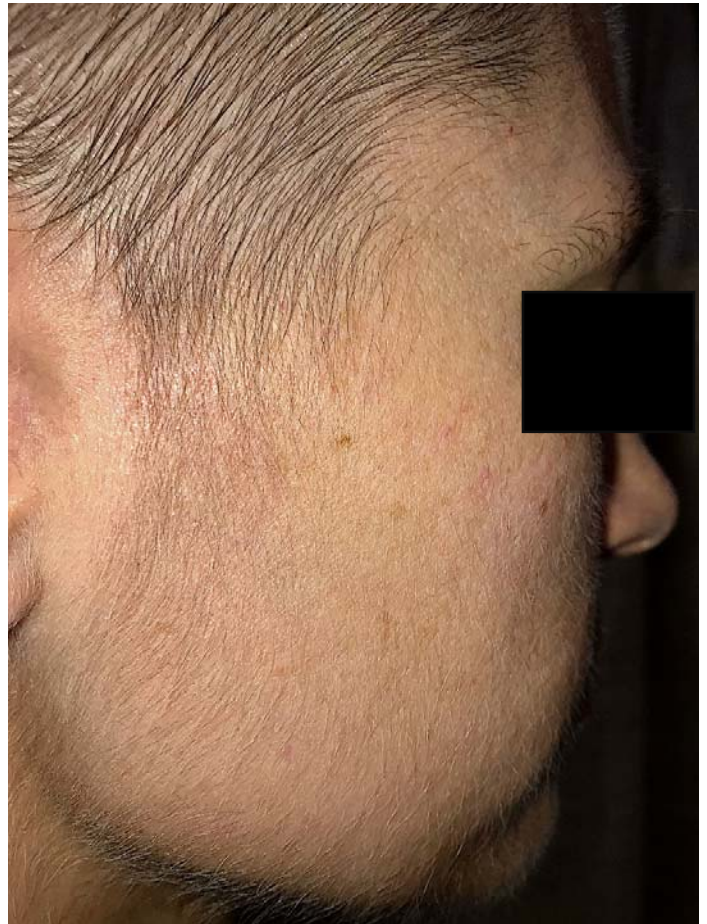


Figure 1. Extensive growth of thin, fine, nonpigmented lanugo-type hair on the face and neck.

positivity for Ki-67 and negativity for HER2/neu, estrogen-receptor, and progesterone-receptor. Genetic testing concluded a variant of uncertain significance in *CHD1* and *XRCC2* genes. Her treatment included mastectomy with adjuvant doxorubicin, cyclophosphamide, and paclitaxel. At her six-month follow-up, she is in complete remission with resolution of her excessive facial hair (**Figure 2**).

Case Discussion

Hypertrichosis lanuginosa acquisita is a cutaneous paraneoplastic syndrome characterized by the rapid growth of lanugo on the face that spreads to the extremities with sparing of the palms and soles [3]. Associated symptoms include diarrhea, lymphadenopathy, taste and smell abnormalities, and trichomegaly [3,4]. Acanthosis nigricans and scleroderma may also develop simultaneously [5].

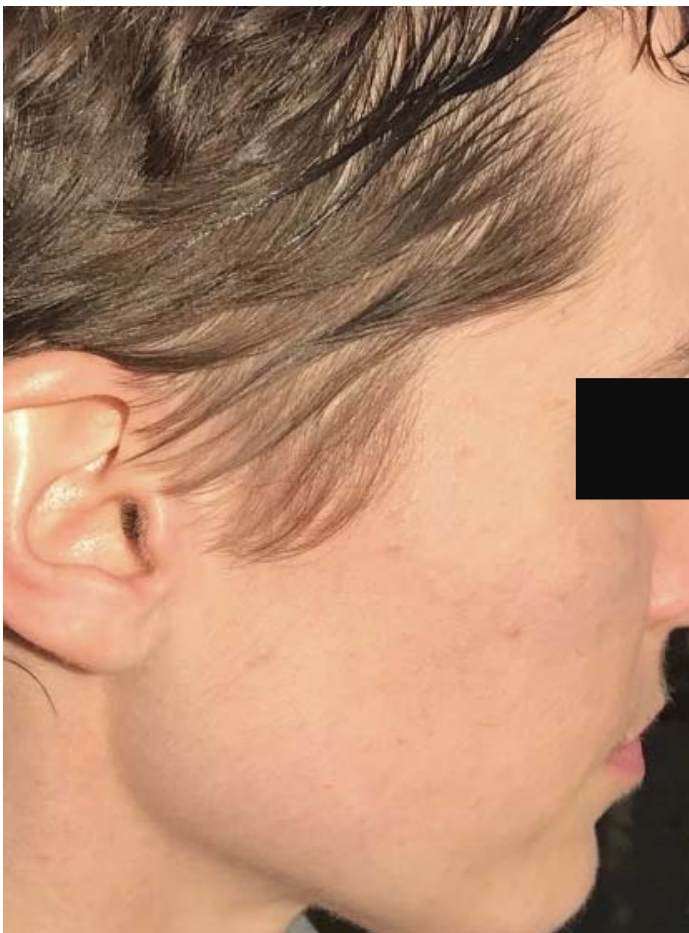

Figure 2. Complete clearance of lanugo hair, photo taken around 6 months after remission.

Removal of the tumor causes regression of lanugo hair. Hypertrichosis lanuginosa acquisita predominantly affects females and is typically diagnosed between 40 and 70 years of age [1].

Hypertrichosis lanuginosa acquisita is recognized as a marker for late malignancy and is associated with a poor prognosis [5]. The appearance of HLA may precede the diagnosis of cancer by two years, with most patients living less than three years after detection [1]. However, our patient's breast cancer was at its early stages despite a two-year history of HLA. Our case raises the question if metastatic or late-stage cancer is intrinsic to HLA, or whether the significant delay in diagnosis confounds its association with a poor prognosis.

Hypertrichosis lanuginosa acquisita should be differentiated from hypertrichosis caused by medications and abnormal endocrine and metabolic function. Hypertrichosis from severe malnutrition may develop lanugo-like hair. Hypertrichosis from other etiologies typically involves vellus and terminal hair. One exception is the appearance of lanugo-like hair in severely malnourished patients. Vellus hairs, commonly referred to as "peach fuzz," are short, thin, and light-colored, whereas terminal hairs are longer, thicker, and pigmented. Hirsutism is a common cause of hypertrichosis and differentiated by the growth of terminal hair on the chest and face. Other disorders include porphyria, brain injury, HIV/AIDS, thyroid disease, and Cushing syndrome. Medication-associated hypertrichosis can occur with cyclosporine, glucocorticoids, penicillamine, interferon, minoxidil, and cetuximab [5,6].

Conclusion

The insidious and asymptomatic course of HLA consequently makes the diagnosis challenging. Patients may consider their hair growth insignificant and not worth mentioning. Clinicians should be familiar with the cutaneous signs of underlying malignancy. A complete history and physical examination are important to recognize HLA to prompt an early comprehensive malignancy workup to identify the tumor. Early recognition of the condition and detection of cancer shortens the delay

in diagnosis, thus potentially improving prognosis and outcomes in these patients.

References

1. Slee PH, van der Waal RI, Schagen van Leeuwen JH, et al. Paraneoplastic hypertrichosis lanuginosa acquisita: uncommon or overlooked? *Br J Dermatol.* 2007;157:1087-1092. [PMID: 17941940].
2. Vulink AJ, ten Bokkel Huinink D. Acquired hypertrichosis lanuginosa: a rare cutaneous paraneoplastic syndrome. *J Clin Oncol.* 2007;25:1625-1626. [PMID: 17443005].
3. Silva JA, Mesquita Kde C, Igreja AC, et al. Paraneoplastic cutaneous manifestations: concepts and updates. *An Bras Dermatol.* 2013;88:9-22. [PMID: 23538999].
4. Thomas I, Schwartz RA. Cutaneous paraneoplastic syndromes: uncommon presentations. *Clin Dermatol.* 2005;23:593-600. [PMID: 16325068].
5. Wyatt JP, Anderson HF, Greer KE, Cordero KM. Acquired hypertrichosis lanuginosa as a presenting sign of metastatic prostate cancer with rapid resolution after treatment. *J Am Acad Dermatol.* 2007;56:S45-47. [PMID: 17224383].
6. Caccavale S, Brancaccio G, Agozzino M, et al. Obligate and facultative paraneoplastic dermatoses: an overview. *Dermatol Pract Concept.* 2018;8:191-197. [PMID: 30116663].

Potential conflicts of interest

The authors declare no conflicts of interests