

Circumscribed palmar hypokeratosis

Nerissa C D'Silva MS, Emily Behrens MD, Ashley Sturgeon MD, Cloyce Stetson MD

Affiliations: Texas Tech University Health Science Center School of Medicine, Lubbock, Texas

Corresponding Author: Nerissa D'Silva, MS, 4707 Autumn Lakes, Missouri City, TX 77459, Email: nerissa.dsilva@ttuhsc.edu

Abstract

Circumscribed palmar hypokeratosis (CPH) is a benign dermatologic condition characterized by local thinning of the stratum corneum. Herein, we present a 52-year-old woman who presented with an asymptomatic pink depressed papule on the right palm. This was treated with clobetasol 0.05% topically twice a day with no improvement.

Keywords: circumscribed palmar hypokeratosis, porokeratosis, Bowen disease, keratinizing disorder

Introduction

Circumscribed palmar hypokeratosis (CPH) is a rare benign dermatosis characterized by a localized reduction of the stratum corneum. First described in 2002, CPH often presents as an isolated atrophic

annular erythematous plaque on the palmar surface, most commonly located at the thenar and hypothenar eminence. Middle aged to elderly women are more commonly affected. Very rarely, malignant transformation has been documented [1].

Case Synopsis

A 52-year-old woman physical therapist presented with a three-month duration of a relatively asymptomatic pink depressed lesion on her right palm (**Figure 1**) without preceding trauma. She noted the border to be more prominent when her hand was wet. She had been treated with clotrimazole 0.1%/betamethasone 0.05% cream for a few weeks with no improvement. Physical examination revealed a 3 mm pink atrophic papule with a well-demarcated border at the right palm mimicking solitary palmar porokeratosis.

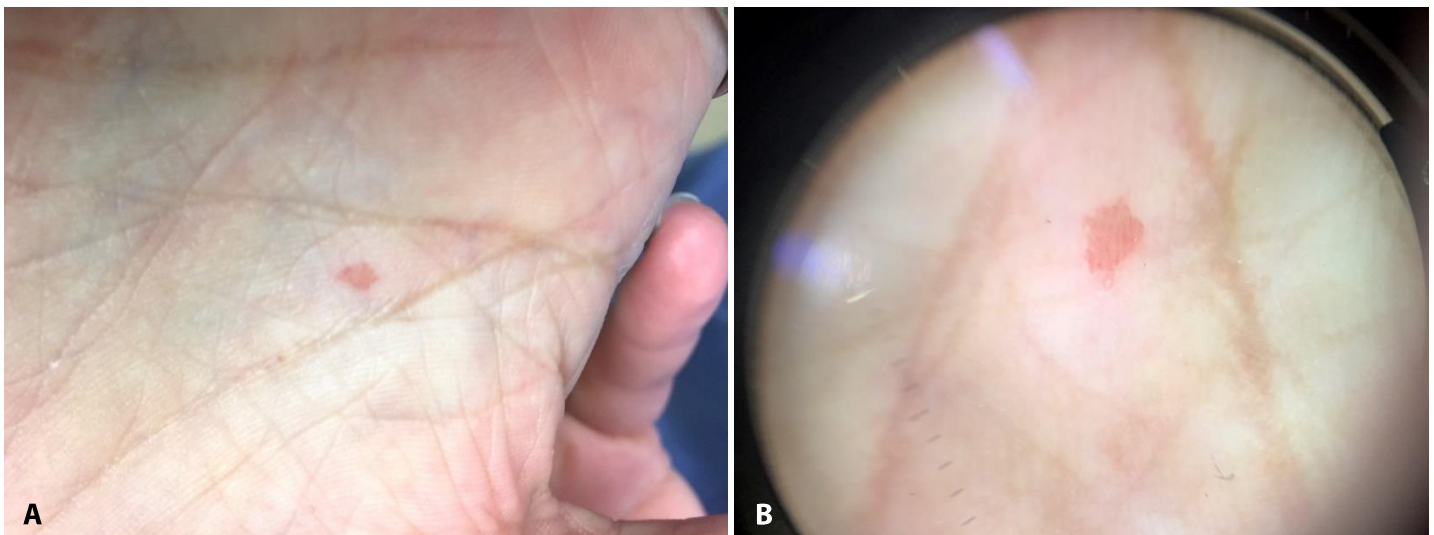


Figure 1. A) 3mm pink atrophic papule on right palm. **B).** Dermatoscopic view of papule on right palm

She was treated with clobetasol 0.05% topical cream twice daily for one month without improvement; the lesion remained unchanged. Shave biopsy of the entire papule was sent for histological examination to rule out atypical presentation of Bowen disease. Histopathological examination displayed a sharply demarcated reduction of thickness within the stratum corneum and a slightly diminished granular layer (**Figure 2**). The Malpighian layer of the epidermis and the dermis appeared unremarkable without increased inflammation. In a focal area of the stratum corneum, bacterial forms were noted. A final diagnosis of circumscribed palmar hypokeratosis was made.

Case Discussion

The pathogenesis of CPH remains unclear, but human papilloma virus has not been identified in lesional skin [1]. Some postulate it as a primary keratinizing disorder, whereas others suggest deregulation in the desquamation process [2, 3]. The histopathological findings are characterized by an abrupt thinning of the stratum corneum from the uninvolved skin to the involved skin [4]. Parakeratosis, atypical keratinocytes, or cornoid lamella are generally absent [1]. The underlying

dermis also appears normal without a specific inflammatory infiltration [5]. High-frequency ultrasonography is a noninvasive alternative to observe the transition at the border between lesional and nonlesional skin [6].

Various topical treatments, including corticosteroids, salicylic acid, and retinoids have been proposed but none showed promising results [5]. In one case, topical calcipotriol resulted in resolution after four years of treatment [2]. Cryotherapy with liquid nitrogen was also beneficial in one case, with no recurrence during follow-up of one year [7].

Conclusion

We present a 52-year-old woman with circumscribed palmar hypokeratosis of the right palm. In many cases, much like our own, the initial clinical presentation resembled that of porokeratosis or Bowen disease. Conservative treatment with ultrapotent topical corticosteroid did not yield success. This case highlights the classic presentation of this rare localized dermatosis affecting only the stratum corneum; it is likely that the incidence of CPH is underestimated. We propose the circumscribed palmar hypokeratosis to be considered in the differential diagnosis for porokeratosis.

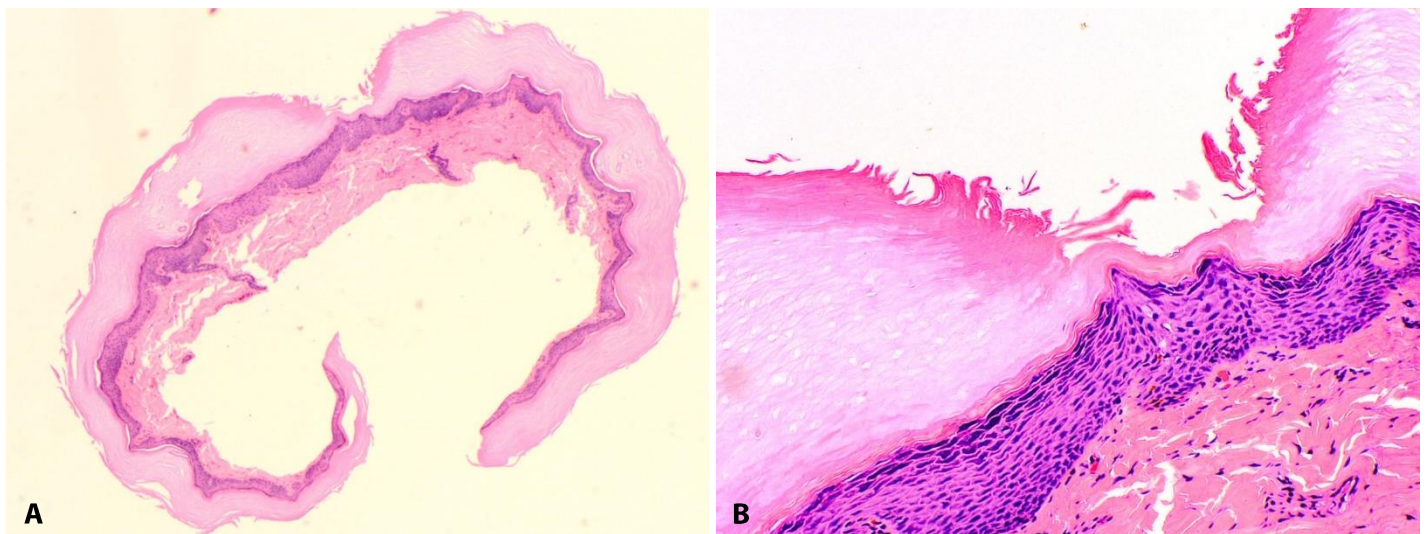


Figure 3. (A). Photomicrograph showing sharply demarcated reduction of thickness within the stratum corneum and a slightly diminished granular layer. H&E, 4x. **(B).** Photomicrograph showing sharply demarcated reduction of thickness within the stratum corneum and a slightly diminished granular layer. H&E, 20x.

References

1. Tosi D, Sala F, Crosti C. Circumscribed Palmar or Plantar Hypokeratosis: Report of an Italian Case. *Indian J. Dermatol. Venereol. Leprol.* 2011;56(2):211-213. [PMID: 21716552].
2. Urbina, F., Misad, C. and González, S. (2005), Circumscribed palmar hypokeratosis: clinical evolution and ultrastructural study after prolonged treatment with topical calcipotriol. *Eur Acad Dermatol Venereol*, 19: 491–494. [PMID: 15987302].
3. Tanioka M, Miyagawa-Hayashino A, Manabe T, Toichi E, Miyachi Y, Takahashi K. Circumscribed palmo-plantar hypokeratosis: a disease with two subtypes. *J Invest Dermatol* 2009; 129: 1045-7. [PMID:18818675].
4. Toyoshima A, Osada S-I, Umabayashi Y, Manabe M. Mutually Exclusive Expression Pattern of Keratin Markers for Differentiation and Proliferation in Circumscribed Palmar Hypokeratosis. *Br. J. Dermatol* 2017. [PMID: 28235237].
5. Perez A, Rutten A, Gold R € et al. Circumscribed palmar or plantar hypokeratosis: a distinctive epidermal malformation of the palms or soles. *J Am Acad Dermatol* 2002; 47: 21–27. [PMID: 12077576].
6. Polańska A, Dańczak-Pazdrowska A, Silny W, et al. Comparison between high-frequency ultrasonography (Dermascan C, version 3) and histopathology in atopic dermatitis. *Skin Res Technol* 2013; 19: 432-7. [PMID: 23521510].
7. Boffa MJ, Degaetano JS. Circumscribed palmar hypokeratosis: Successful treatment with cryotherapy. *J Eur Acad Dermatol Venereol*, 21 (2007), pp. 420-421. [PMID: 17309486].