

Localized pemphigus vulgaris on scalp: an atypical presentation

Alejandro Lapeña-Casado^{1,2}, Javier Alcántara-González^{1,3}, Mar García-García⁴, Cristian Perna-Monroy⁵, Maria-Antonia Concellón-Doñate², Tania-Marusia Capusán^{1,3}

Affiliations: ¹Department of Dermatology, Torrejón University Hospital. Madrid, Spain, ²Department of Dermatology, Lozano Blesa University Clinical Hospital. Zaragoza, Spain, ³Francisco de Vitoria University. Madrid, Spain, ⁴Department of Pathology, Lozano Blesa University Clinical Hospital. Zaragoza, Spain, ⁵Department of Pathology, Torrejón University Hospital. Madrid, Spain

Corresponding Author: Javier Alcántara-González, Department of Dermatology, Torrejón University Hospital, Calle Mateo Inurria sin numero Torrejón de Ardoz, 28850, Madrid, Spain, Email: jalcantarag@hotmail.es

Abstract

We present two middle-aged patients with pruritic, crusted scalp erosions. Skin biopsy showed epidermal acantholysis with IgG and C3 intercellular deposits on direct immunofluorescence, leading to the diagnosis of localized pemphigus vulgaris. Resolution of the lesions without relapse occurred after low doses of oral prednisone and intralesional triamcinolone acetonide.

Keywords: pemphigus, scalp, vulgaris

Introduction

Pemphigus vulgaris is an autoimmune blistering disease of mucosa and skin; it presents a worldwide distribution with an incidence of 0.07-3.2 cases/100,000 population. It is more prevalent among Jewish and Mediterranean patients, except juvenile cases [1]. The presence of IgG autoantibodies against desmoglein 3 (and -1 less frequently) play a primary pathogenic role in inducing the loss of cell adhesion between keratinocytes and subsequent blister formation. Erosions and pain ulcers in oral cavity with posterior extension to skin around the fifth decade is the typical clinical presentation with a chronic course. Nevertheless, exclusively mucosal or cutaneous forms have been described [2]. The frequency of scalp involvement as first clinical manifestation in pemphigus vulgaris is estimated at 9-15% [1,3]. Non-extension of pemphigus involvement to other areas

in a minimum period of 5 months defines the concept of localized pemphigus vulgaris (LPV), [4]. Herein, we report two patients with LPV on scalp.

Case Synopsis

Case 1

A 57-year-old man, without known drug allergies but with a medical history of arterial hypertension and surgically removed pituitary adenoma taking substitutive oral treatment with hydrocortisone, complained of a persistent pruritic scalp lesion start with progressive growth over 6 months. Oral antibiotic treatments had been ineffective. No fever or other symptoms were present. He did not remember any trauma or suspicious animal contact and his family history was not contributory. Furthermore, no new topical products had been used.

On physical examination of the interparietal region, two crusted plaques with alopecia with an erosive base were observed (**Figure 1A**). Trichoscopy of the lesions did show extravasation and polymorphic vessels as main patterns. In addition, bacterial culture and skin biopsy were also performed. There was a *Staphylococcus aureus* overgrowth on the former. Histopathological findings were characteristic of an acantholytic dermatosis with Hailey-Hailey like pattern and, extension to the infundibular epithelium. Some dyskeratotic cells were also noted. IgG and C3 deposits on direct immunofluorescence were demonstrated, affecting

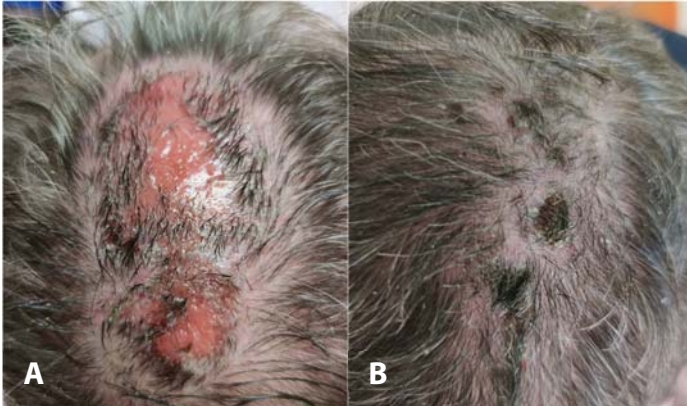


Figure 1. Case 1. **A)** Panoramic view of localized erosive lesions on the scalp after removal of crust. **B)** Follicular regrowth and marked improvement after two months of oral prednisone.

mostly the basal portion of the epidermis (**Figure 2A**). Indirect immunofluorescence and autoimmunity profile were negative (**Figure 2B, C**).

A diagnosis of LPV on the scalp was made and treatment with topical corticosteroids was initiated with partial resolution of scalp lesions. One month later, oral prednisone at a dose of 0.5mg/kg/day was added with full resolution of erosive lesions and follicular regrowth (**Figure 1B**). After 18 months, no sign of relapse was observed.

Case 2

A 56-year-old woman, without known drug allergies or relevant medical history, presented with an alopecic plaque on the scalp for three months that had been treated with oral antibiotic and topical corticosteroids, showing only a slight improvement with the latter.

On physical examination a 4cm, non-infiltrated, erythematous, erosive and crusty, alopecic plaque was observed on the scalp vertex (**Figure 3A**). Fungal culture and skin biopsy were performed. No microbiological growth was obtained and the histopathological biopsy showed epidermal acantholysis (**Figure 4**) and intercellular deposits of IgG and C3 in the epidermis at direct immunofluorescence. Indirect immunofluorescence and autoimmunity profile was negative.

With the diagnosis of LPV on the scalp oral prednisone was prescribed at a dose of one mg/kg/day with a progressive dose reduction over

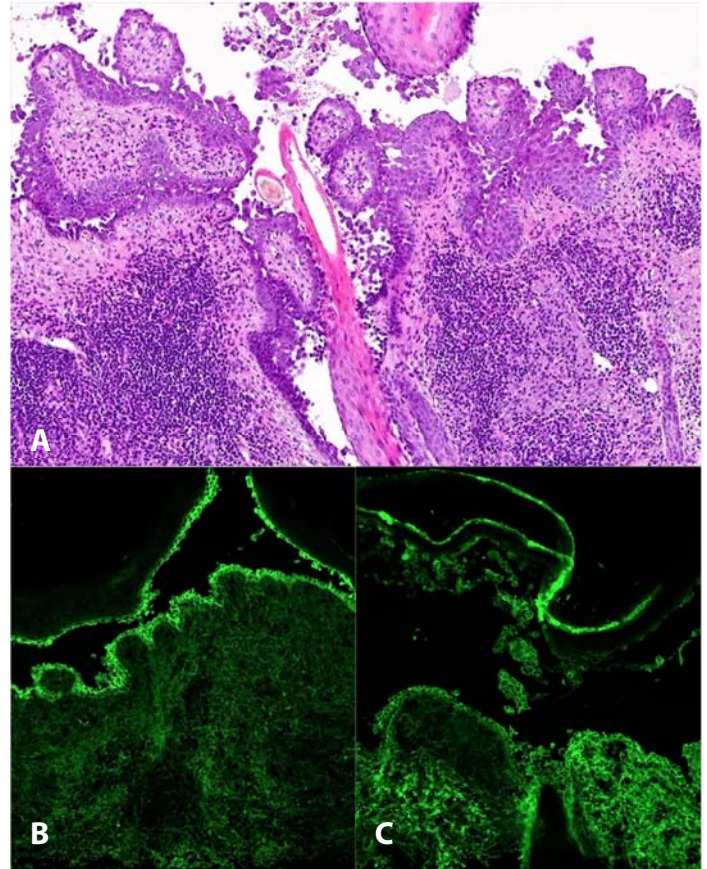


Figure 2. Case 1. **A)** H&E stain. Suprabasal acantholysis with extension to the follicular epithelium, 10x. **B)** Direct immunofluorescence visualization of C3 deposits in intercellular spaces of the epidermis, 10x. **C)** IgG deposits in intercellular spaces of the epidermis, 10x.

two months. The patient had a good response with only a slightly 1cm, erosive area persisting. After triamcinolone acetonide intralesional injection she achieved re-epithelization and follicular regrowth

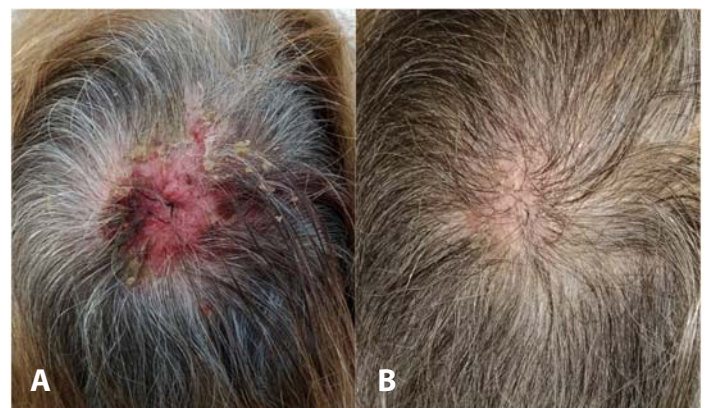


Figure 3. Case 2. **A)** Erosive and crusted plaque on the vertex. **B)** Complete re-epithelization and follicular regrowth oral and intralesional corticosteroid treatment.

(**Figure 3B**). No sign of relapse has been observed after 13 months.

Case Discussion

Scalp lesions may occur during the course of pemphigus vulgaris in up to 16-60% of patients [1,3,5] and in up to 15% of cases it can be the initial manifestation [1,3]. However, isolated scalp presence as a localized variant of pemphigus vulgaris is much rarer. The exact incidence of this situation is unknown, but the study of Zaraa et al. found only four out of 151 cases of pemphigus were classified as localized pemphigus [4]. In cases of LPV the most common involvement is mucosal, with less than 10 cases reported in the literature of exclusive scalp affection [6].

Localized pemphigus vulgaris has been associated with surgical scars (suggesting a Koebner-like phenomenon) and contact pemphigus related to topical chemicals has been described [7,8]. However, ultraviolet radiation could have triggered an acantholytic autoimmune response in our first case because his scalp pemphigus started in spring [9].

In our cases, negative indirect immunofluorescence may support the absence of dissemination of the lesions over the time as being related to an absent or low rate of circulating autoantibodies. Furthermore, singular location at scalp may be explained with excess desmoglein type 3 in this area. It is expressed on the basal and para-basal cell layer of skin and in medulla, outer root sheath, and infundibulum of hair follicles [10].

Histological examination and direct immunofluorescence are necessary for confirming the diagnosis. Recently, direct immunofluorescence of plucked hairs has been used, suggesting its usefulness for monitoring disease activity [6,11].

In our first case, the histologic findings of a Hailey-Hailey like pattern are characterized by the presence of near full-thickness acantholysis of keratinocytes and acantholytic dyskeratotic cells. However, the

diagnosis of familial benign chronic pemphigus disease was rejected owing to the absence of a family history, the non-involvement of flexural areas, and immunofluorescence findings. The presence of a Hailey-Hailey like pattern of acantholysis on the scalp with direct immunofluorescence pattern of pemphigus vulgaris has only been previously described in 11 patients [12].

Treatment of LPV is based on topical corticosteroids, systemic corticosteroids, and other immunosuppressive therapies. For refractory lesions, intralesional administration of rituximab or triamcinolone acetonide is described [13]. Cases with good response to topical corticosteroid monotherapy have been reported, which we consider as the first-choice option due to its excellent safety profile [14]. However, in cases like ours where adequate disease control is not achieved, systemic corticosteroids for brief periods may be necessary, relying on topical and intralesional corticosteroids for response maintenance. Prognosis of LPV is favourable although, potential secondary extension and the recurrent course of the disease warrant long-term reviews [4].

Conclusion

Although scalp lesions may occur during the course of pemphigus vulgaris, their presence as an isolated manifestation is rare. Bullous diseases are frequently not taken into account in the differential diagnosis of scalp lesions and experienced personnel are necessary to reach a correct diagnosis.

It should also be noted that, in cases of LPV, good results can be obtained with oral corticosteroid treatment for a short period of time and intralesional infiltrations for maintenance, thus avoiding side effects associated with prolonged immunosuppressive treatments.

Potential conflicts of interest

The authors declare no conflicts of interest.

References

1. Esmaili N, Chams-Davatchi C, Valikhani M, et al. Pemphigus vulgaris in Iran: a clinical study of 140 cases. *Int J Dermatol.* 2007;46:1166–70. [PMID: 17988336].
2. Melchionda V, Harman KE. Pemphigus vulgaris and pemphigus foliaceus: an overview of the clinical presentation, investigations and management. *Clin Exp Dermatol.* 2019;44:740–6. [PMID: 31378971].
3. Salmanpour R, Shahkar H, Namazi MR, Rahman-Shenas MR. Epidemiology of pemphigus in south-western Iran: a 10-year retrospective study (1991-2000). *Int J Dermatol.* 2006;45:103–5. [PMID: 16445496].
4. Zaraa I, El Euch D, Kort R, et al. Localized pemphigus: a report of three cases. *Int J Dermatol.* 2010;49:715–6. [PMID: 20618482].
5. Arya S R, Valand A G, Krishna K. A clinico-pathological study of 70 cases of pemphigus. *Indian J Dermatol Venereol and Leprol.* 1999;65:168–171. [PMID: 20921646].
6. Marta Sar-Pomian, Lidia Rudnicka, Malgorzata Olszewska. The Significance of Scalp Involvement in Pemphigus: A Literature Review. *Biomed Res Int.* 2018;2018:6154397. [PMID: 29770335].
7. Saini P, Chakraborty A, Singh A, et al. Pemphigus Vulgaris Localized to a Surgical Scar. *Skinmed.* 2020;18:252–3. [PMID: 33050992].
8. Darlenski R, Kazandjieva J, Tsankov N. Contact pemphigus: does it exist?. *Eur J Dermatol.* 2021;31:702-704. [PMID: 33337331].
9. Tavakolpour S. Pemphigus trigger factors: special focus on pemphigus vulgaris and pemphigus foliaceus. *Arch Dermatol Res.* 2018;310:95–106. [PMID: 29110080].
10. Sar-Pomian M, Konop M, Gala K, Rudnicka L, Olszewska M. Scalp involvement in pemphigus: a prognostic marker. *Postepy Dermatol Alergol.* 2018;35:293–8. [PMID: 30008648].
11. Daneshpazhooh M, Naraghi Z S, Ramezani A, et al. Direct immunofluorescence of plucked hair for evaluation of immunologic remission in pemphigus vulgaris. *J Am Acad Dermatol.* 2011;65:e173–e177. [PMID: 33223735].
12. Gottesman SP, Abedi SM, Rosen JR, Gottlieb GJ. Hailey-Hailey-Like Pattern of Acantholysis on the Scalp Should Raise the Possibility of Incipient Pemphigus Vulgaris. *Am J Dermatopathol.* 2019;41:286–8. [PMID: 30640761].
13. Iraj F, Danesh F, Faghihi G, et al. Comparison between the efficacy of intralesional rituximab versus intralesional triamcinolone in the treatment refractory Pemphigus Vulgaris lesions: A randomized clinical trial. *Int Immunopharmacol.* 2019;73:94–7. [PMID: 31082727].
14. Vega-Diez D, Lario AR, Zubiaur AG, S. Pemphigus Vulgaris Localized to the Scalp with Complete Response to Topical Steroids. *Int J Trichology.* 2021;13:36–38. [PMID: 34934300].