

UC Davis

Dermatology Online Journal

Title

Sarcoidosis

Permalink

<https://escholarship.org/uc/item/5d3306f8>

Journal

Dermatology Online Journal, 21(12)

Authors

Martires, Kathryn
Shvartsbeyn, Marianna
Brinster, Nooshin
et al.

Publication Date

2015

DOI

10.5070/D32112029526

Copyright Information

Copyright 2015 by the author(s). This work is made available under the terms of a Creative Commons Attribution-NonCommercial-NoDerivatives License, available at <https://creativecommons.org/licenses/by-nc-nd/4.0/>

Peer reviewed

Case presentation

Sarcoidosis

Kathryn Martires MD, Marianna Shvartsbeyn MD, Nooshin Brinster MD, Sarika Ramachandran MD, and Andrew G Franks Jr MD

Dermatology Online Journal 21 (12): 1

New York University School of Medicine

Special Guest Editor: Nicholas A Soter MD

Abstract

We present a 28-year-old man with a one-year history of cutaneous lesions in old scars and tattoos with concomitant subcutaneous nodules and myopathy. A skin biopsy specimen showed cutaneous sarcoidosis. We discuss the multiple aspects of this case, which represent unique presentations of this systemic disease as well as review isomorphic and isotopic responses.

Case synopsis

History: A 28-year-old man presented with a one-year history of itchy papules on his face, arms, and chest. The lesions began in old scars from remote trauma as well as in one amateur tattoo on his right arm. He also noted one at the site of a prior cold sore of his lip. He noted that the lesions were not present in any of his professionally-applied tattoos. He also noted multiple, slightly-tender, subcutaneous nodules of his arms and legs. At this time, he began experiencing cough, joint pain, diffuse lymph-node enlargement, and generalized symmetric muscle weakness. He received a course of oral glucocorticoids, which seemed to improve his symptoms appreciably. His family history included systemic lupus erythematosus in his sister.

Physical examination: Multiple, scattered, 3-to-6-mm, red-brown, firm papules were present on the eyelids, lips, ears, right shoulder in an old scar, and right forearm in the distribution of a tattoo. The tattoos of the left forearm and neck were free of any lesions. There also were multiple, firm, 1-to-4-cm firm, rubbery, subcutaneous nodules of the upper arms, chest, thighs, and groin. Enlargement of the Meibomian glands was noted on the upper eyelids.

Laboratory: A complete blood count and metabolic panel were normal. The angiotensin-converting enzyme level was elevated at 98U/L. Anti-nucleolar antibody was 1:320, with a predominantly nucleolar pattern. The creatinine kinase level was elevated at 1719 U/L, and aldolase level was elevated at 18.7U/L. The erythrocyte sedimentation rate was elevated at 69 mm/h, and C-reactive protein level was 10.1mg/L. A rapid plasma reagin test was negative. Anti-Jo-1, anti-PM-Scl/ENA, anti-Ro anti-La, anti-Scl70, anti-Smith, and anti-dsDNA antibodies were negative. A chest radiograph demonstrated diffuse bilateral lymphadenopathy.

Histopathology: In the superficial dermis, there are relatively well-circumscribed aggregates of epithelioid and multinucleated histiocytes. Some aggregates are surrounded in part by an infiltrate of lymphocytes and plasma cells. Opaque foreign material is noted in foci. A periodic acid-Schiff with diastase stain for fungi and an acid-fast bacillus stain fail to show microorganisms.

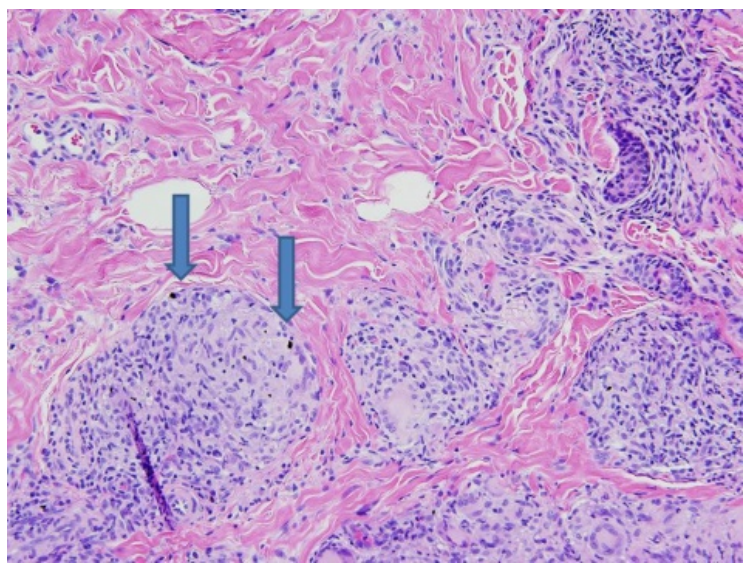
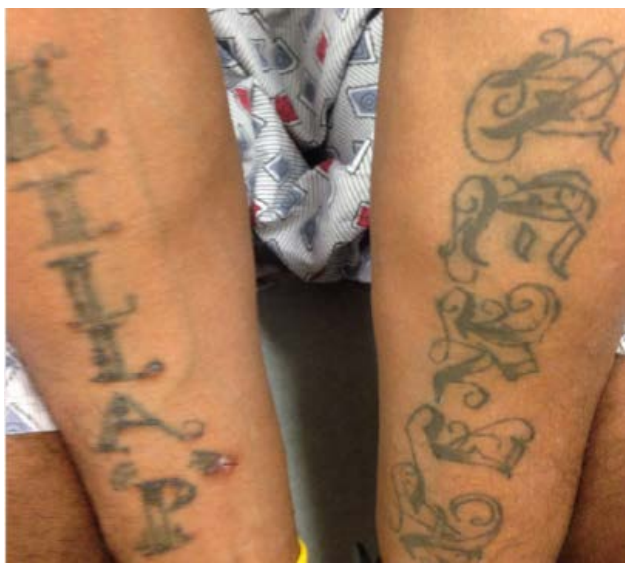

Figure 1. Tattoo related inflammatory papules Figure 2. Opaque foreign material noted by arrows

Discussion

Diagnosis: Sarcoidosis

Comment: Sarcoidosis is a multisystem disease that is characterized by non-caseating granulomas on histopathologic examination [1]. Cutaneous findings occur in a large portion of cases and often may represent the first sign of disease [2]. Exposure to one or more extrinsic antigens in a genetically susceptible individual may lead to activation of inflammatory pathways that promote the formation of non-caseating granulomas [1]. Although the etiologic agent is unknown, it is thought that the antigens may be infectious or environmental [3].

Development of sarcoidosis in scars or tattoos is an uncommon type of cutaneous disease. Cutaneous sarcoidosis may occur in scar tissue, at traumatized sites, and around imbedded foreign material, such as tattoos and silica [4]. In our case, sarcoidosis occurred at the site of amateur, but not professional, tattoos. It also occurred at sites of remote traumatic scars. Sarcoidosis also has been reported at sites of minor injury, which include acne or needle sticks [5]. The appearance of disease in previously inactive scars is thought to herald signs of increased disease activity. Studies suggest that systemic disease, which includes pulmonary disease, lymphadenopathy, and uveitis, is more common when cutaneous sarcoidosis is found within scars [6, 7].

Generally, there are several differences between amateur and professional tattoos. Amateur tattoos may have lower concentrations of pigment, utilize lower-grade material, and be applied at various depths of penetration. Professionally-applied tattoos, in contrast, may contain more pigment at greater depths and utilize multiple types of pigment [8]. There is no literature regarding the appearance of sarcoidosis in amateur versus professional tattoos. We hypothesize, however, that the amateur tattoo in this case may have induced increased trauma to the skin, which may have triggered more of an antigenic response than do the professional ones. It may be challenging to distinguish sarcoidosis from foreign body reaction on histopathologic examination [1]. However, based on the clinical picture and appearance on histopathologic examination, a diagnosis of sarcoidosis was favored in this case.

The distribution of skin lesions is a diagnostic clue to many dermatologic conditions. The Koebner isomorphic response describes the appearance of skin lesions at sites of injury that are morphologically similar to the existing skin disease. It is most frequently associated with psoriasis and lichen planus [9]. Isotopic responses describe the occurrence of a new, unrelated disease in the same location as a previously healed disease. Most commonly, herpes zoster and simplex have been reported as the initial skin insults [10]. In our case, sarcoidosis also appeared at the site of a prior cold sore of the lip. Mucosal sarcoidosis is otherwise uncommon [1].

The muscular symptoms were thought to represent a very rare form of systemic disease, sarcoid myopathy. Patients with this manifestation generally have chronic, progressive, generalized muscle weakness with elevated plasma creatinine kinase levels [11]. Our patient's creatinine kinase levels were elevated and decreased with treatment.

The initial appearance of multiple, simultaneous, subcutaneous nodules of the arms, thighs, and chest raises the question about the subcutaneous form of sarcoidosis, which is also known as Darier-Roussy sarcoidosis. It presents with deep, 0.5-to-2-cm, firm,

mobile, painless-to-slightly-tender nodules on the upper and lower extremities. They may be distinguished from erythema nodosum by the absence of tenderness and inflammation [12]. There is an association between subcutaneous sarcoidosis and systemic disease [13]. The patient initially presented with shortness of breath and cough; he was found to have bilateral lymphadenopathy on a chest radiograph. The patient's nodules, as well as much of his cutaneous and systemic disease, resolved after a month-long course of systemic glucocorticoids. He was later started on methotrexate.

References

1. Haimovic A, *et al.* Sarcoidosis: a comprehensive review and update for the dermatologist: part I. Cutaneous disease. *J Am Acad Dermatol* 2012;66:699 English
2. JC, *et al.* Sarcoidosis. *J Am Acad Dermatol* 2001;44:725
3. Barnard J, *et al.* Job and industry classifications associated with sarcoidosis in A Case-Control Etiologic Study of Sarcoidosis (ACCESS). *J Occup Environ Med* 2005;47:226
4. Post J, Hull P. Tattoo reactions as a sign of sarcoidosis. *Can Med Assoc J J Assoc Medicale Can* 2012;184:432
5. Antonovich DD, Callen JP. Development of sarcoidosis in cosmetic tattoos. *Arch Dermatol* 2005;141:869
6. Su Ö, *et al.* Disseminated scar sarcoidosis may predict pulmonary involvement in sarcoidosis. *Acta Dermatovenerol Alp Pannonica Adriat* 2013;22:71
7. Landers MC, *et al.* Cutaneous and pulmonary sarcoidosis in association with tattoos. *Cutis* 2005;75:44
8. Sweeney SM. Tattoos: a review of tattoo practices and potential treatment options for removal. *Curr Opin Pediatr* 2006;18:391
9. Rubin AI, Stiller MJ. A listing of skin conditions exhibiting the koebner and pseudo-koebner phenomena with eliciting stimuli. *J Cutan Med Surg* 2002;6:29
10. Wolf R, *et al.* Isotopic response. *Int J Dermatol* 1995;34:341
11. Maeshima S, *et al.* Clinicopathological features of sarcoidosis manifesting as generalized chronic myopathy *J Neurol* 2015;e-pub ahead of print
12. Lodha S, *et al.* Sarcoidosis of the skin: a review for the pulmonologist. *Chest* 2009;136:583
13. Ahmed I, Harshad SR. Subcutaneous sarcoidosis: is it a specific subset of cutaneous sarcoidosis frequently associated with systemic disease? *J Am Acad Dermatol* 2006;54:55