

UC Davis

Dermatology Online Journal

Title

Scented lotions may cause scarring and premature fading of tattoos

Permalink

<https://escholarship.org/uc/item/5d2676s2>

Journal

Dermatology Online Journal, 26(10)

Authors

Pona, Adrian
Gonzalez, Cristian D
Walkosz, Barbara J
et al.

Publication Date

2020

DOI

10.5070/D32610050465

Copyright Information

Copyright 2020 by the author(s). This work is made available under the terms of a Creative Commons Attribution-NonCommercial-NoDerivatives License, available at <https://creativecommons.org/licenses/by-nc-nd/4.0/>

Peer reviewed

Scented lotions may cause scarring and premature fading of tattoos

Adrian Pona^{1,2} MD, Cristian D Gonzalez¹ MD, Barbara J Walkosz³ PhD, Robert P Dellavalle^{1,4} MD PhD MSPH

Affiliations: ¹Department of Dermatology, University of Colorado School of Medicine, Aurora, Colorado, USA, ²Department of Internal Medicine, Vidant Medical Center/East Carolina University, Greenville, North Carolina, USA, ³Klein Buendel, Inc., Golden, Colorado, USA, ⁴US Department of Veterans Affairs Rocky Mountain Regional VA Medical Center Dermatology Service, Aurora, Colorado, USA

Corresponding Author: Adrian Pona MD, Department of Dermatology, University of Colorado, Anschutz Cancer Pavilion Building, 3rd Floor, 1665 Aurora Court, Aurora, CO 80045, Tel: 720-848-0500, Fax: 720-848-0529, Email: pona1318@hotmail.com

Abstract

Although tattoo artists provide tattoo aftercare instructions to their clients, recommendations are often not cost-effective or supported by evidence. A 22-year-old man developed a pruritic red rash over his healing tattoo one week after receiving the tattoo. Although multiple queries were negative, the patient did note use of a scented lotion before the eruption. We determined that allergic contact dermatitis from the scented lotion caused scarring and premature fading of the new tattoo. Tattoo artists should recommend avoidance of scented lotions and instruct clients to care for their new tattoo like a wound in their aftercare instructions.

Keywords: allergic contact dermatitis, tattoos, ink, pigment, allergic reaction, allergy, hypersensitivity, case report, skin of color, carbon black 7

Introduction

Tattoo artists provide skin aftercare instructions to their clients following a tattoo procedure. Tattoo aftercare instructions are often limited to basic wound healing instructions, sun safety protection, and avoidance of submerging the tattoo in water (including pools, hot tubs, and lakes). However, there are no standardized tattoo aftercare instructions since insufficient evidence supports the determination of efficacious and cost-effective care. The purpose of this case presentation is to provide evidence that scented lotions could potentially harm

healing tattoos and should be mentioned in aftercare instructions [1].

Case Synopsis

A 22-year-old healthy man presented to clinic with onset of a new rash on his tattoo. One week after receiving a new tattoo on his right forearm (**Figure 1**), he developed an extremely pruritic rash on his healing tattooed skin. The patient went to his primary care physician for evaluation on day two of the reaction.

He reported no history of skin conditions or similar skin reactions. He also reported taking no medications nor did he have any pertinent travel history, family history, allergies, occupational exposures, sun exposure lasting greater than 10 minutes, or exposure to water, new soaps, or detergents. Concomitant symptoms included mild pain during day 1 and extreme pruritus several days thereafter. He did not experience any blisters, pus, tenderness to palpation, fever, chills, or night sweats.

When queried about a possible culprit that may have caused the rash, he acknowledged applying a strawberry and mint scented lotion (Olay Quench Cooling White Strawberry and Mint Body Lotion) to the tattooed skin. On day 1 after application of the scented lotion, the healing tattooed skin became erythematous and pruritic minutes after applying the scented lotion. On day 2, the tattooed skin became swollen and developed light pink plaques with multiple 1-2mm erosions, scabbing, and silver



Figure 1. The patient's right dorsal forearm represents a picture of the tattoo the moment the procedure was completed and before the scented lotion was applied. This provides a baseline reference of the tattoo color saturation.

scales (**Figure 2**). Given the history and timing of the reaction, his primary care physician did not refer the patient to a dermatologist for patch testing nor did he feel that a skin biopsy was warranted. The primary care physician recommended symptomatic treatment with ibuprofen for the swelling, application of an unscented lotion to control the pruritus, and avoidance of offending agents such as scented lotions. After day 2, the reaction subsided over days and the tattooed skin completely healed in three weeks. However, his tattoo continued to fade 6 months after the reaction (**Figure 3**).

The patient had three tattoos when the reaction took place. He had two uncomplicated healed tattoos (ventral left wrist and forearm) that were done in July and August 2018, whereas the inflamed tattooed skin on the left dorsal forearm was done in October 2018. All his tattoos were completed by the same

tattoo artist using the same ink (Dynamic ink). The black ink was composed of carbon black 7 (CAS# 1333-86-41, acrylic resin [TSRN00195201005-5102P], and isopropyl alcohol [CAS# 67-63-0]). Although the patient applied the scented lotion to all tattoos, only the fresh healing tattoo reacted. Furthermore, he had previously used the same scented lotion on his nontattooed skin several times but did not experience a skin reaction. He later received two additional tattoos (dorsal hand and ventral third finger) in March and April 2019 from the same tattoo artist using the same ink. Both tattoos healed without any complications.

Case Discussion

It is possible that allergic contact dermatitis to scented lotions could negatively impact the quality of a tattoo. In this case, without a patch test, the exact allergen precipitating allergic contact dermatitis cannot be narrowed down since the scented lotion

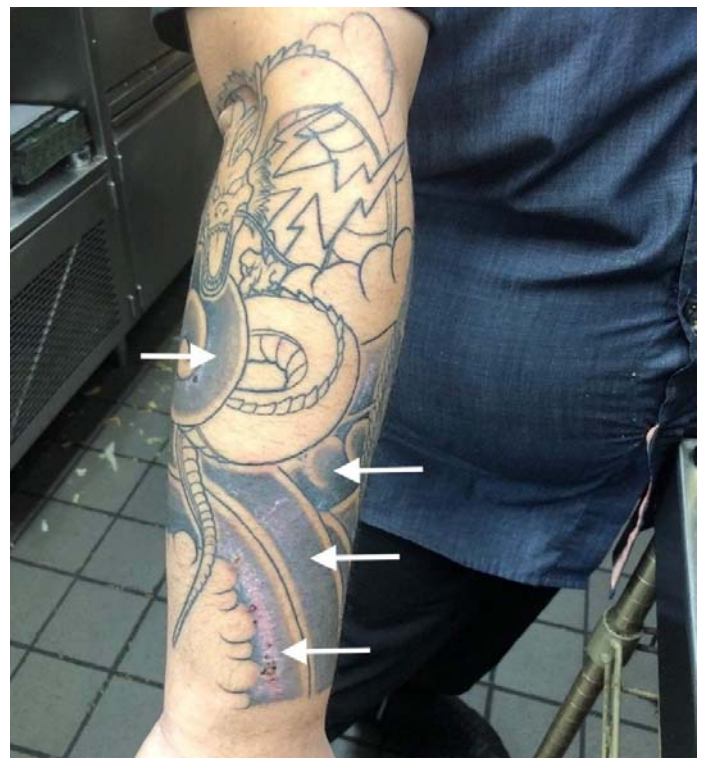


Figure 2. The patient's right dorsal forearm represents a picture of the patient's tattoo suffering from allergic contact dermatitis taken three days after the reaction. Compared to Figure 1, the color saturation has faded significantly and light pink plaques surround the edges of the new tattoo. The white arrows represent the maximally involved areas.



Figure 3. The patient's dorsal forearm represents the tattoo 6 months after the allergic contact dermatitis. Compared to Figures 1 and 2, there is significant color fading, change in texture, and scaring. The white arrows further represent the maximally involved areas.

had numerous potential allergens (**Table 1**). Although the scented lotion was applied to all tattoos, only the healing tattoo developed an allergic reaction. Damage to the skin barrier from the tattoo procedure may explain why the topical scented lotion caused an allergic contact dermatitis on the fresh healing tattoo and not on the old healed tattoos [2]. In our patient the initial rapidity of erythematous reaction within minutes suggested an irritant contact reaction, the development observed

over the next two days was much more suggestive of allergic contact dermatitis. Therefore, new tattoos could be managed like a wound and tattoo artists should appropriately mention how to manage a wound in their aftercare instructions. Furthermore, the healing tattoo suffering from allergic contact dermatitis was less likely caused by the tattoo ink and more likely caused by the scented lotion because the patient subsequently received similar tattoos with the same ink without reaction. In addition, it has been found that colored ink more likely precipitates an allergic contact dermatitis than black ink. In a study exploring the most common tattoo pigments proven or suspected of causing allergic contact dermatitis, 19 subjects were reported to suffer from an allergic contact dermatitis secondary to a colorful pigment and none of the subjects suffered from an allergic contact dermatitis secondary to a black pigment [3]. Tattoo artists should include avoidance of scented vehicles in their tattoo aftercare instructions to prevent contact dermatitis which may cause delayed wound healing, scar tissue formation, and premature tattoo fading.

Allergic contact dermatitis may be an underrepresented adverse effect after a tattoo procedure. In a study exploring common tattoo adverse effects, 80.5% of tattoo artists experience at least one client with an allergic reaction during their tattoo career [4]. Furthermore, another case series reported 43% of tattoo-related complications were likely related to allergic contact dermatitis [5]. However, a study of 448 tattoo artists reported 8% of tattoo artists experienced a client with an allergic reaction to the tattoo ink color [6]. Although the majority of the literature reports an allergic contact dermatitis to the tattoo ink, allergic contact dermatitis may also be secondary to a scented

Table 1: Ingredients in the Scented Lotion Serving as Potential Allergens*

Isopropyl Isostearate	Aluminum Starch Octenylsuccinate	Cetearyl Glucoside
Caprylic/Capric Triglyceride	Behenyl Alcohol	Cetearyl Alcohol
Dimethicone	Benzyl Alcohol	Disodium EDTA
Fragrance	Methylparaben	Stearic Acid
Stearyl Alcohol	Ethylparaben	Palmitic Acid
Cetyl Alcohol	Dimethiconol	Sodium Hydroxide
Sodium Acrylates Copolymer	Propylparaben	Yellow 10
Polyethylene	PEG-100 Stearate	Red 33

*The above-mentioned potential allergens are listed as displayed on the lotion bottle.

vehicle [7]. Furthermore, cases that report an allergic reaction to an ink may be secondary to the scented vehicle applied and not the ink itself. Increased awareness and implementation of scented vehicle avoidance in the tattoo aftercare instructions could improve preventable tattoo complications. Although allergic contact dermatitis may be related to the tattoo ink, the allergic contact dermatitis may also be related to the vehicle applied by the patient. A good history from the patient exploring possible culprits precipitating allergic contact dermatitis could distinguish the primary cause of allergic contact dermatitis.

A study exploring the most common tattoo aftercare instructions reported that avoidance of tattoo site manipulation, applying an antibiotic-free ointment, keeping the tattoo site dry, and using sunscreen were the most common recommended aftercare instructions. However, avoidance of scented lotions or creams was not reported [8].

Lack of a diagnostic patch test and biopsy and inability to acquire the exact scented lotion that caused the allergic contact dermatitis are limitations to this case report. Although the aforementioned diagnostic tests could further validate the allergic contact dermatitis, a proposed diagnostic algorithm for cutaneous reactions after a tattoo procedure suggests deferring from patch testing and a biopsy if the reaction occurred within one month of the tattoo procedure [7]. Since our case reported a reaction within one month, the primary care physician deferred from performing a patch test and biopsy and initiated supportive therapy.

References

1. Liszewski W, Jagdeo J, Laumann AE. The Need for Greater Regulation, Guidelines, and a Consensus Statement for Tattoo Aftercare. *JAMA Dermatol.* 2016;152:141-2. [PMID: 26535490].
2. Alavi A, Sibbald RG, Ladizinski B, et al. Wound-Related Allergic/Irritant Contact Dermatitis. *Adv Skin Wound Care.* 2016;29:278-86. [PMID: 27171256].
3. Liszewski W, Warshaw EM. Pigments in American tattoo inks and their propensity to elicit allergic contact dermatitis. *J Am Acad Dermatol.* 2019. [PMID: 30731175].
4. Rosenbaum BE, Milam EC, Seo L, Leger MC. Skin Care in the Tattoo Parlor: A Survey of Tattoo Artists in New York City. *Dermatol.* 2016;232:484-9. [PMID: 27287431].
5. Gonzalez-Villanueva I, Silvestre Salvador JF. Diagnostic Tools to

Since tattoo aftercare instructions are poorly regulated, we hope to inform dermatologists, healthcare providers and tattoo artists by providing evidence that may develop future efficacious and cost-effective standardized tattoo aftercare instructions [1].

Conclusion

Avoidance of scented lotions and use of inert vehicles on a tattoo should be included in the tattoo aftercare instructions. New tattoos should be treated like a wound. Failure to avoid scented vehicles could precipitate an allergic or irritant contact dermatitis, which may lead to significant tattoo fading, delayed wound healing, and scar formation. Furthermore, although tattoo ink may cause allergic contact dermatitis, what the patient is applying on the tattoo may also be the key culprit precipitating allergic contact dermatitis. Therefore, a thorough history of the cutaneous eruption could delineate the true cause of allergic contact dermatitis.

Potential conflicts of interest

The authors declare no conflicts of interests.

Acknowledgements

Funding for this project was provided by the National Cancer Institute (Diversity Training Branch and NIH/NCI Center to Reduce Cancer Health Disparities): R01CA206569-03S1.

Use When We Suspect an Allergic Reaction to a Tattoo: A Proposal Based on Cases at Our Hospital. *Actas Dermosifiliogr.* 2018;109:162-72. [PMID: 29197467].

6. Kluger N. Self-reported tattoo reactions in a cohort of 448 French tattooists. *Int J Dermatol.* 2016;55:764-8. [PMID: 26499460].
7. Silvestre JF, Gonzalez-Villanueva I. Diagnostic Approach for Suspected Allergic Cutaneous Reaction to a Permanent Tattoo. *J Invest Allergol Clin Immunol.* 2019. [PMID: 30931919].
8. Sandsmark EK, Salazar M, Jones J, et al. Re: Cutaneous melanoma attributable to sunbed use: systematic review and meta-analysis. 2012. <https://www.bmj.com/content/345/bmj.e4757/rapid-responses>. Accessed on June 20, 2019.